

SUBGLOTTIC STENOSIS COMPLICATED BY ALLERGIC ESOPHAGITIS CASE REPORT

CHRISTOPHER J. HARTNICK, MD

BOSTON, MASSACHUSETTS

ROBIN T. COTTON, MD

CINCINNATI, OHIO

JAMES H. LIU, MD

CINCINNATI, OHIO

COLIN RUDOLPH, MD, PHD

CINCINNATI, OHIO

Allergic esophagitis is a known entity that had been described in patients with dysphagia. It has not been previously described in association with subglottic stenosis. We report the case of a 2-year-old girl with symptoms suggestive of allergic esophagitis who suffered from subglottic stenosis that recurred despite surgical measures. Her esophageal pH monitoring results were normal, and she did not respond to antireflux medications. She did respond dramatically to corticosteroid therapy with improvement of both her esophageal and laryngeal symptoms. Allergic esophagitis as a clinical entity is discussed.

KEY WORDS — allergic esophagitis, subglottic stenosis.

INTRODUCTION

In 1982, Winter et al¹ described the association of esophageal eosinophilia with abnormal acid clearance. Since that point, esophageal eosinophilia has been used as a marker for gastroesophageal reflux disease (GERD). Gastroesophageal reflux disease has been linked to a host of airway disorders, including subglottic stenosis (SGS). The effect of GERD on the development and management of laryngotracheal stenosis was first described by Bain et al² in 1983 and has subsequently been the subject of much debate and controversy. In 1985, Little et al³ performed an elegant experiment in which they examined the effect of gastric acid on injured laryngeal mucosa. In a canine model, they divided their experiment into two arms: a control arm and an experimental arm. Both groups of dogs underwent controlled endoscopic injury to the laryngeal mucosa; the subglottic mucosa of the dogs in the experimental arm was then painted with gastric acid. In the control animals, the mucosal injuries healed without the development of SGS. When the mucosal injury was painted with gastric acid, SGS developed. Koufman⁴ has reported clinical data that concur with these canine experiments; he found that 78% of patients with SGS have abnormal double-probe pH study findings suggestive of GERD.

There have been several reports of patients with esophageal eosinophilia and the GERD-associated symptoms of dysphagia, vomiting, heartburn, and globus sensation who failed to respond to traditional medications for GERD such as prokinetics and proton pump inhibitors but who responded well to cor-

ticosteroid therapy.^{5,6} This has given credence to the diagnosis of allergic esophagitis.^{7,8} Kelly et al⁹ demonstrated that in some cases food allergy produces eosinophilic esophagitis. Ten children with GERD-like symptoms failed to respond either to maximum medical therapy or to surgical Nissen fundoplication, but improved with dietary restrictions and a specific diet; symptoms returned when specific food groups were reintroduced.⁹

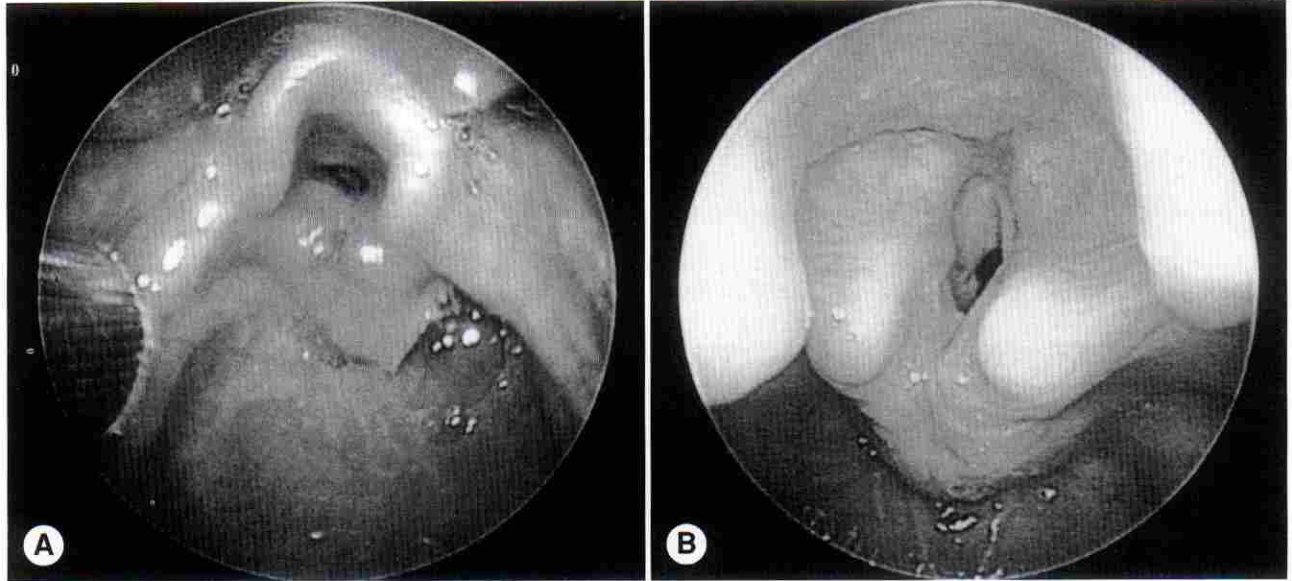
Allergic esophagitis has not been reported to be a causative factor in extra-esophageal disease; however, it is reasonable to assume that just as GERD plays a role in certain laryngeal disorders, so could allergic (or eosinophilic) esophagitis. A recent report documented the association of laryngeal clefts and eosinophilic gastroenteritis.¹⁰ The following case report describes a child with laryngeal inflammation initially thought to be consistent with GERD who did not respond to aggressive antireflux therapy, but rather, responded to therapy used to treat allergy.

CASE REPORT

A 2-year-old girl who had been born prematurely at 32 weeks required intubation for 3 weeks. Upon extubation, she had mild to moderate stridor that was exacerbated by upper respiratory tract infections. She also developed intolerance to many food products, suffering from choking and vomiting episodes. She received a diagnosis of SGS and underwent multiple laser procedures at an outside institution. Upon arrival at Children's Hospital Medical Center in Cincinnati, she underwent endoscopy that revealed a Myer-Cotton grade III SGS (see Figure, A). Her hy-

From the Departments of Pediatric Otolaryngology (Hartnick, Liu, Cotton) and Pediatric Gastroenterology (Rudolph), Children's Hospital Medical Center, Cincinnati, Ohio.

CORRESPONDENCE — Christopher J. Hartnick, MD, Dept of Otolaryngology, Massachusetts Eye and Ear Infirmary, 243 Charles St, Boston, MA 02114.



Endoscopic views of larynx of patient A) before and B) after treatment for allergic esophagitis.

popharyngeal and postcricoid regions showed inflammation that suggested GERD. Flexible esophagoscopy and biopsies of the esophagus were performed. A double-probe pH monitor was placed with the upper probe positioned in the base of the pyriform fossa and the lower probe at the level of the third thoracic vertebra. The patient then underwent a functional endoscopic evaluation of swallowing that revealed no signs of penetration or aspiration and revealed an essentially normal pharyngeal swallow. The pH probe monitoring was performed overnight for a total recording time of 15 hours and revealed no episodes of a pH of <4 in the upper esophagus, and a pH of <4 in the lower esophagus for only 1% of the recording time. The biopsy results were significant for the finding of eosinophilia (10 to 12 eosinophils per high-power field [HPF]).

Given the clinical appearance of the child's postcricoid region and hypopharynx, the decision was made to start her on an empiric course of Cisapride (0.3 mg/kg per day divided into 4 daily administrations) and Prilosec (1 mg/kg per day in 4 daily administrations) and then to proceed with surgical correction of her airway. The patient underwent a single-stage cricotracheal resection and was intubated for 6 days. After the operation, she was maintained on her anti-reflux medications; over the ensuing weeks, the SGS recurred and did not respond to serial dilations. Her postoperative course was complicated by difficulty with oral intake, as she could not tolerate many different food products without retching and vomiting spells. She underwent allergy testing, which revealed an essentially normal complete blood count other than an elevated IgE level of 38 IU/mL. (In our laboratory, the mean normative value for the serum IgE

level in a 2-year-old is 3 IU/mL, and >2 SD from the mean, or >29.5 IU/mL, represents an elevated laboratory value.) Skin testing showed evidence of allergy. Radioallergosorbent testing showed a positive allergic response to peanuts, milk, and walnuts.

The patient then underwent a single-stage laryngotracheal reconstruction with costal cartilage grafting. A pH probe was placed during the operation and again failed to demonstrate any significant GERD over the next 48 hours. The patient's postoperative course was stormy, as she quickly redeveloped tightness of breathing and intermittent stridor. She suffered an anaphylactic reaction to a peanut that required emergent intubation and medical therapy.

In light of the strong history of allergic responses, the patient was placed on 0.5 mg/kg Decadron given every other day for 1 month and then tapered off. Over this period, her symptoms markedly improved; her ability to eat food without event improved, as did her airway symptoms. Repeat endoscopy showed a significantly improved postcricoid region with minimal inflammation or edema (see Figure, B). Biopsy of the esophageal mucosa revealed an absence of eosinophilia. She persisted with a grade II SGS. Over the 6-week course of therapy, she had developed side effects to the steroid treatment, including significant weight gain with water retention. At the 6-week follow-up after steroid discontinuation, the side effects of the steroids had significantly diminished, but so had their effect. Again, she was experiencing tightness of breathing and retching and vomiting with feeding.

The patient has been placed on an aerosolized steroid regimen and a strict diet following the recommendations of Kelly et al.⁹ Her symptoms markedly

improved over a 2-week period. She currently is undergoing further allergy testing and dietary evaluation. The decision has been made to delay further surgery pending medical management of her allergic symptoms.

DISCUSSION

There are many anecdotal reports, as well as published cases, of children with signs and symptoms of GERD who fail to respond to either maximum medical therapy or surgical therapy.^{6,9} A subset of these patients have esophageal biopsies that document eosinophilia. There has been divergence in the literature as to how to interpret this finding. Winter et al¹ noted that eosinophilia was an early sign of GERD, and that the more prominent the eosinophilia, the more severe the GERD. Their patients, however, generally had fewer than 5 eosinophils per HPF. Other studies have used esophageal eosinophilia as a marker for GERD.¹¹⁻¹³

Recently, more severe eosinophilia has been recognized to be due to allergy and other nonreflux causes. Liacouras et al^{5,6} examined a cohort of children with esophageal eosinophilia and GERD symptoms who did not respond to medical therapy or Nissen fundoplication. They found that children with "allergic esophagitis" who responded to corticosteroid treatment had a greater eosinophilia than did children with esophageal eosinophilia and GERD who responded to traditional medical treatment.⁵ Other groups have described similar cohorts of patients⁸; Ruchelli et al⁷ used the number of eosinophils per HPF (ie, >7) to predict the success of antireflux therapy, and posited that alternative medical therapies aimed at allergic causes might well be effective.

The role of GERD in the genesis and outcome of upper airway disease processes has been well documented, but remains controversial. Laryngeal manifestations of GERD have been postulated since Cherry and Margulies¹⁴ described a possible relationship between GERD and the development of laryngeal contact ulcers. Since that time, GERD has been associated with a host of respiratory manifestations.^{15,16} There have been several anecdotal reports of the success of preoperative medical treatment of GERD with respect to the outcome of surgical repair of laryngotracheal stenosis.¹⁷⁻¹⁹ These reports contrast with the 1996 study by Zalzal et al,²⁰ which denies an association between GERD and the outcome of laryngo-

tracheal stenosis surgery.

Our case report portrays a child with acquired SGS and marked symptoms of GERD. The complicating factors were the failure of double-probe pH studies to measure acid reflux, as well as the inability of fairly aggressive medical antireflux therapy to control the symptoms. Surgical treatment of GERD was considered, but in the face of the negative pH probe tests, it was difficult to justify. After formal allergy testing and a review of esophageal biopsies that showed 10 to 12 eosinophils per HPF, a trial of corticosteroid therapy was implemented with marked improvement of symptoms. (We are using the definition of Ruchelli et al⁷ of >7 eosinophils per HPF as a marker for allergic esophagitis.) Repeat esophageal biopsies showed an absence of eosinophilia. Symptoms (both airway and gastrointestinal) returned upon withdrawal of the steroid regimen, and as the patient developed minor side effects after a 1-month course of steroids, a longer treatment regimen with this course of therapy seemed unreasonable. Aerosolized corticosteroid therapy presents an untested but potential alternate treatment and has been offered as an option to the parents of children with allergic esophagitis.²¹

Another treatment option, which has been suggested by the work of Kelly et al,⁹ is dietary therapy. Kelly et al proposed the hypothesis that symptoms of allergic esophagitis were a response to the ingestion of intact dietary proteins. When they tested this hypothesis by removing all intact dietary proteins from 10 children's diets for a period of time and giving them Neocate or Neocate-1 Plus supplement, the children's symptoms improved. This treatment option needs further evaluation, but holds promise.

CONCLUSIONS

There is a cohort of patients with signs and symptoms of allergic esophagitis who respond to corticosteroid and/or steroid therapy. We present the case of a child with acquired SGS and signs and symptoms of allergic esophagitis. This represents the first association between allergic esophagitis and a laryngeal disorder such as SGS. For children with extraesophageal disease suspected to be related to or aggravated by GERD, in which traditional medical and/or surgical therapy fails to relieve the symptoms, a diagnosis of allergic esophagitis should be considered.

REFERENCES

1. Winter HS, Madara JL, Stafford RJ, Grand RJ, Quinlan JE, Goldman H. Intraepithelial eosinophils: a new diagnostic criterion for reflux esophagitis. *Gastroenterology* 1982;83:818-23.
2. Bain WM, Harrington JW, Thomas LE, Schaefer SD. Head and neck manifestations of gastroesophageal reflux. *Laryngoscope* 1983;93:175-9.
3. Little FB, Koufman JA, Kohut RI, Marshall RB. Effect of gastric acid on the pathogenesis of subglottic stenosis. *Ann Otol Rhinol Laryngol* 1985;94:516-9.

4. Koufman JA. The otolaryngologic manifestations of gastroesophageal reflux disease (GERD): a clinical investigation of 225 patients using ambulatory 24-hour pH monitoring and an experimental investigation of the role of acid and pepsin in the development of laryngeal injury. *Laryngoscope* 1991;101 (suppl 53).
5. Liacouras CA, Wenner WJ, Brown K, Ruchelli E. Primary eosinophilic esophagitis in children: successful treatment with oral corticosteroids. *J Pediatr Gastroenterol Nutr* 1998;26:380-5.
6. Liacouras CA. Failed Nissen fundoplication in two patients who had persistent vomiting and eosinophilic esophagitis. *J Pediatr Surg* 1997;32:1504-6.
7. Ruchelli E, Wenner W, Voytek T, Brown K, Liacouras C. Severity of esophageal eosinophilia predicts response to conventional gastroesophageal reflux therapy. *Pediatr Dev Pathol* 1999;2:15-8.
8. Walsh SV, Antonioli DA, Goldman H, et al. Allergic esophagitis in children: a clinicopathological entity. *Am J Surg Pathol* 1999;23:390-6.
9. Kelly KJ, Lazenby AJ, Rowe PC, Yardley JH, Perman JA, Sampson HA. Eosinophilic esophagitis attributed to gastroesophageal reflux: improvement with an amino acid-based formula. *Gastroenterology* 1995;109:1503-12.
10. Goldstein NA, Putnam PE, Dohar JE. Laryngeal cleft and eosinophilic gastroenteritis: report of 2 cases. *Arch Otolaryngol Head Neck Surg* 2000;126:227-30.
11. Hyams JS, Ricci A Jr, Leichtner AM. Clinical and laboratory correlates of esophagitis in young children. *J Pediatr Gastroenterol Nutr* 1988;7:52-6.
12. Brown LF, Goldman H, Antonioli DA. Intraepithelial eosinophils in endoscopic biopsies of adults with reflux esophagitis. *Am J Surg Pathol* 1984;8:899-905.
13. Shub MD, Ulshen MH, Hargrove CB, Siegal GP, Groben PA, Askin FB. Esophagitis: a frequent consequence of gastroesophageal reflux in infancy. *J Pediatr* 1985;107:881-4.
14. Cherry J, Margulies SI. Contact ulcer of the larynx. *Laryngoscope* 1968;78:1937-40.
15. Andze GO, Luks FI, Bensoussan AL, Blanchard H. [Role of surgical treatment of gastro-esophageal reflux in children with severe asthma.] *Pediatric* 1991;46:451-4.
16. Bauman NM, Sandler AD, Smith RJH. Respiratory manifestations of gastroesophageal reflux disease in pediatric patients. *Ann Otol Rhinol Laryngol* 1996;105:23-32.
17. Jindal JR, Milbrath MM, Shaker R, Hogan WJ, Toohill RJ. Gastroesophageal reflux disease as a likely cause of "idiopathic" subglottic stenosis. *Ann Otol Rhinol Laryngol* 1994;103:186-91.
18. Halstead LA. Gastroesophageal reflux: a critical factor in pediatric subglottic stenosis. *Otolaryngol Head Neck Surg* 1999;120:683-8.
19. Gray S, Miller R, Myer CM III, Cotton RT. Adjunctive measures for successful laryngotracheal reconstruction. *Ann Otol Rhinol Laryngol* 1987;96:509-13.
20. Zalzal GH, Choi SS, Patel KM. The effect of gastroesophageal reflux on laryngotracheal reconstruction. *Arch Otolaryngol Head Neck Surg* 1996;122:297-300.
21. Faubion WA Jr, Perrault J, Burgart LJ, Zein NN, Clawson M, Freese DK. Treatment of eosinophilic esophagitis with inhaled corticosteroids. *J Pediatr Gastroenterol Nutr* 1998;27:90-3.