

Temporal Bone Image Library

Chapter: Surgical Pathology

Otopathology Laboratory



Fenestration, L-436

Title: Fenestration, L-436

Chapter: Surgical Pathology

Chapter Section: Surgery for Otosclerosis

TB Case Number: 1004

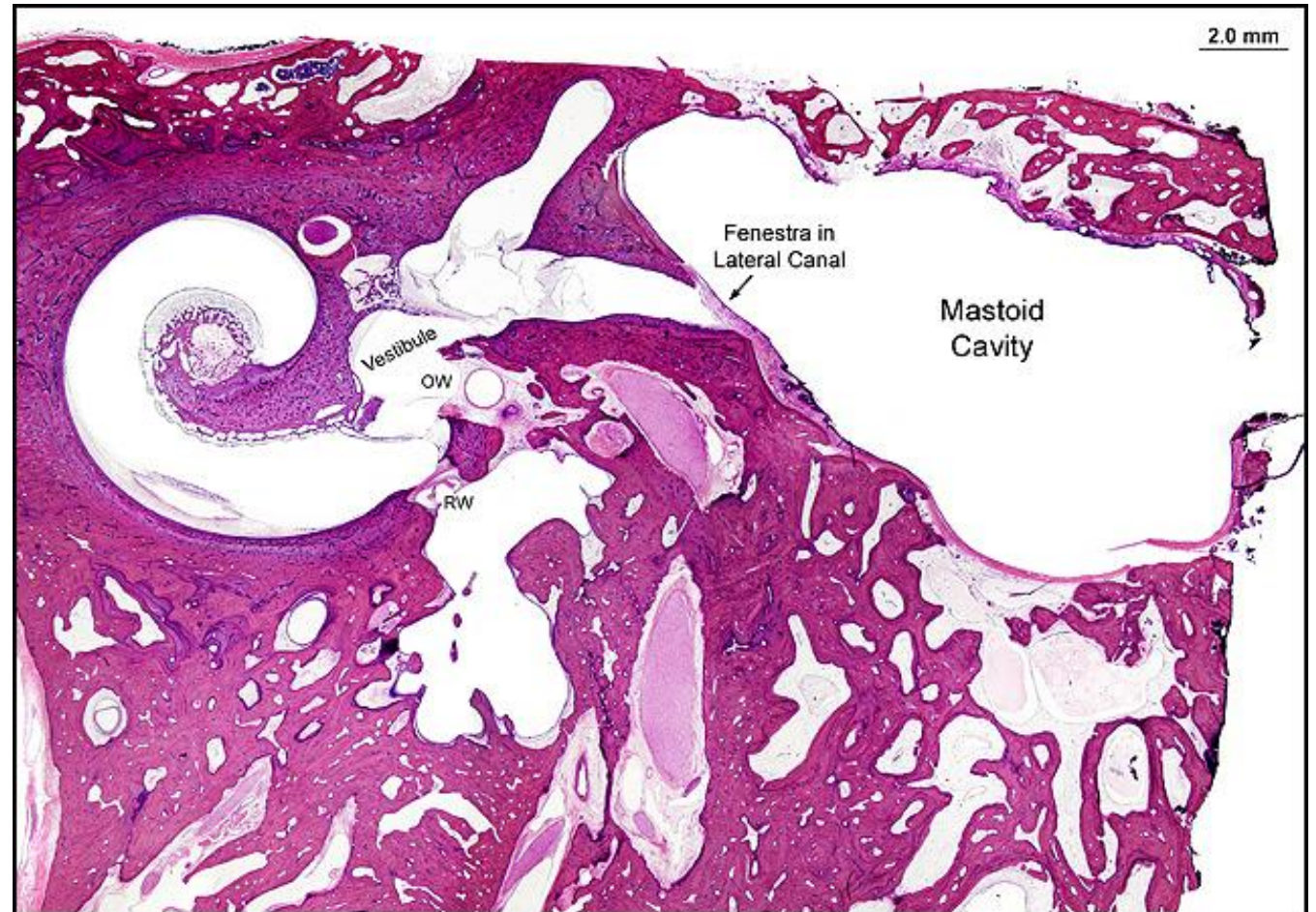
Comments: Fenestration and stapedectomy done. Large residual air-bone gap of 40 dB. Section shows all 3 windows

Gender: Male

Age (yrs.): 84

Otologic Diagnosis:

1. Otosclerosis with mixed hearing loss, bilateral
2. Fenestration surgery for otosclerosis followed by stapedectomy, bilateral
3. Otosclerosis, clinical, single focus near oval window, bilateral
4. Fenestration procedure



Fenestration and Stapedectomy, L-436

Title: Fenestration and Stapedectomy, L-436

Chapter: Surgical Pathology

Chapter Section: Surgery for Otosclerosis

TB Case Number: 1004

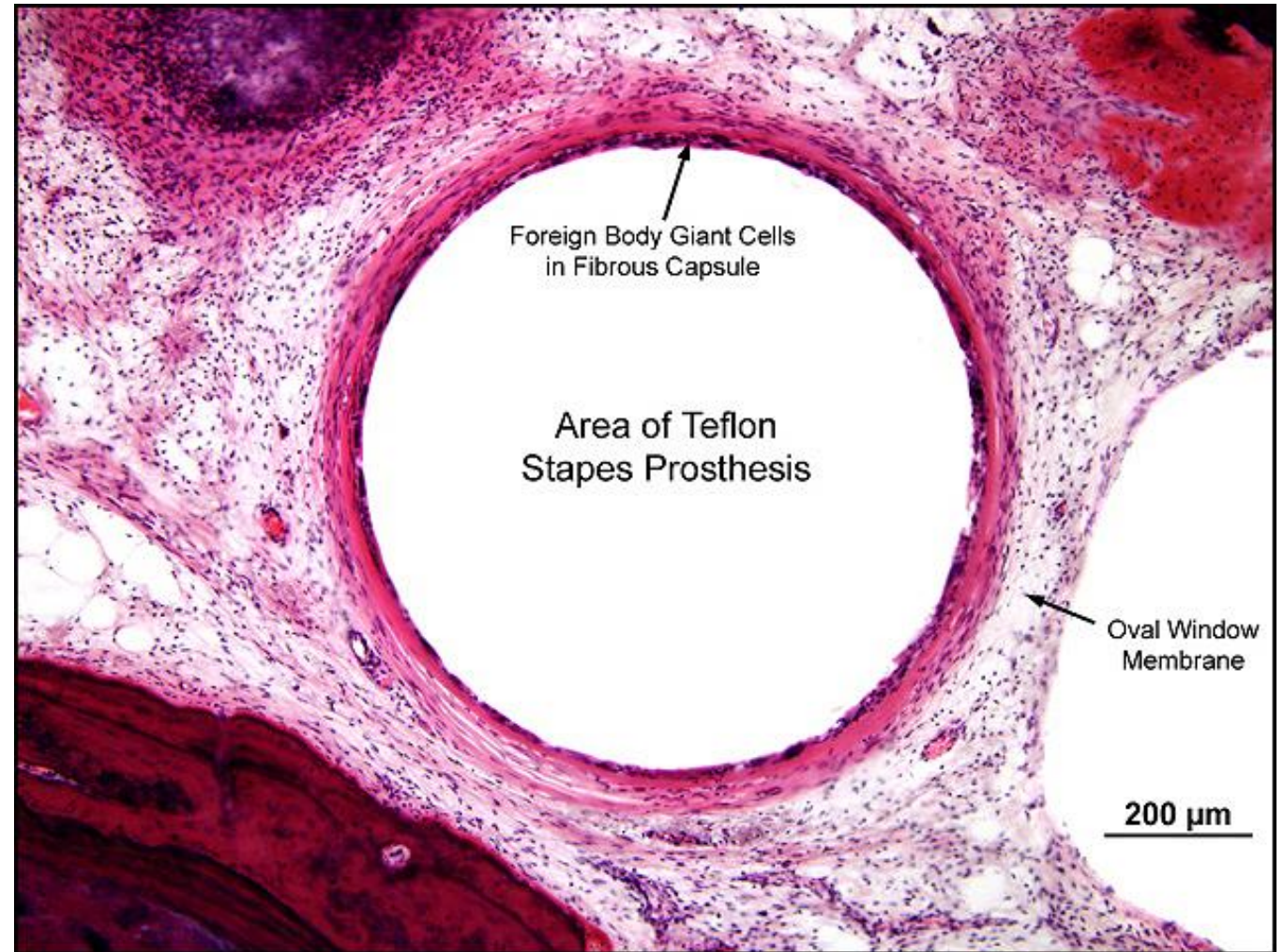
Comments: Total stapedectomy with teflon piston

Gender: Male

Age (yrs.): 84

Otologic Diagnosis:

1. Otosclerosis with mixed hearing loss, bilateral
2. Fenestration surgery for otosclerosis followed by stapedectomy, bilateral
3. Otosclerosis, clinical, single focus near oval window, bilateral
4. Fenestration procedure



Fenestration, R-61

Title: Fenestration, R-61

Chapter: Surgical Pathology

Chapter Section: Surgery for Otosclerosis

TB Case Number: 1004

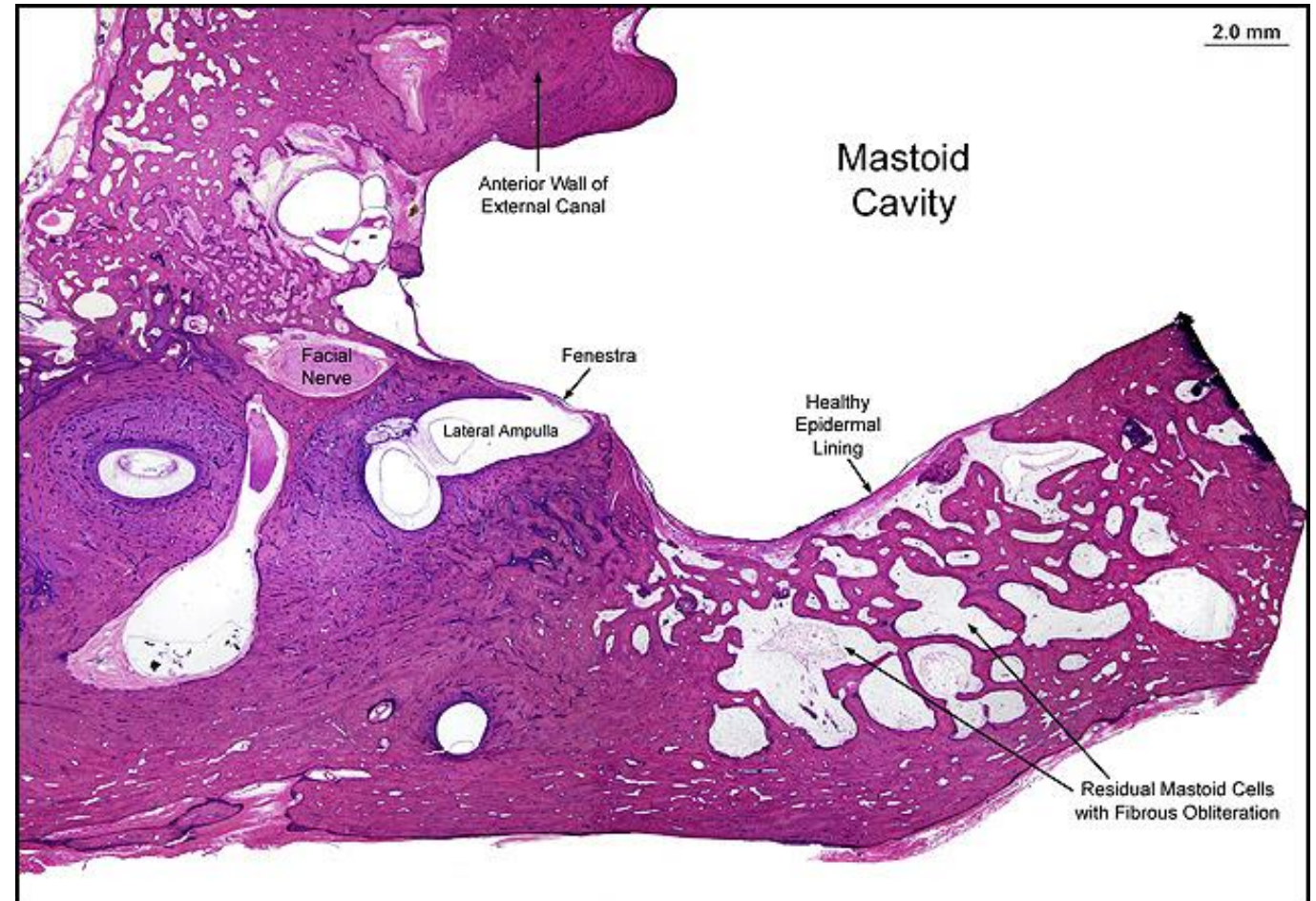
Comments: Fenestration done, fenestra nov-ovalis.

Gender: Male

Age (yrs.): 84

Otologic Diagnosis:

1. Otosclerosis with mixed hearing loss, bilateral
2. Fenestration surgery for otosclerosis followed by stapedectomy, bilateral
3. Otosclerosis, clinical, single focus near oval window, bilateral
4. Fenestration procedure



Fenestration, R-61

Title: Fenestration, R-61

Chapter: Surgical Pathology

Chapter Section: Surgery for Otosclerosis

TB Case Number: 1004

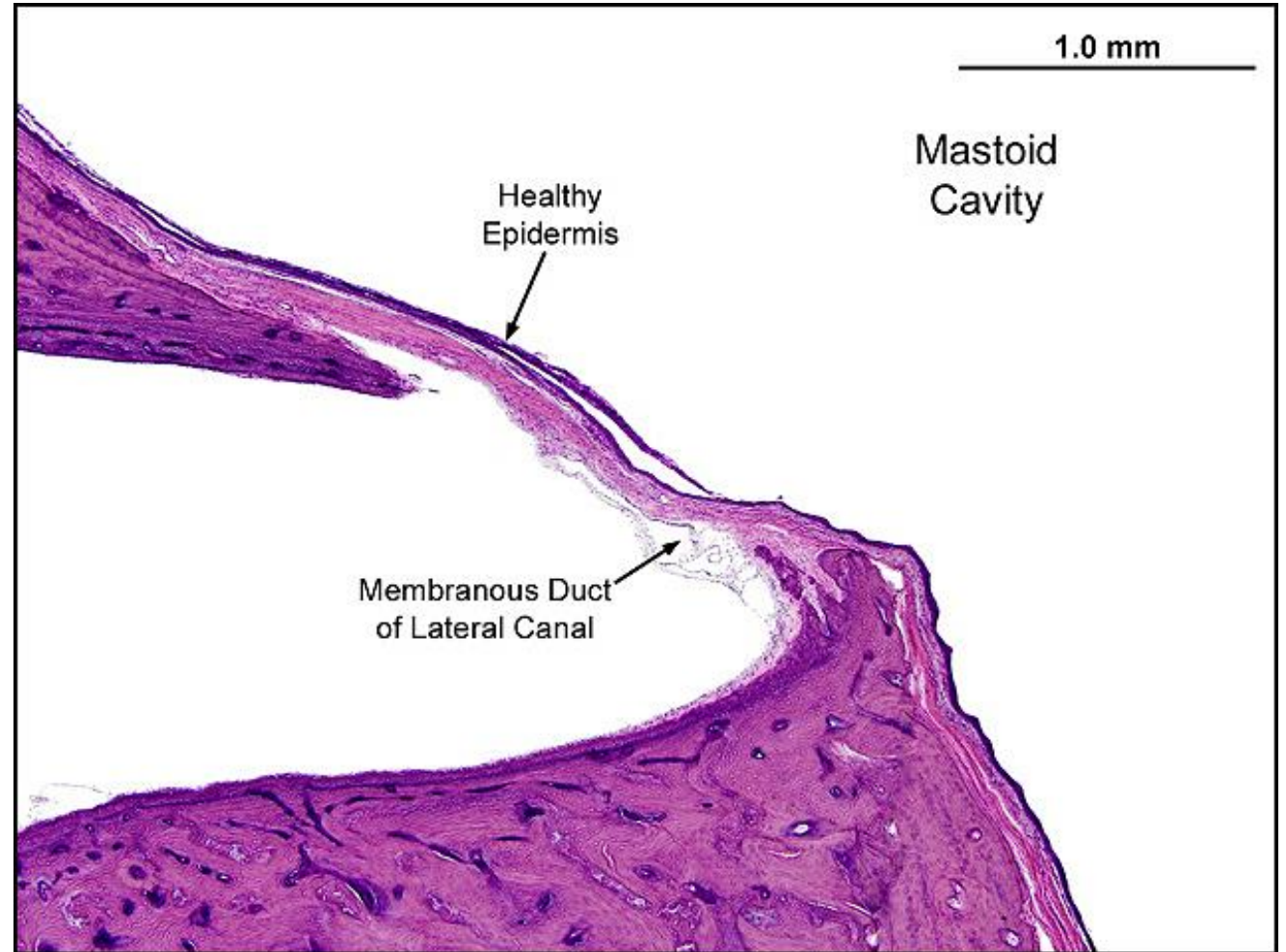
Comments: Fenestration done, fenestra nov-ovalis.

Gender: Male

Age (yrs.): 84

Otologic Diagnosis:

1. Otosclerosis with mixed hearing loss, bilateral
2. Fenestration surgery for otosclerosis followed by stapedectomy, bilateral
3. Otosclerosis, clinical, single focus near oval window, bilateral
4. Fenestration procedure



Normal Incus, L-189

Title: Normal Incus, L-189

Chapter: Surgical Pathology

Chapter Section: Surgery for Otosclerosis

TB Case Number: 404

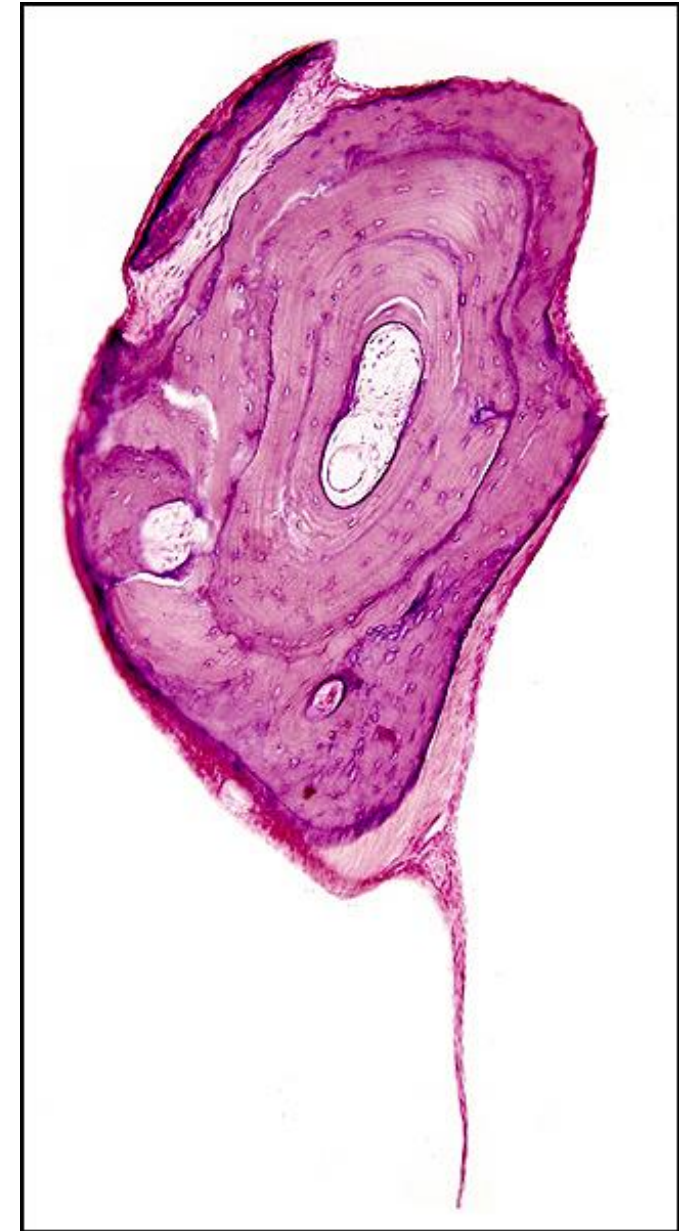Comments: incus necrosis control

Gender: Female

Age (yrs.): 56

Otologic Diagnosis:

1. Otosclerosis with stapes fixation, bilateral
2. Stapedectomy with adipose tissue implant to oval window, right
3. Iatrogenic infracture, fallopian canal, causing temporary postoperative facial palsy, right



Incus Necrosis, R-176

Title: Incus Necrosis, R-176

Chapter: Surgical Pathology

Chapter Section: Surgery for Otosclerosis

TB Case Number: 404

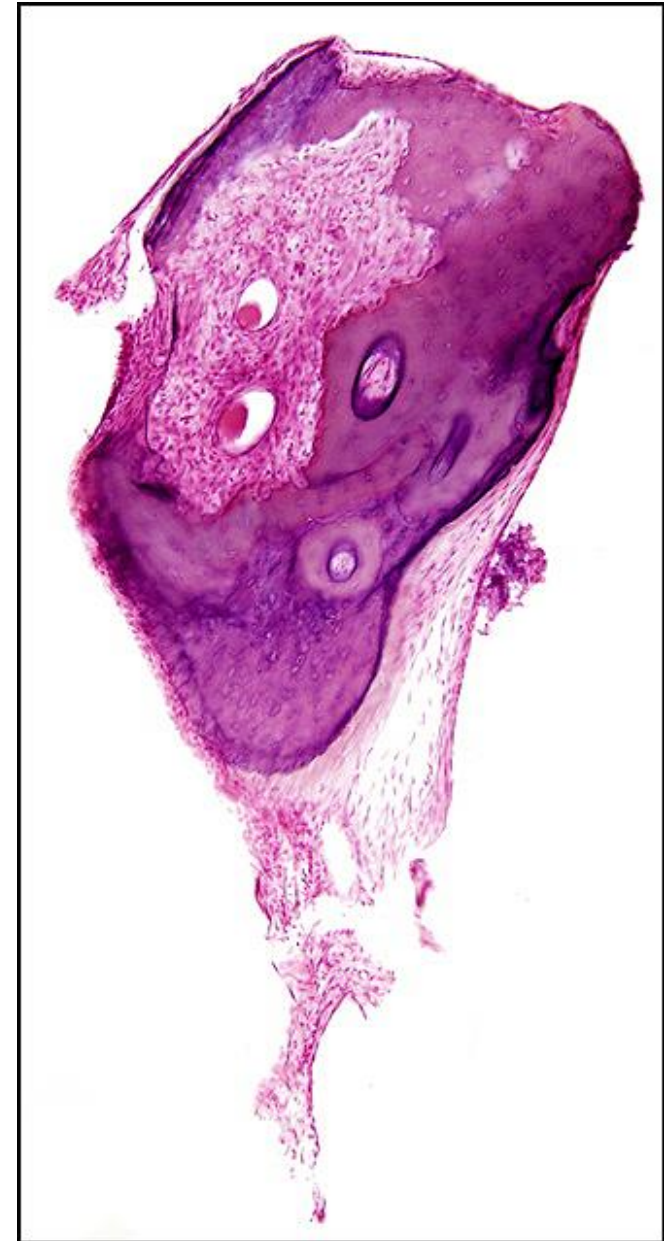
Comments: incus necrosis after stapedectomy

Gender: Female

Age (yrs.): 56

Otologic Diagnosis:

1. Otosclerosis with stapes fixation, bilateral
2. Stapedectomy with adipose tissue implant to oval window, right
3. Iatrogenic infracture, fallopian canal, causing temporary postoperative facial palsy, right



Incus Necrosis, L-189 and R-176

Title: Incus Necrosis, L-189 and R-176

Chapter: Surgical Pathology

Chapter Section: Surgery for Otosclerosis

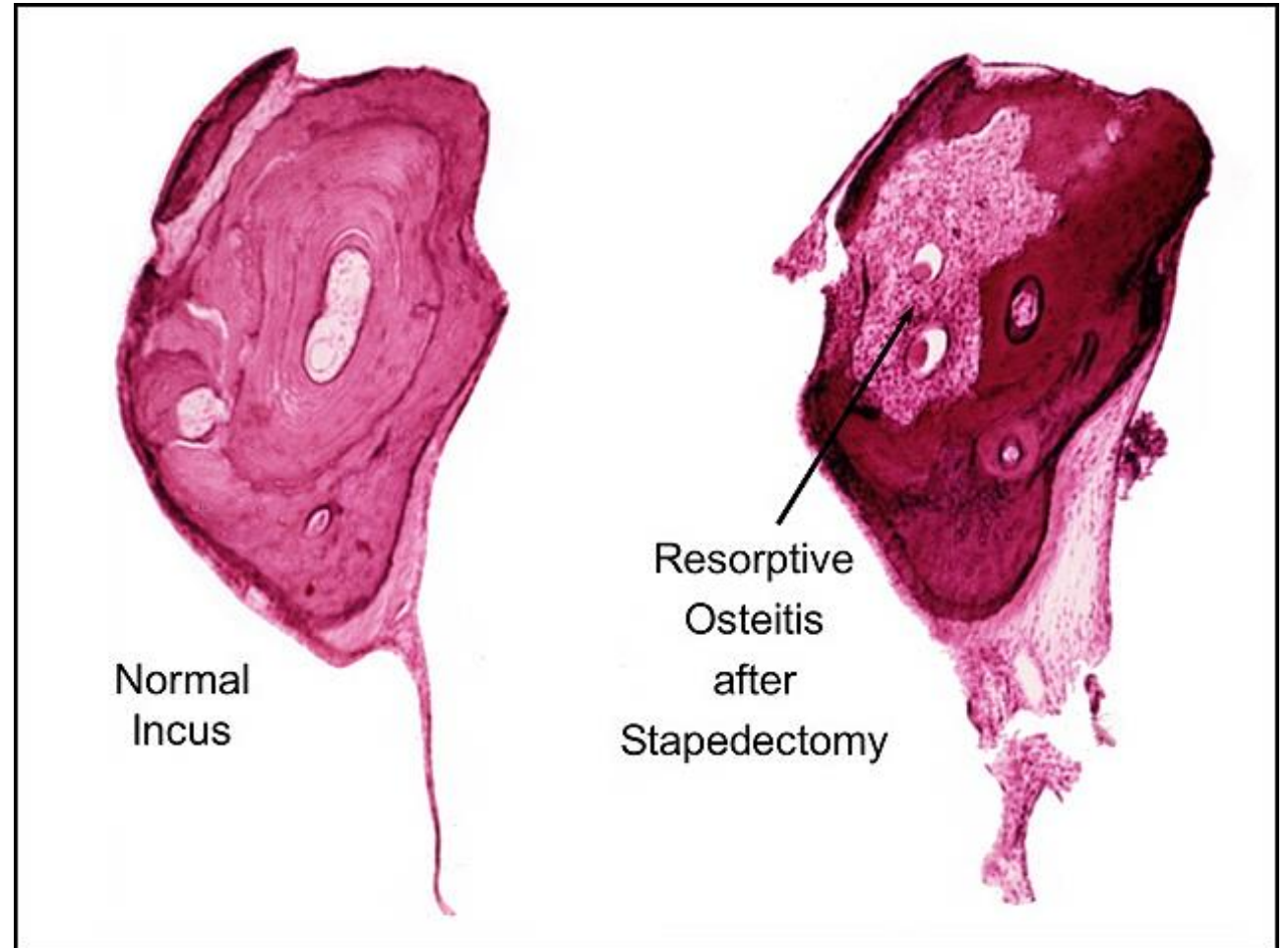
TB Case Number: 404

Gender: Female

Age (yrs.): 56

Otologic Diagnosis:

1. Otosclerosis with stapes fixation, bilateral
2. Stapedectomy with adipose tissue implant to oval window, right
3. Iatrogenic infracture, fallopian canal, causing temporary postoperative facial palsy, right



Stapedectomy, R-193.2

Title: Stapedectomy, R-193-2

Chapter: Surgical Pathology

Chapter Section: Surgery for Otosclerosis

TB Case Number: 404

Comments: Stapedectomy - Robinson stapes prosthesis

Gender: Female

Age (yrs.): 56

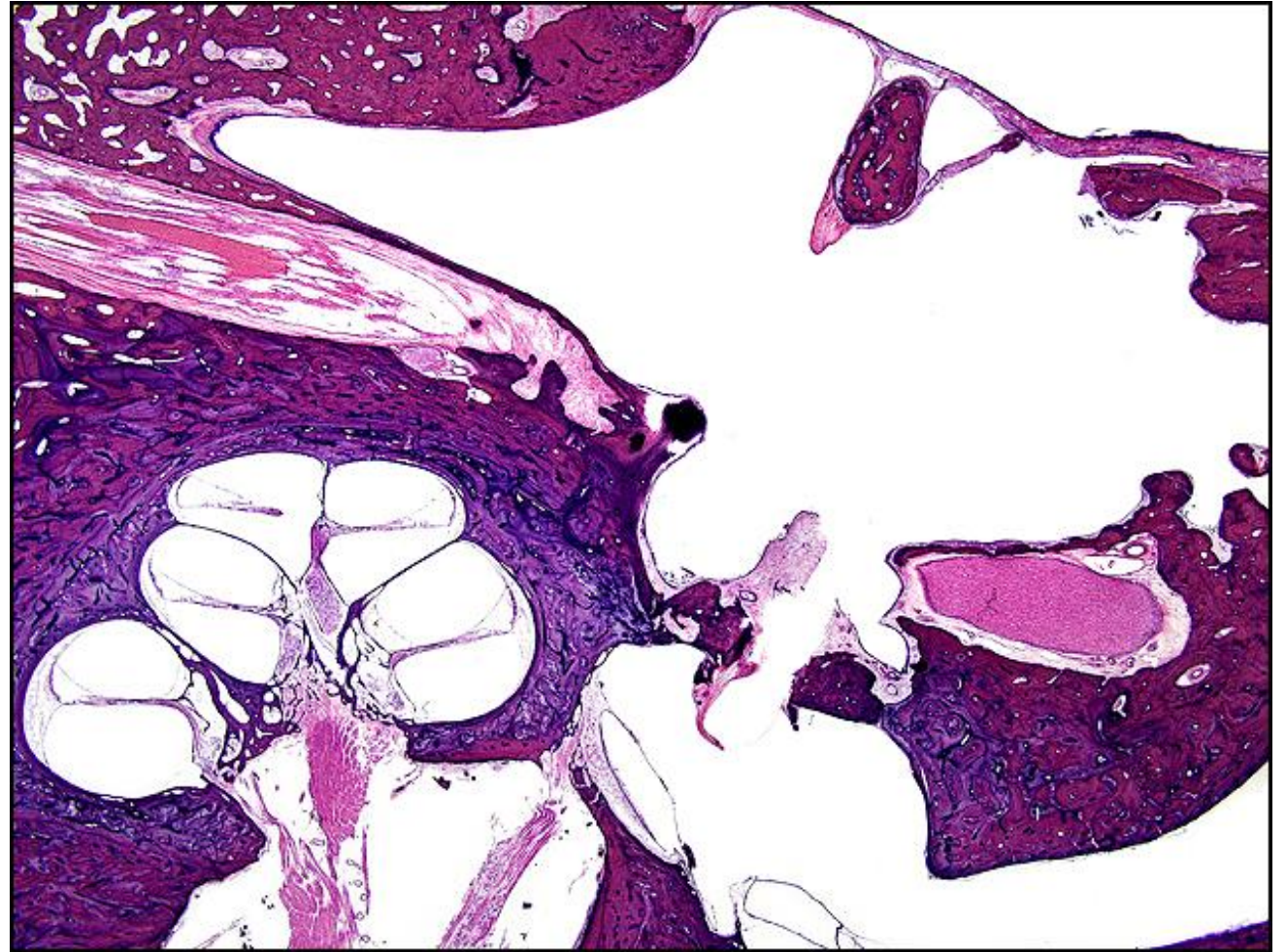
Otologic Diagnosis:

Clinical:

1. Otosclerosis, clinical, with stapes fixation, right
2. Stapedectomy, small fenestra, Robinson stainless steel prosthesis, right
3. Profound hearing loss, left

Histological:

Otosclerosis, clinical, involving stapes footplate, bilateral



Stapedectomy, R-193.1

Title: Stapedectomy, R-193.1

Chapter: Surgical Pathology

Chapter Section: Surgery for Otosclerosis

TB Case Number: 995

Comments: Stapedectomy, Robinson stapes prosthesis

Gender: Female

Age (yrs.): 80

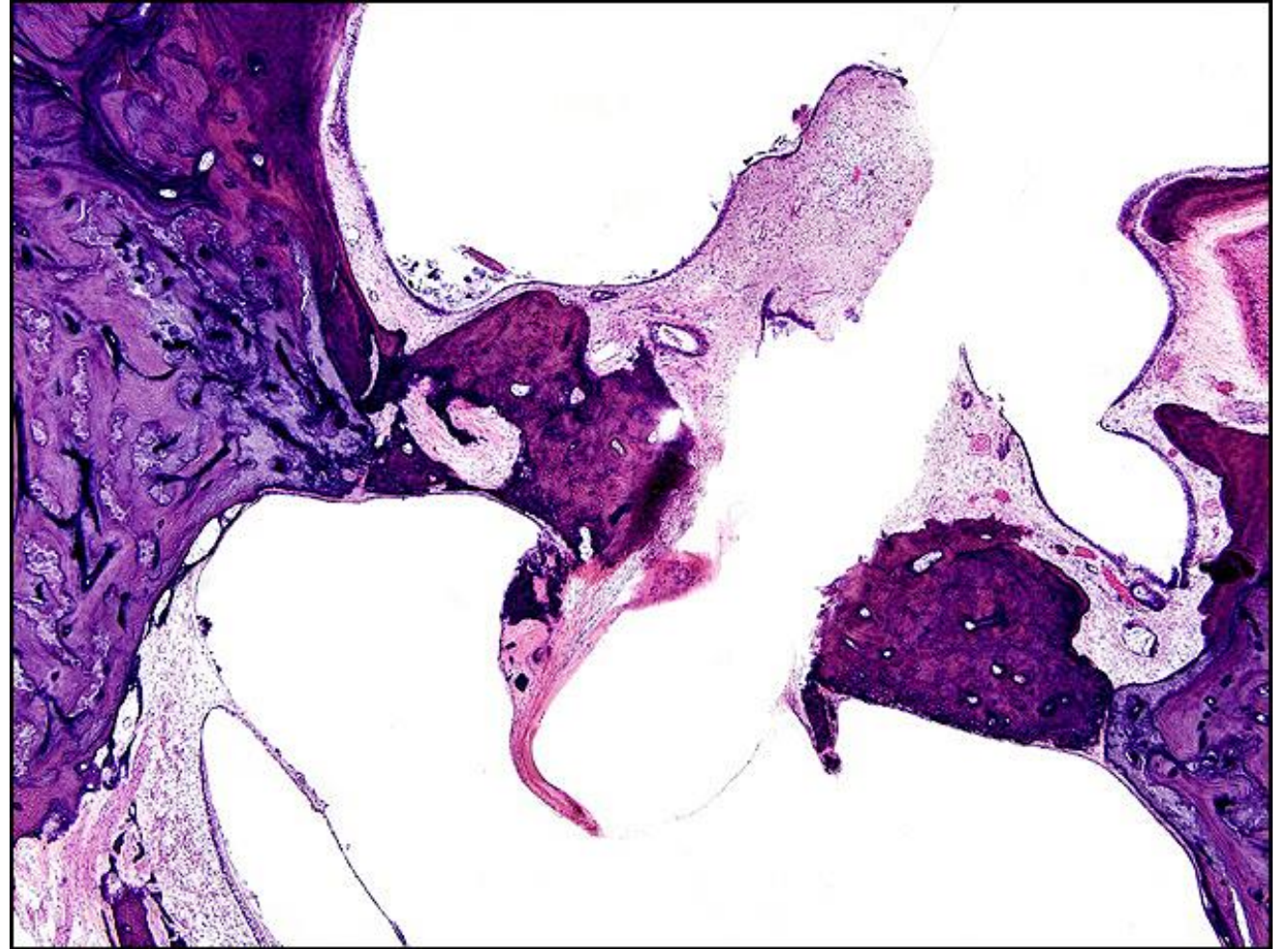
Otologic Diagnosis:

Clinical:

1. Otosclerosis, clinical, with stapes fixation, right
2. Stapedectomy, small fenestra, Robinson stainless steel prosthesis, right
3. Profound hearing loss, left

Histological:

Otosclerosis, clinical, involving stapes footplate, bilateral



Labyrinthitis Ossificans, L-261

Title: Labyrinthitis Ossificans, L-261

Chapter: Surgical Pathology

Chapter Section: Surgery for Otosclerosis

TB Case Number: 992

Comments: Stapedectomy Polyethylene tube prosthesis with labyrinthitis ossificans

Gender: Female

Age (yrs.): 95

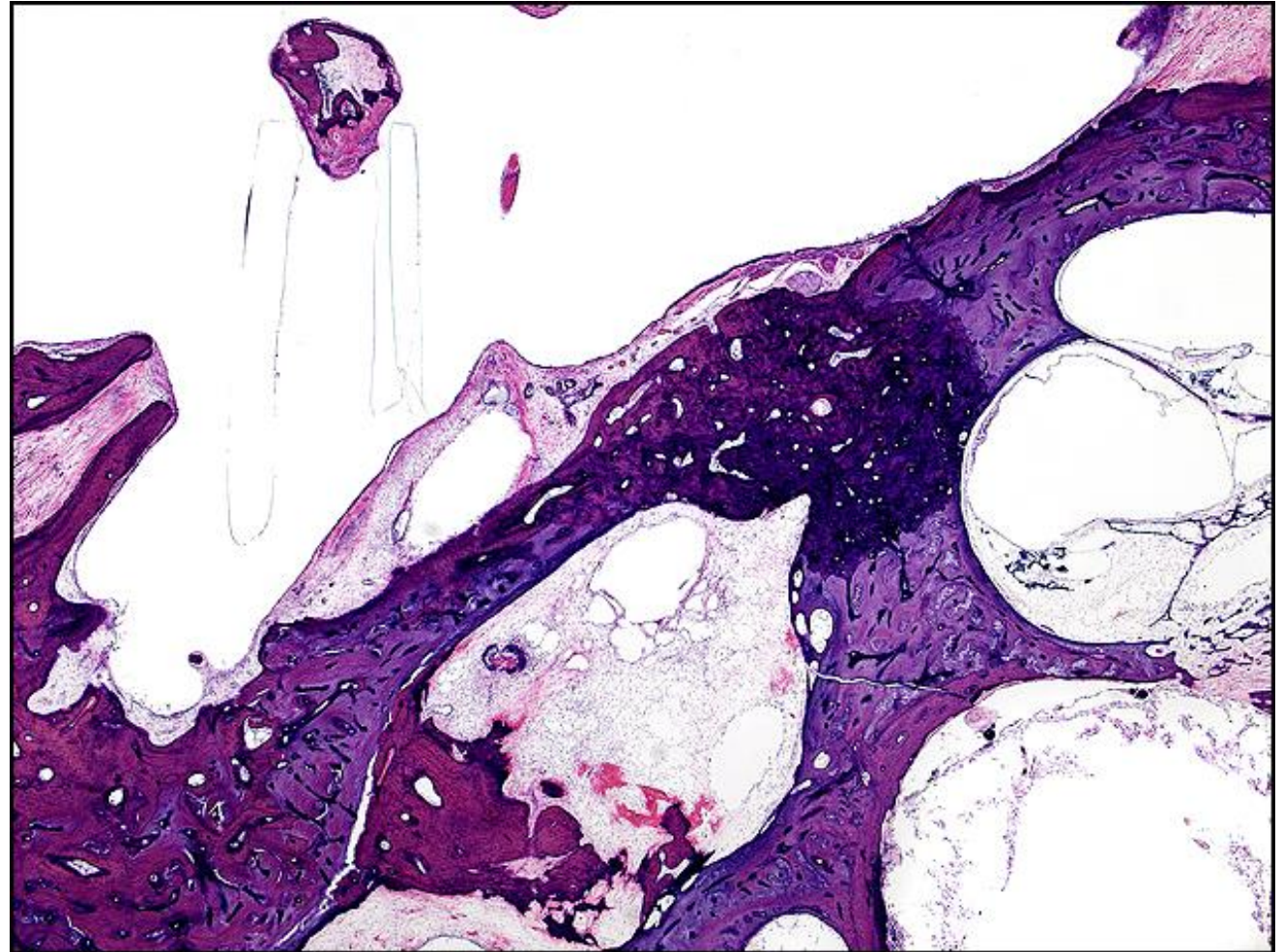
Otologic Diagnosis:

Clinical Diagnoses:

1. Otosclerosis, bilateral
2. Profound hearing loss, left, status post total stapedectomy with polyethylene strut
3. Mixed hearing loss, right, associated with otosclerosis

Histologic Diagnoses:

Otosclerosis, clinical, bilateral



Incus, R-151

Title: Incus, R-151

Chapter: Surgical Pathology

Chapter Section: Surgery for Otosclerosis

TB Case Number: 992

Comments: Resorption of incus without stapedectomy

Gender: Female

Age (yrs.): 95

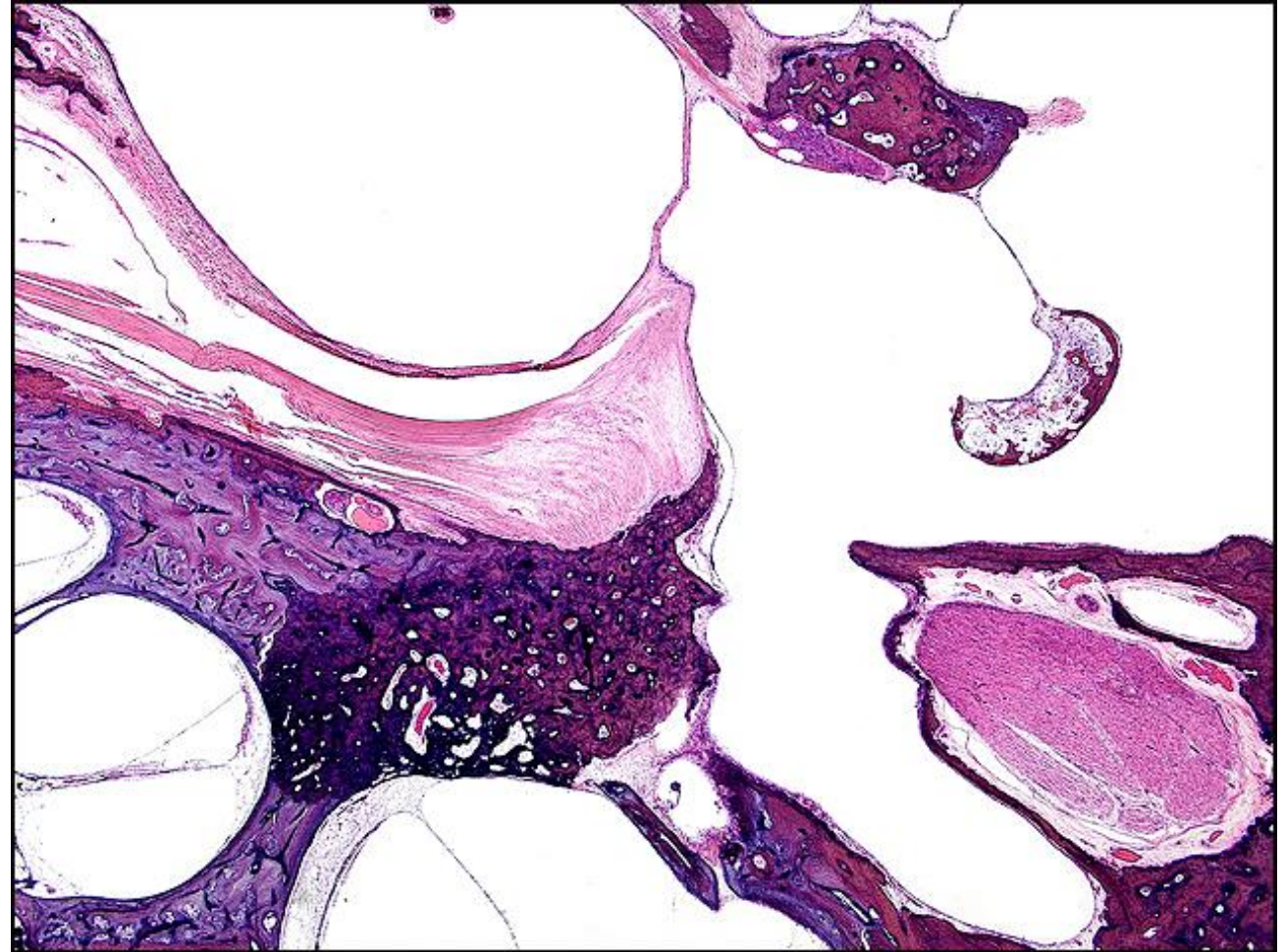
Otologic Diagnosis:

Clinical Diagnoses:

1. Otosclerosis, bilateral
2. Profound hearing loss, left, status post total stapedectomy with polyethylene strut
3. Mixed hearing loss, right, associated with otosclerosis

Histologic Diagnoses:

Otosclerosis, clinical, bilateral



Incus, R-151

Title: Incus, R-151

Chapter: Surgical Pathology

Chapter Section: Surgery for Otosclerosis

TB Case Number: 992

Comments: resorption of incus without stapedectomy

Gender: Female

Age (yrs.): 95

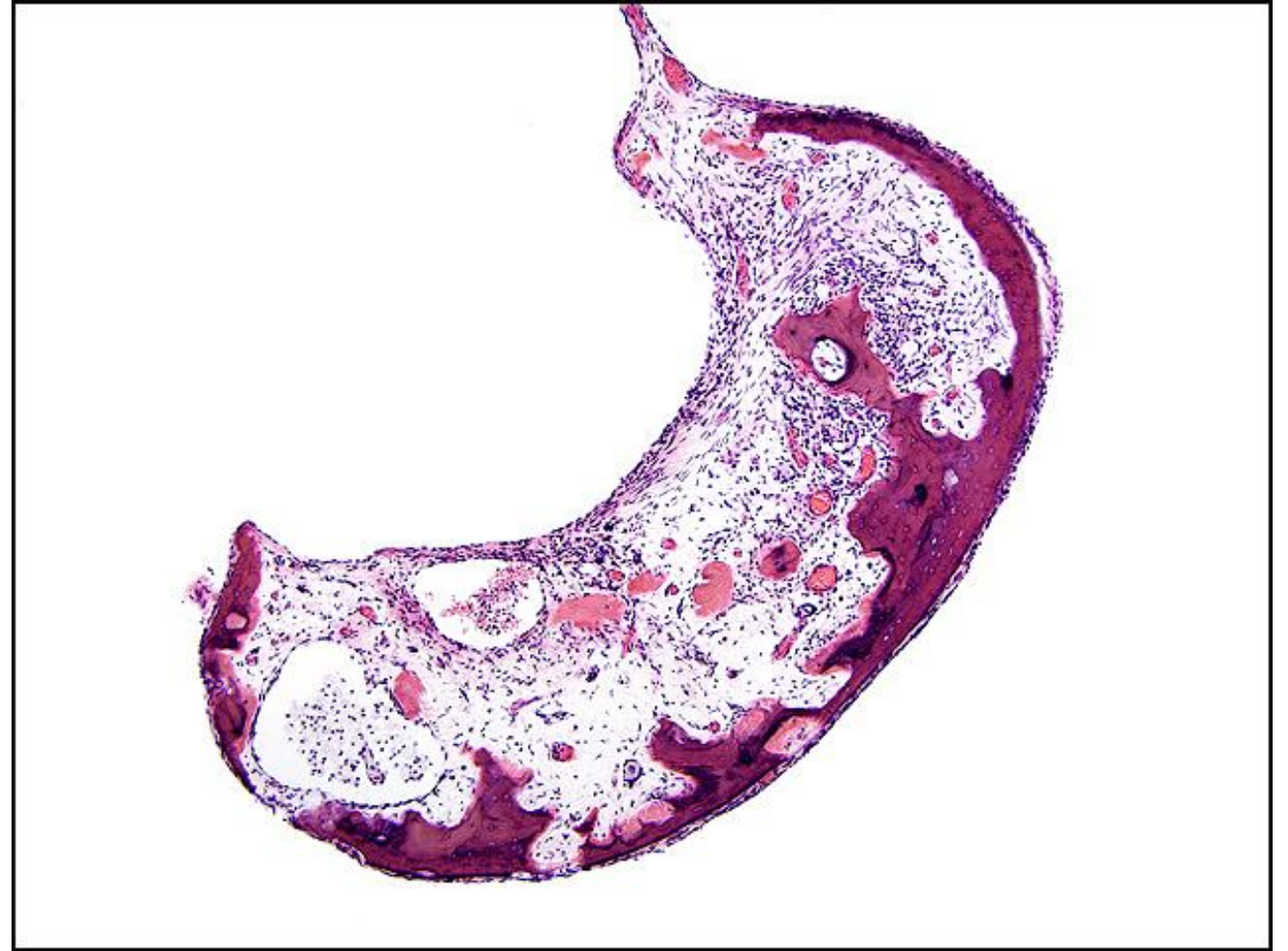
Otologic Diagnosis:

Clinical Diagnoses:

1. Otosclerosis, bilateral
2. Profound hearing loss, left, status post total stapedectomy with polyethylene strut
3. Mixed hearing loss, right, associated with otosclerosis

Histologic Diagnoses:

Otosclerosis, clinical, bilateral



Ossicles, L-236

Title: Ossicles, L-236

Chapter: Surgical Pathology

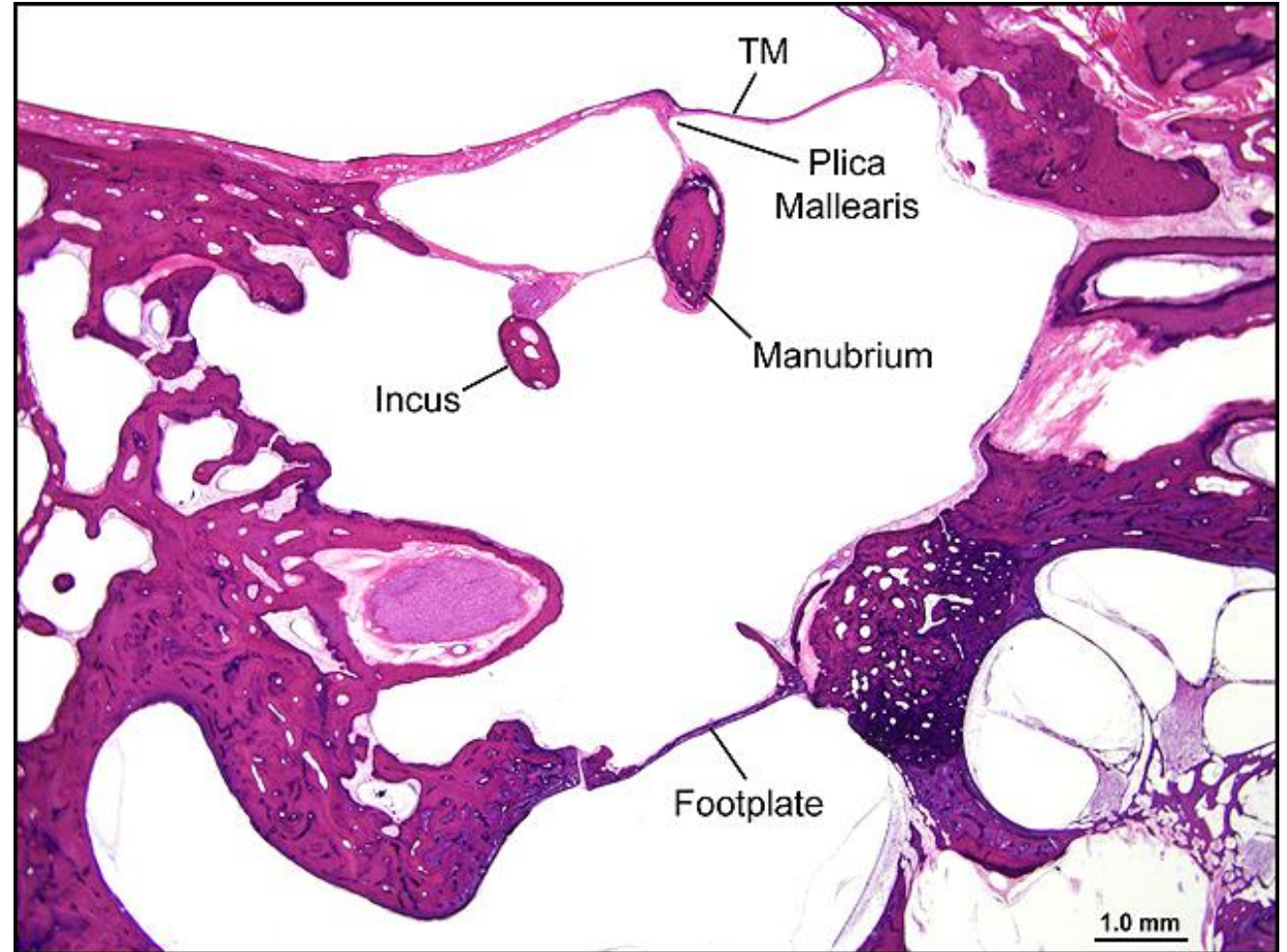
Chapter Section: Surgery for Otosclerosis

TB Case Number: 1012

Comments: 86 yr. old woman with otosclerosis. Anatomical relationships between manubrium, plica mallearis, incus and footplate are shown.

Gender: Female

Age (yrs.): 86



Stapedectomy, R-212.26

Title: Stapedectomy, R-212.26

Chapter: Surgical Pathology

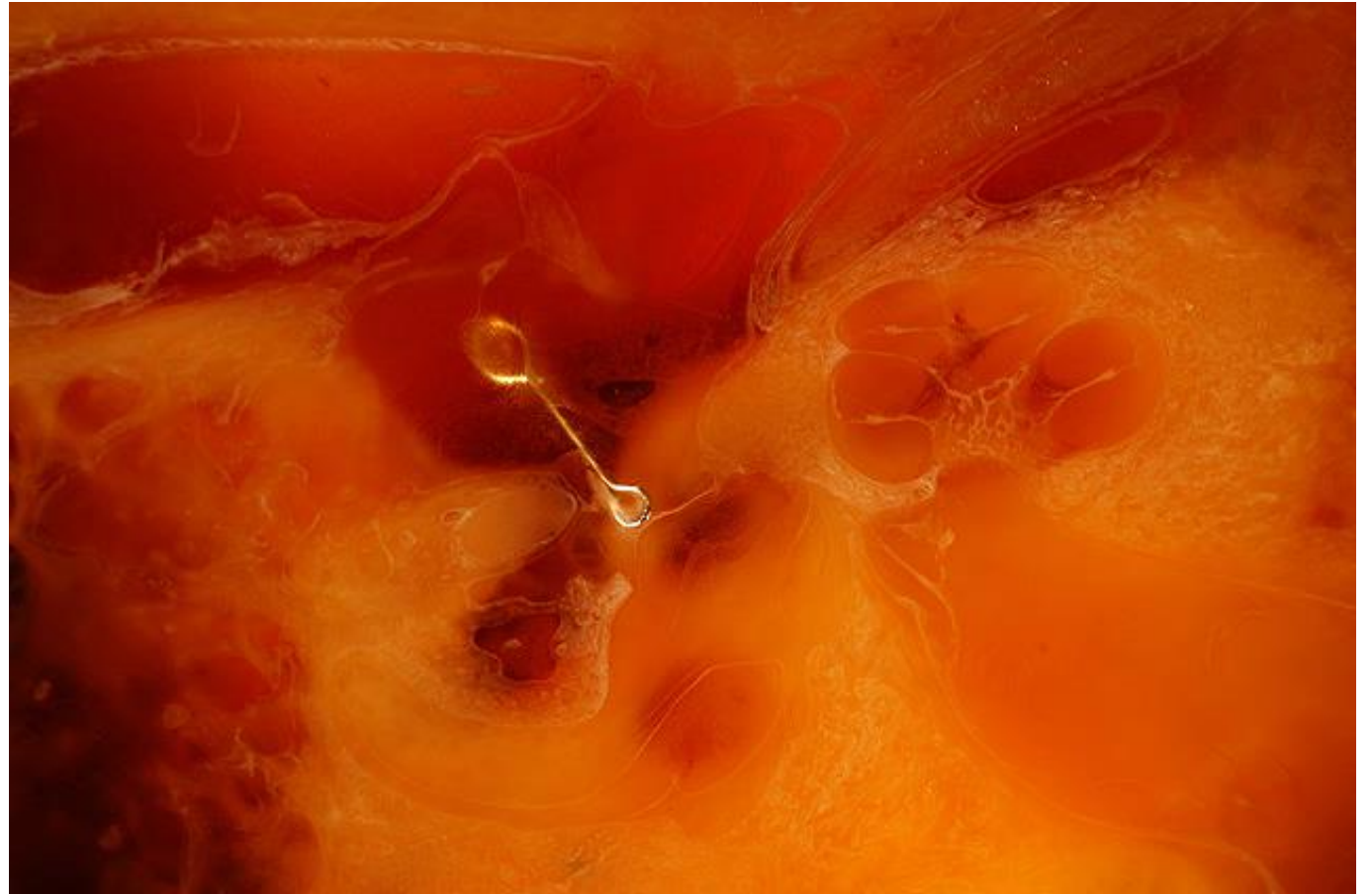Chapter Section: Surgery for Otosclerosis

TB Case Number: 1012

Comments: 86 yr. old woman with otosclerosis. Underwent stapedectomy with 4.5 mm gel wire prosthesis at age 58. She had a residual 10-30 dB air-bone gap. There are adhesions between the wire and facial canal, probably responsible for the gap.

Gender: Female

Age (yrs.): 86



Stapedectomy, L-241.1

Title: Stapedectomy, L-241-1

Chapter: Surgical Pathology

Chapter Section: Surgery for Otosclerosis

TB Case Number: 992

Gender: Female

Age (yrs.): 95

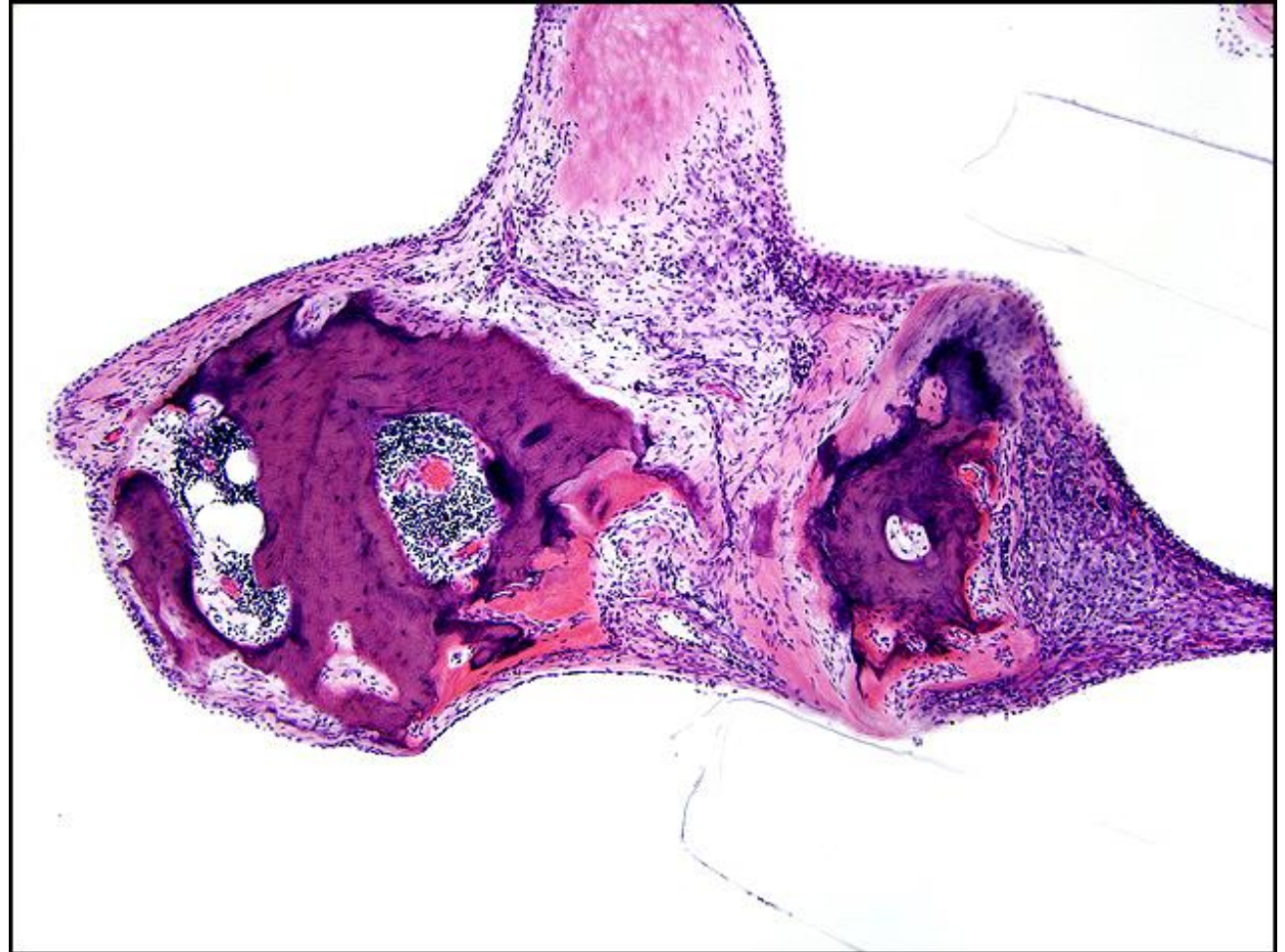Otologic Diagnosis:

Clinical Diagnoses:

1. Otosclerosis, bilateral
2. Profound hearing loss, left, status post total stapedectomy with polyethylene strut
3. Mixed hearing loss, right, associated with otosclerosis

Histologic Diagnoses:

Otosclerosis, clinical, bilateral



Labyrinthitis Ossificans, L-241

Title: Labyrinthitis Ossificans, L-241

Chapter: Surgical Pathology

Chapter Section: Surgery for Otosclerosis

TB Case Number: 992

Comments: Stapedectomy Polyethylene tube prosthesis with labyrinthitis ossificans

Gender: Female

Age (yrs.): 95

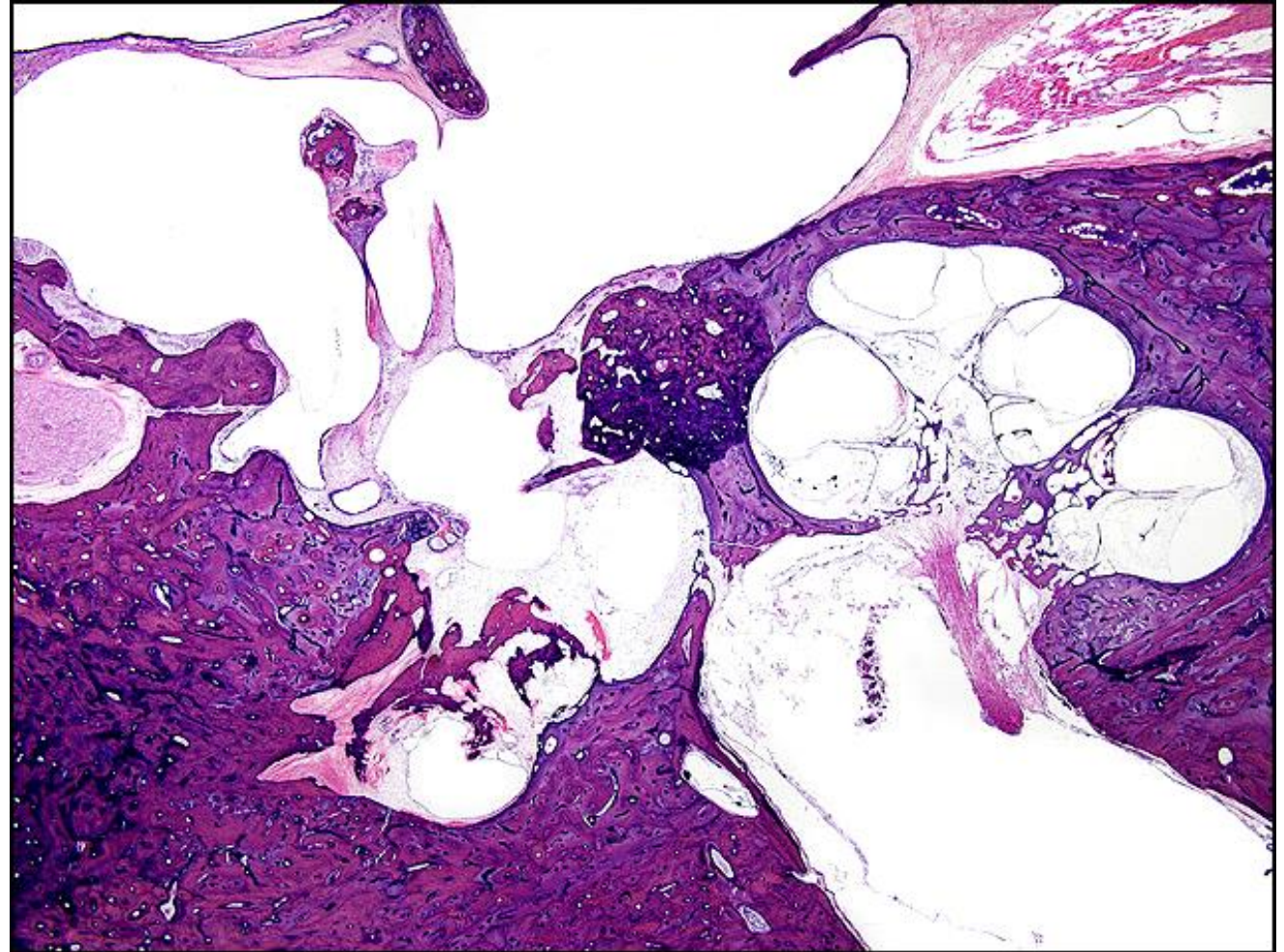
Otologic Diagnosis:

Clinical Diagnoses:

1. Otosclerosis, bilateral
2. Profound hearing loss, left, status post total stapedectomy with polyethylene strut
3. Mixed hearing loss, right, associated with otosclerosis

Histologic Diagnoses:

Otosclerosis, clinical, bilateral



Stapes Mobilization, L-174

Title: Stapes mobilization, L-174

Chapter: Surgical Pathology

Chapter Section: Surgery for Otosclerosis

TB Case Number: 1015

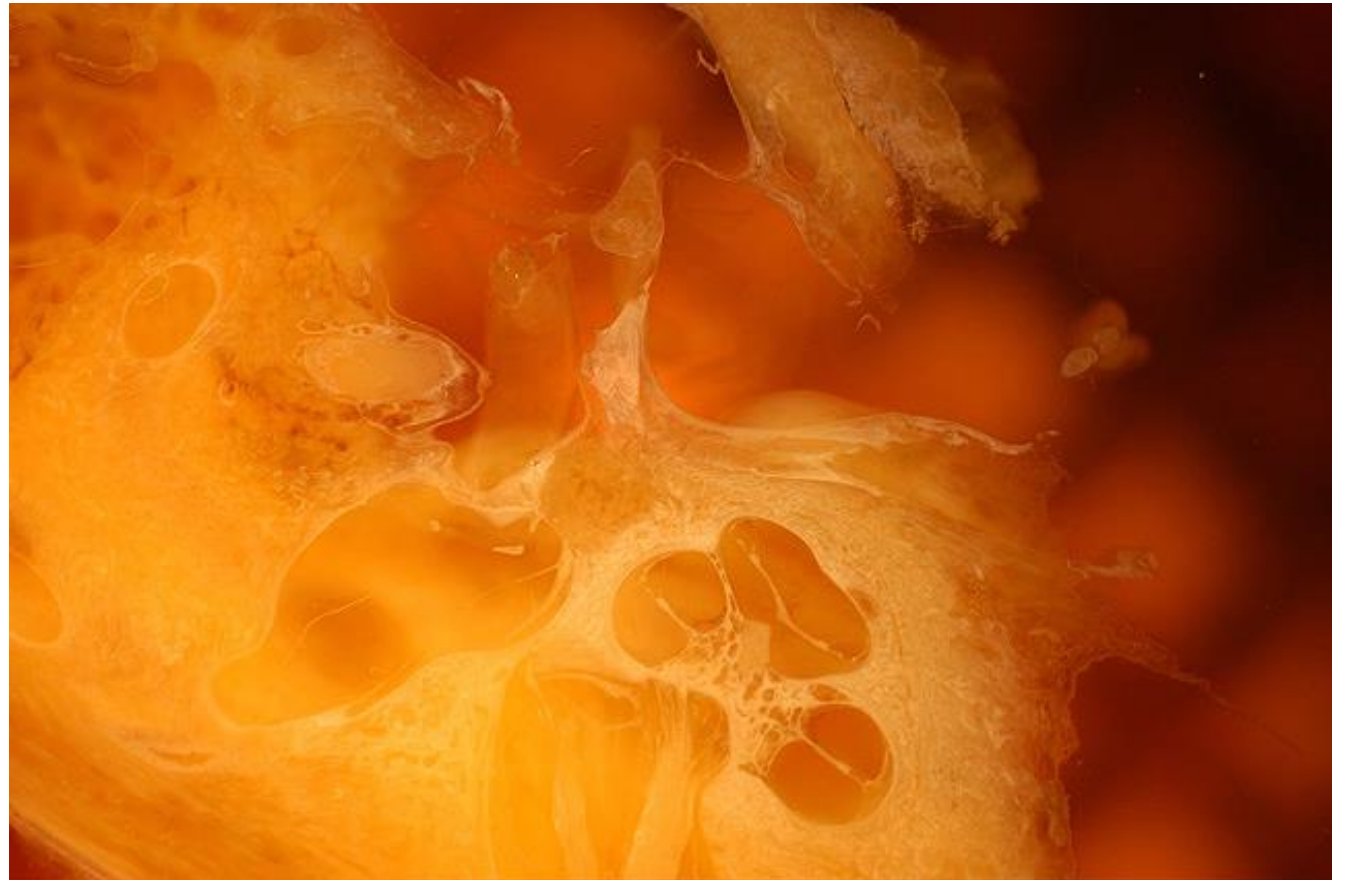Comments: 91 yr. old F with stapes footplate mobilization, removal of superstructure and placement of Polyethylene Tube Prosthesis at age 50 for otosclerosis. Preop 50-60 dB air-bone gap. Post-op air-bone gap of 20-30 dB for remainder of life.

Gender: Female

Age (yrs.): 92

Otologic Diagnosis:

1. Otosclerosis, S/P mobilization of stapes footplate with polyethylene tube prosthesis, left
2. Chronic otitis media with central perforation and middle ear cholesteatoma, S/P tympanoplasty type III (minor columella, polyethylene strut), right



Stapes Mobilization, L-200

Title: Stapes Mobilization, L-200

Chapter: Surgical Pathology

Chapter Section: Surgery for Otosclerosis

TB Case Number: 1015

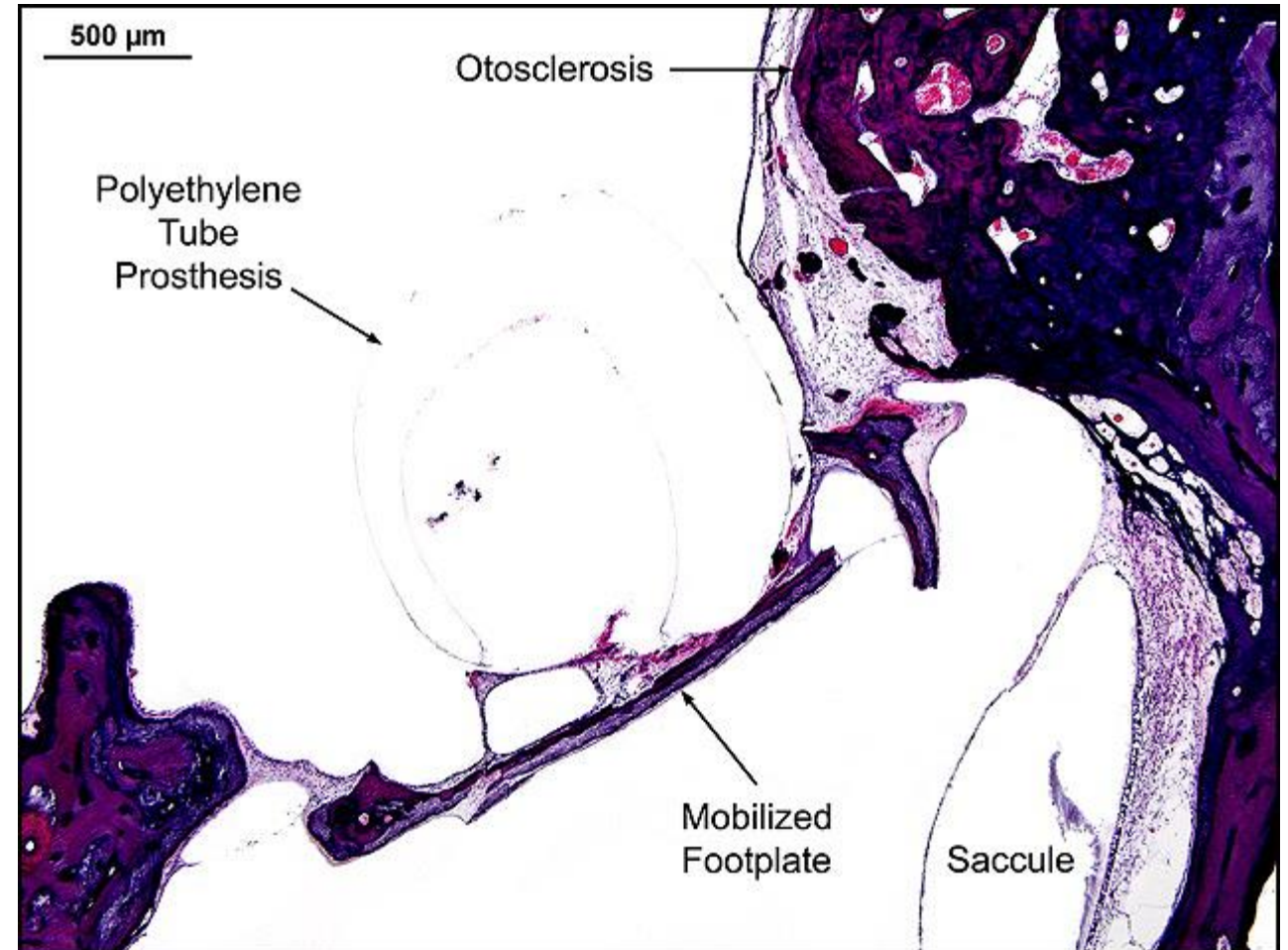
Comments: 91 yr. old F with stapes footplate mobilization, removal of superstructure and placement of Polyethylene Tube Prosthesis at age 50 for otosclerosis. Preop 50-60 dB air-bone gap. Post-op air-bone gap of 20-30 dB for remainder of life.

Gender: Female

Age (yrs.): 92

Otologic Diagnosis:

1. Otosclerosis, S/P mobilization of stapes footplate with polyethylene tube prosthesis, left
2. Chronic otitis media with central perforation and middle ear cholesteatoma, S/P tympanoplasty type III (minor columella, polyethylene strut), right



Stapes Mobilization, L-222

Title: Stapes Mobilization, L-222

Chapter: Surgical Pathology

Chapter Section: Surgery for Otosclerosis

TB Case Number: 1015

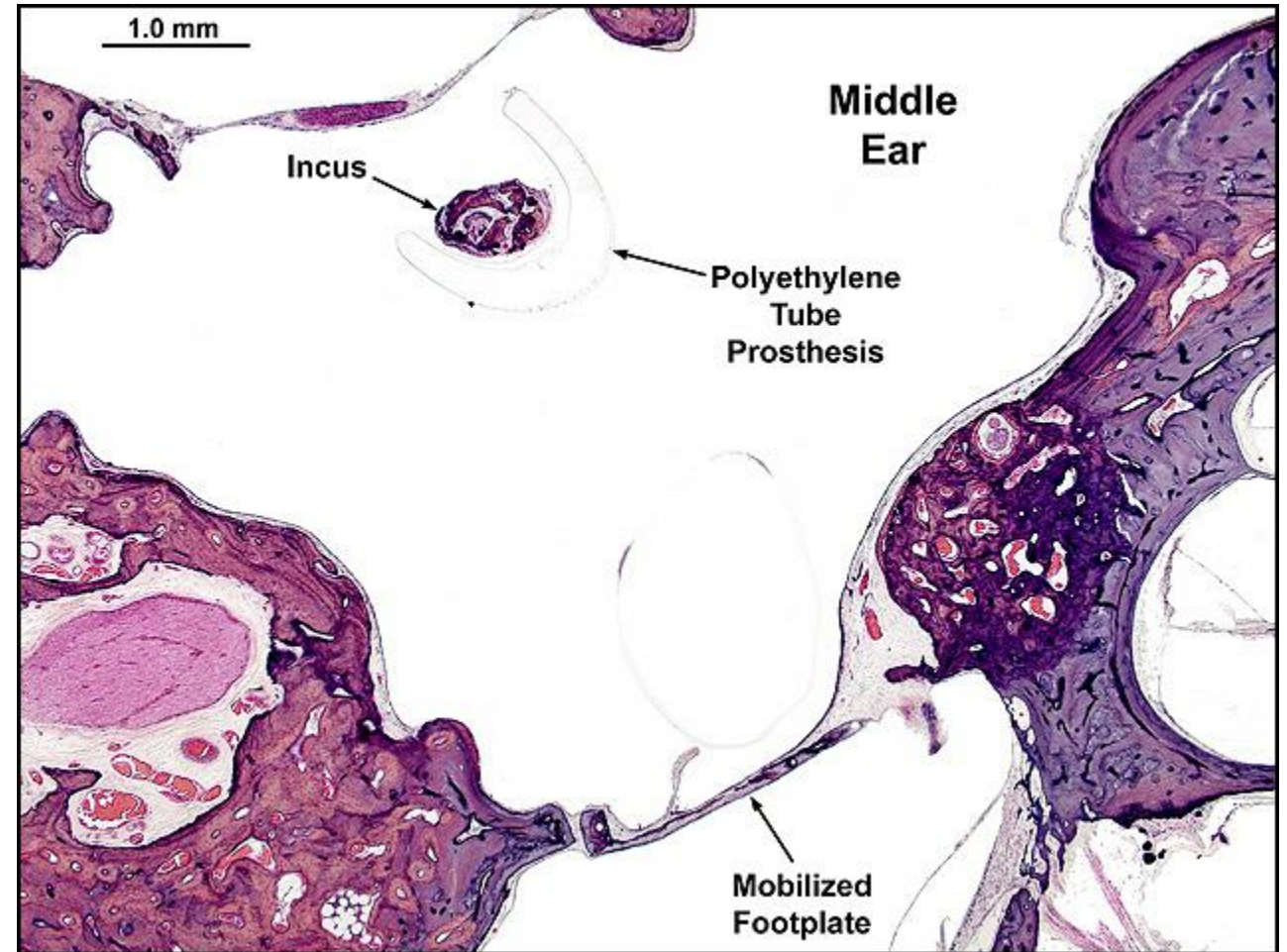
Comments: 91 yr. old F with stapes footplate mobilization, removal of superstructure and placement of Polyethylene Tube Prosthesis at age 50 for otosclerosis. Preop 50-60 dB air-bone gap. Post-op air-bone gap of 20-30 dB for remainder of life.

Gender: Female

Age (yrs.): 92

Otologic Diagnosis:

1. Otosclerosis, S/P mobilization of stapes footplate with polyethylene tube prosthesis, left
2. Chronic otitis media with central perforation and middle ear cholesteatoma, S/P tympanoplasty type III (minor columella, polyethylene strut), right

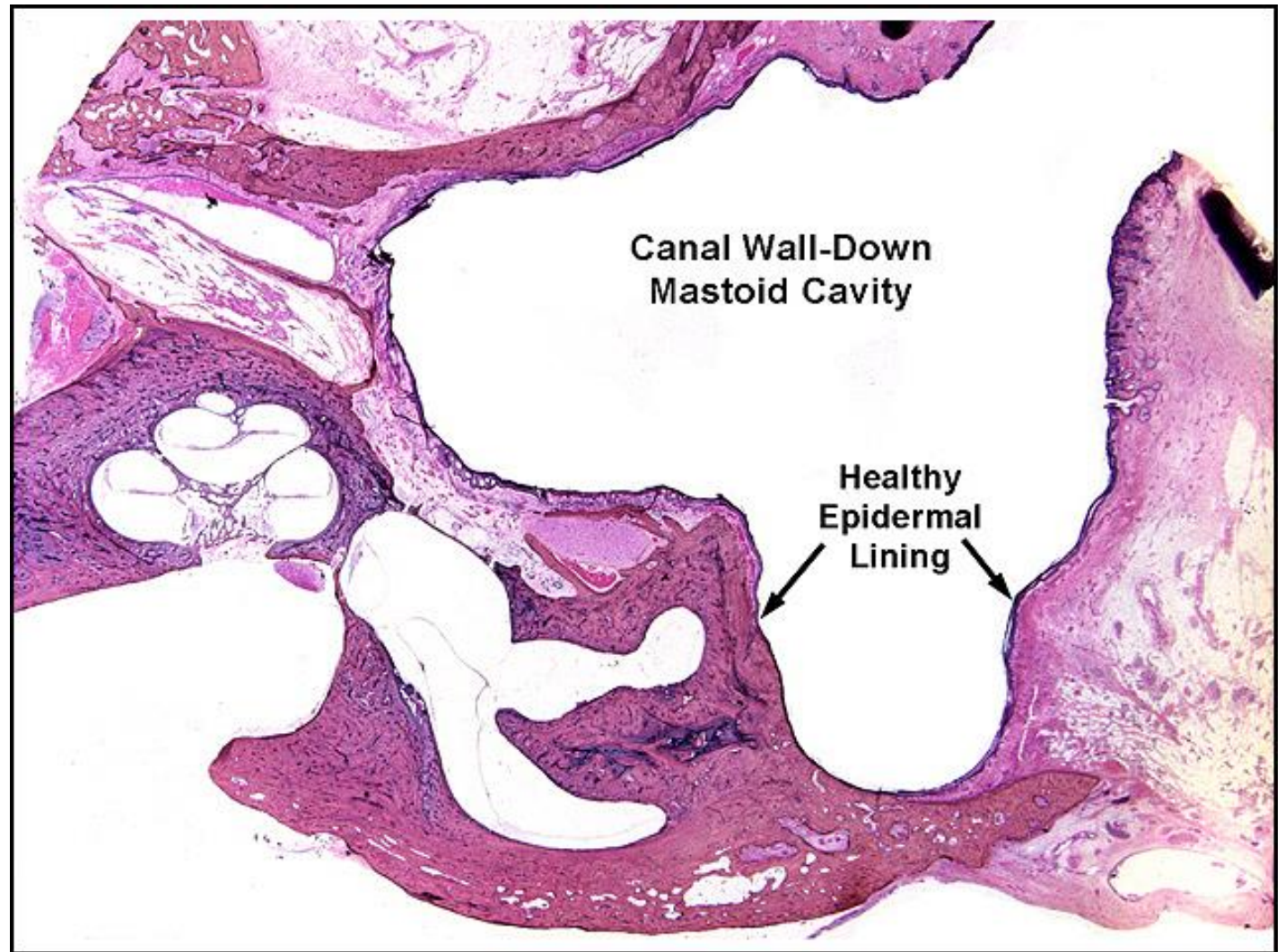


Mastoid Cavity

Title: Mastoid Cavity

Chapter: Surgical Pathology

Chapter Section: Surgery for Otitis Media
Mastoidectomy

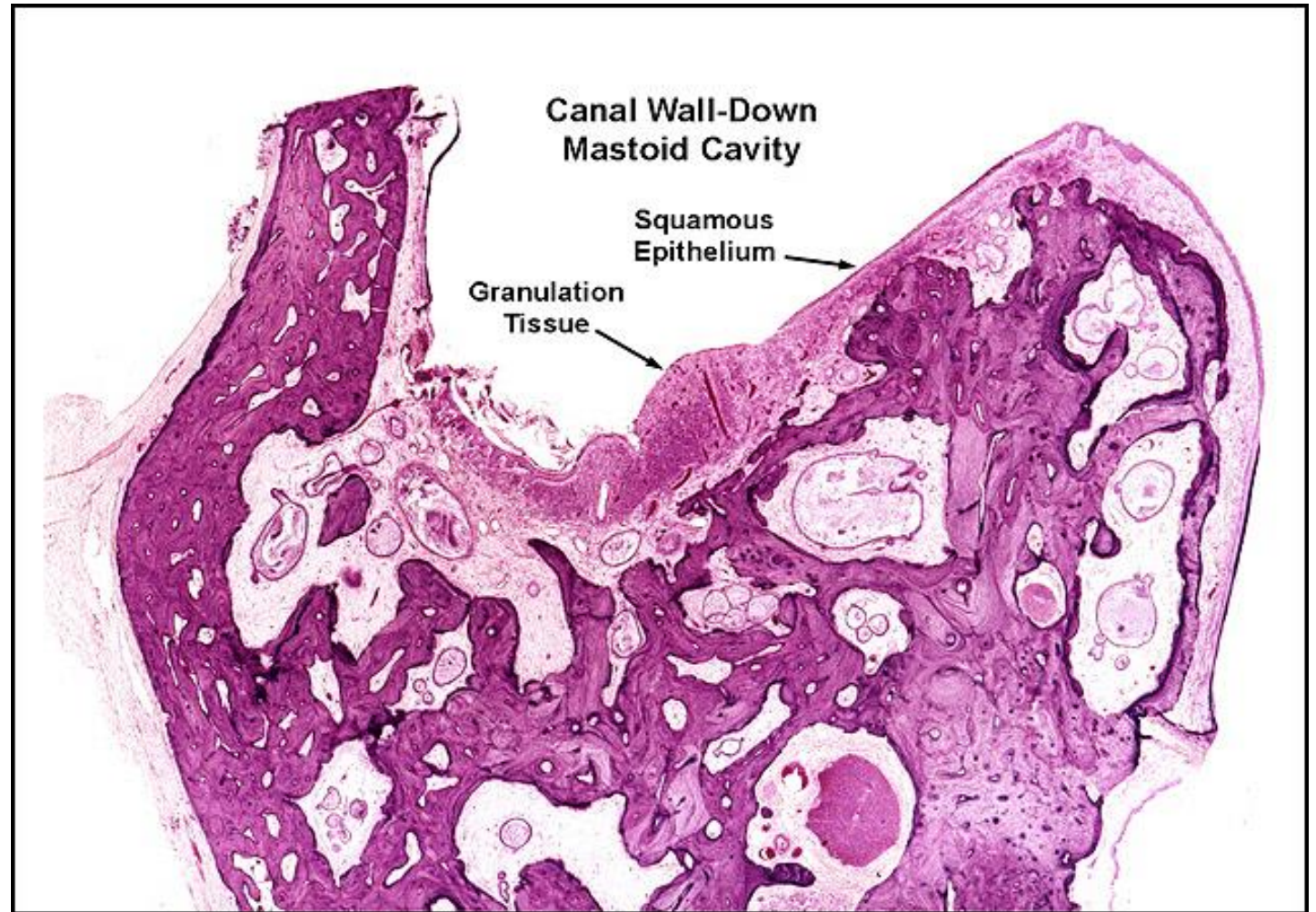


Mastoid Cavity

Title: Mastoid cavity

Chapter: Surgical Pathology

Chapter Section: Surgery for Otitis Media
Mastoidectomy



Radical Mastoidectomy, R-220

Title: Radical Mastoidectomy, R-220

Chapter: Surgical Pathology

Chapter Section: Surgery for Otitis Media
Mastoidectomy

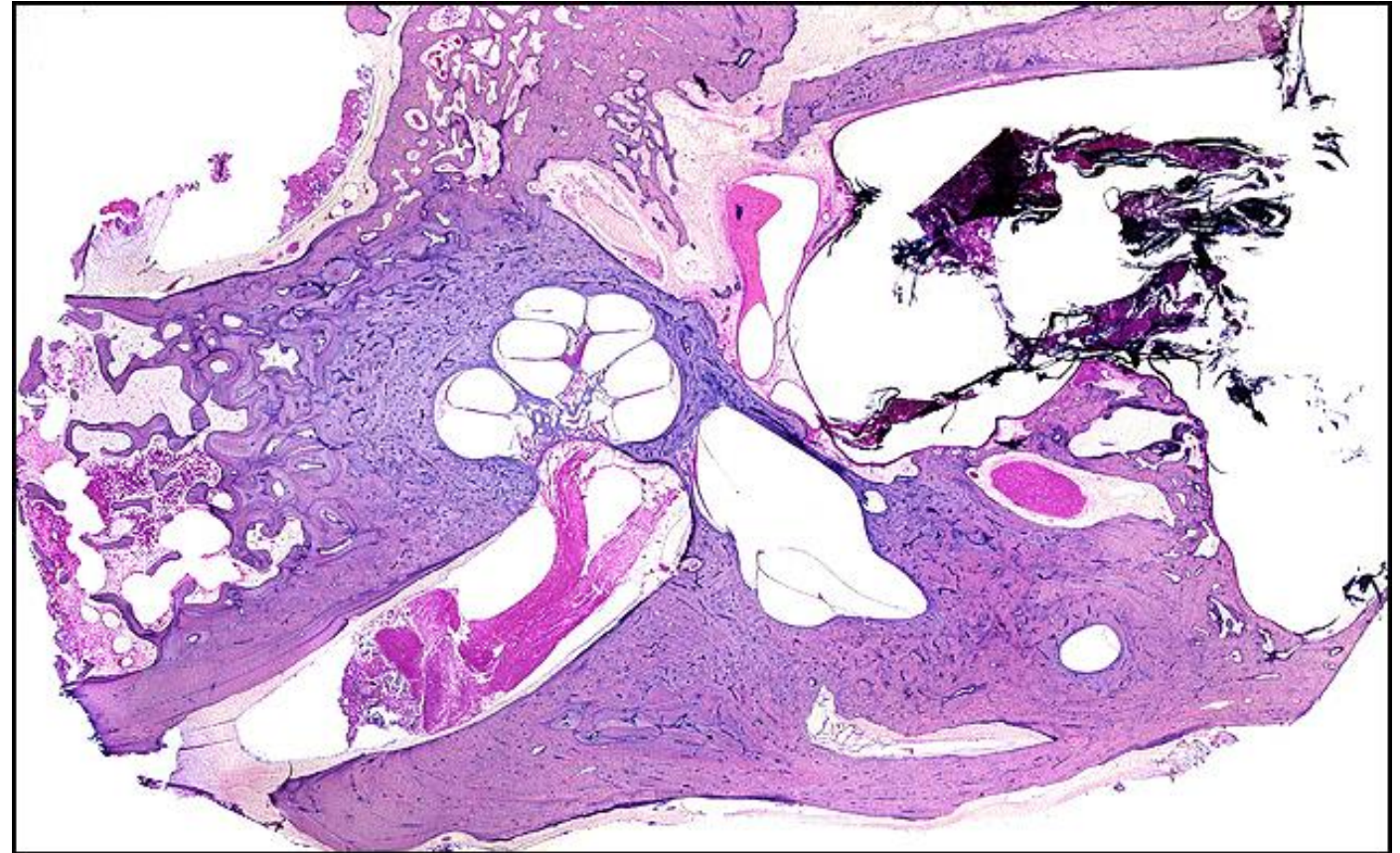
TB Case Number: 11

Gender: Male

Age (yrs.): 56

Otologic Diagnosis:

1. Cholesteatoma, external auditory canals, bilateral
2. External auditory canal, resorption of the posterior wall with the creation of a “nature’s radical”, right
3. Bony fistula, lateral semicircular canal, right
4. Epitympanic and mesotympanic retraction pocket



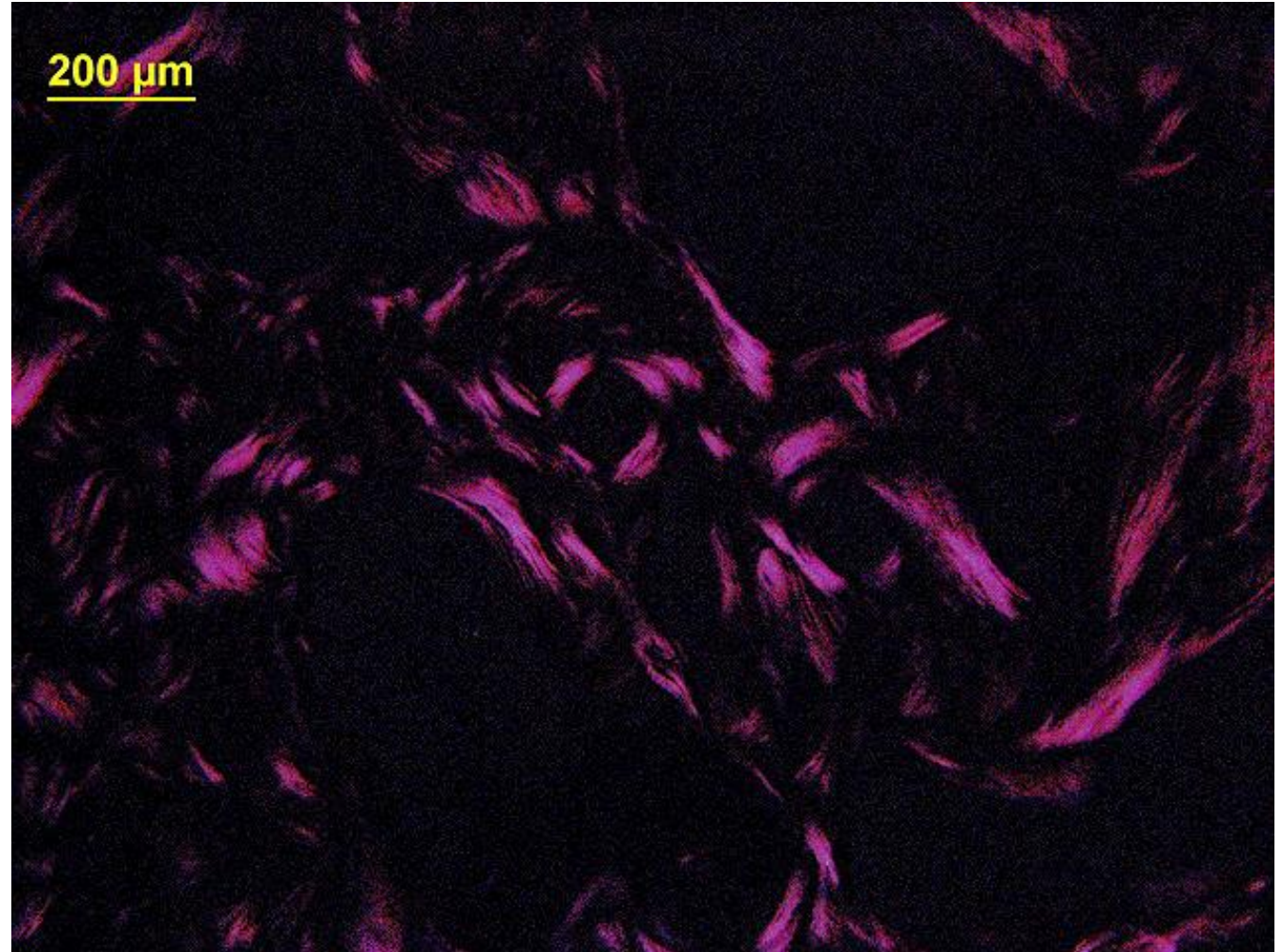
Bone Pate, 225.2

Title: Bone Pate, 225.2

Chapter: Surgical Pathology

Chapter Section: Surgery for Otitis Media
Mastoidectomy

Comments: Bone pate implanted for 5 years.
Polarized light showing lamellar bone.



Incus Autograft

Title: Incus Autograft

Chapter: Surgical Pathology

Chapter Section: Surgery for Otitis Media
Ossiculoplasty

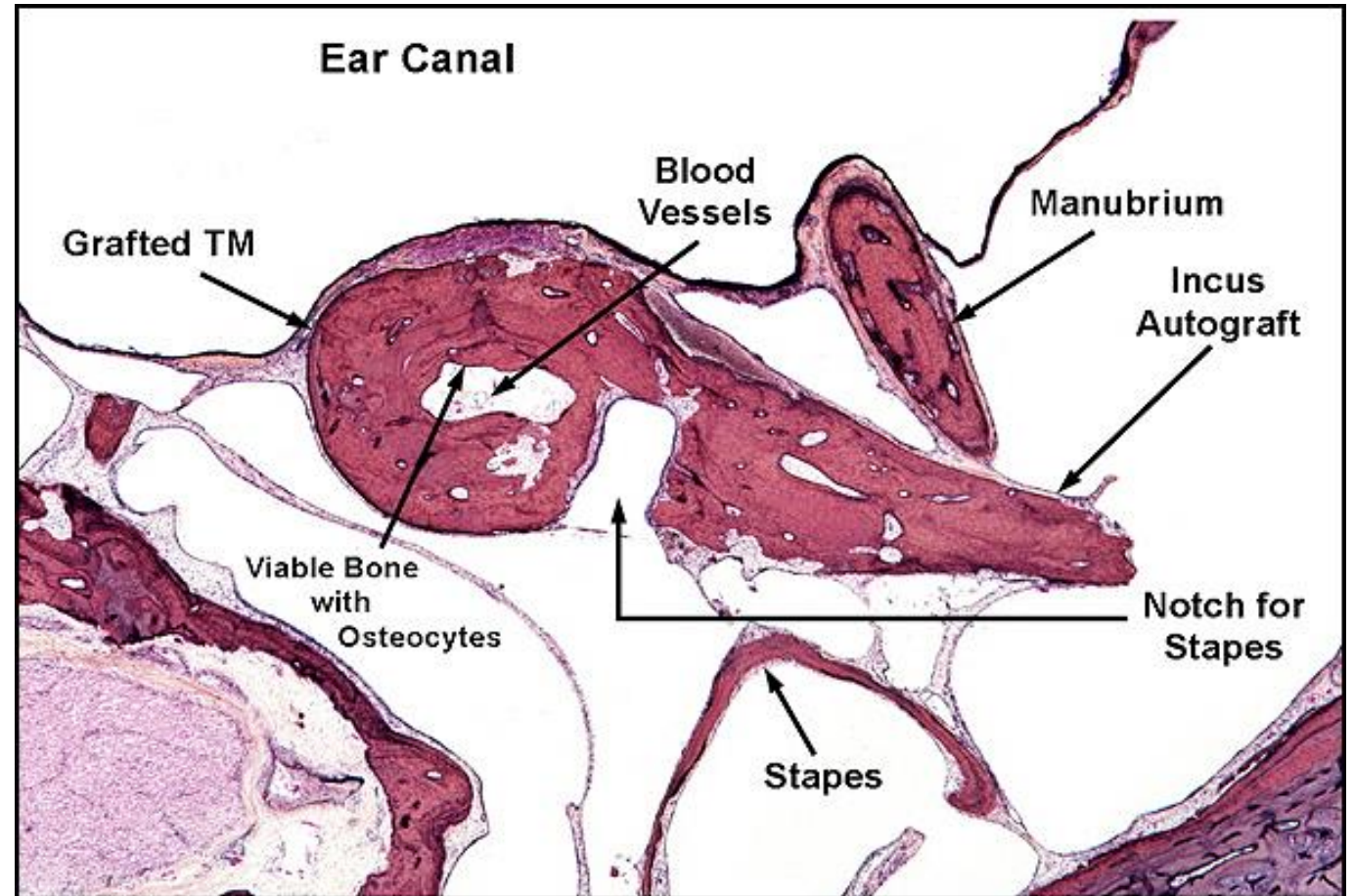
TB Case Number: 938

Gender: Female

Age (yrs.): 87

Otologic Diagnosis:

1. Otitis media and mastoiditis, chronic, bilateral
2. Cholesteatoma, acquired, epitympanum, right
3. Effusion, middle ear, right
4. Sclerosis, fibrocystic and fibro-osseous, middle ear and mastoid, right
5. Granuloma, cholesterol, mastoid, right
6. Retraction pocket



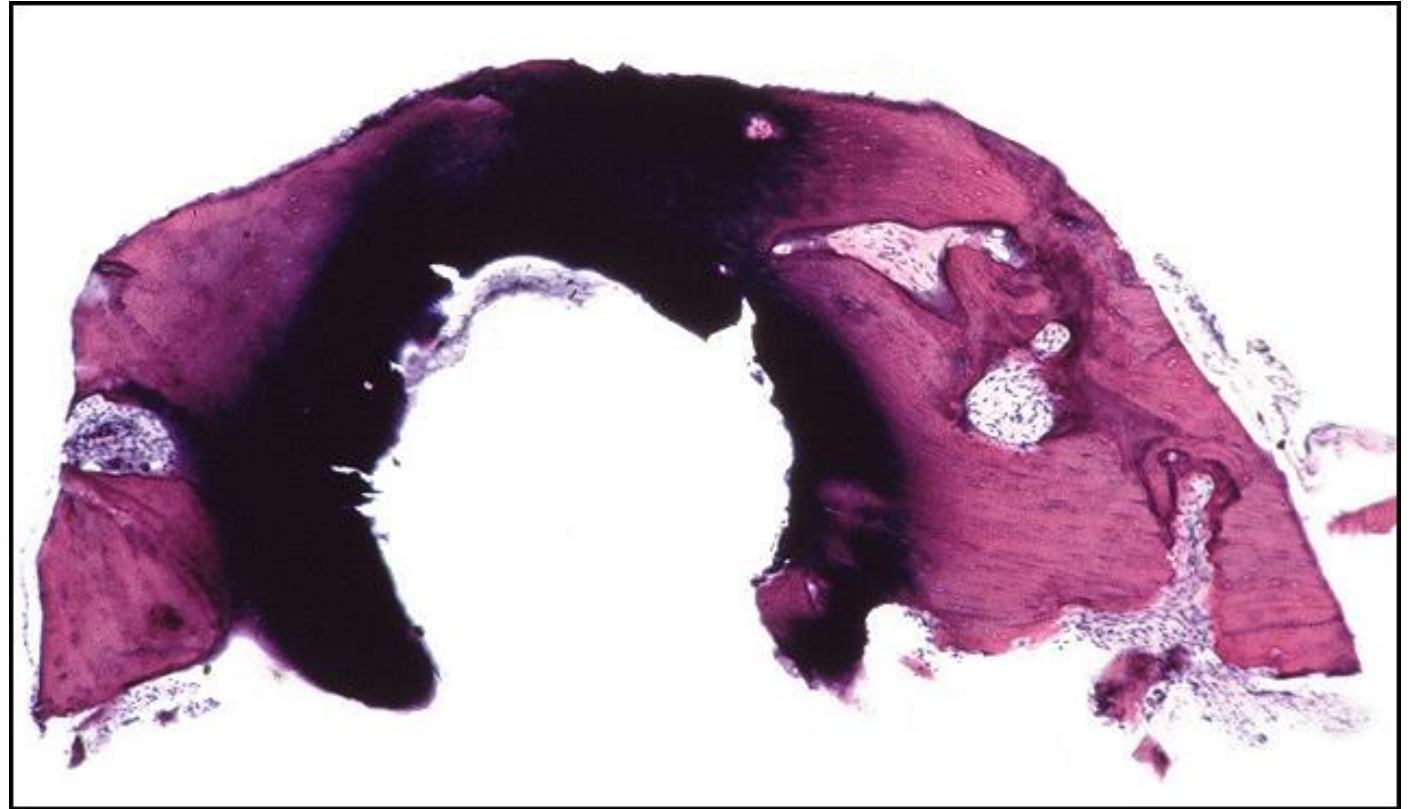
Incus Autograft

Title: Incus Autograft

Chapter: Surgical Pathology

Chapter Section: Surgery for Otitis Media
Ossiculoplasty

Comments: Thermal trauma to autograft strut



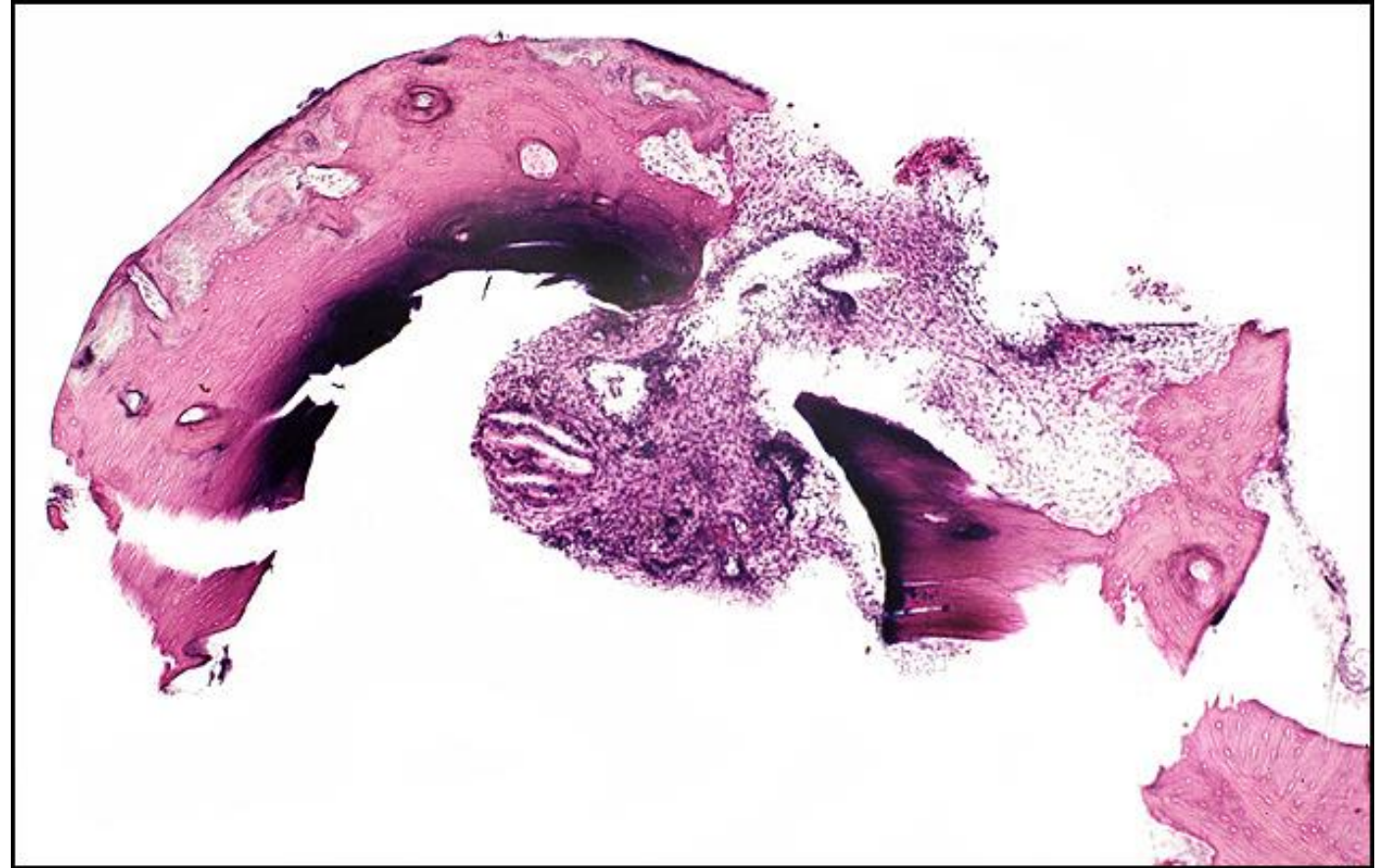
Incus Autograft, 50

Title: Incus Autograft, 50

Chapter: Surgical Pathology

Chapter Section: Surgery for Otitis Media
Ossiculoplasty

Comments: Thermal trauma to autograft strut

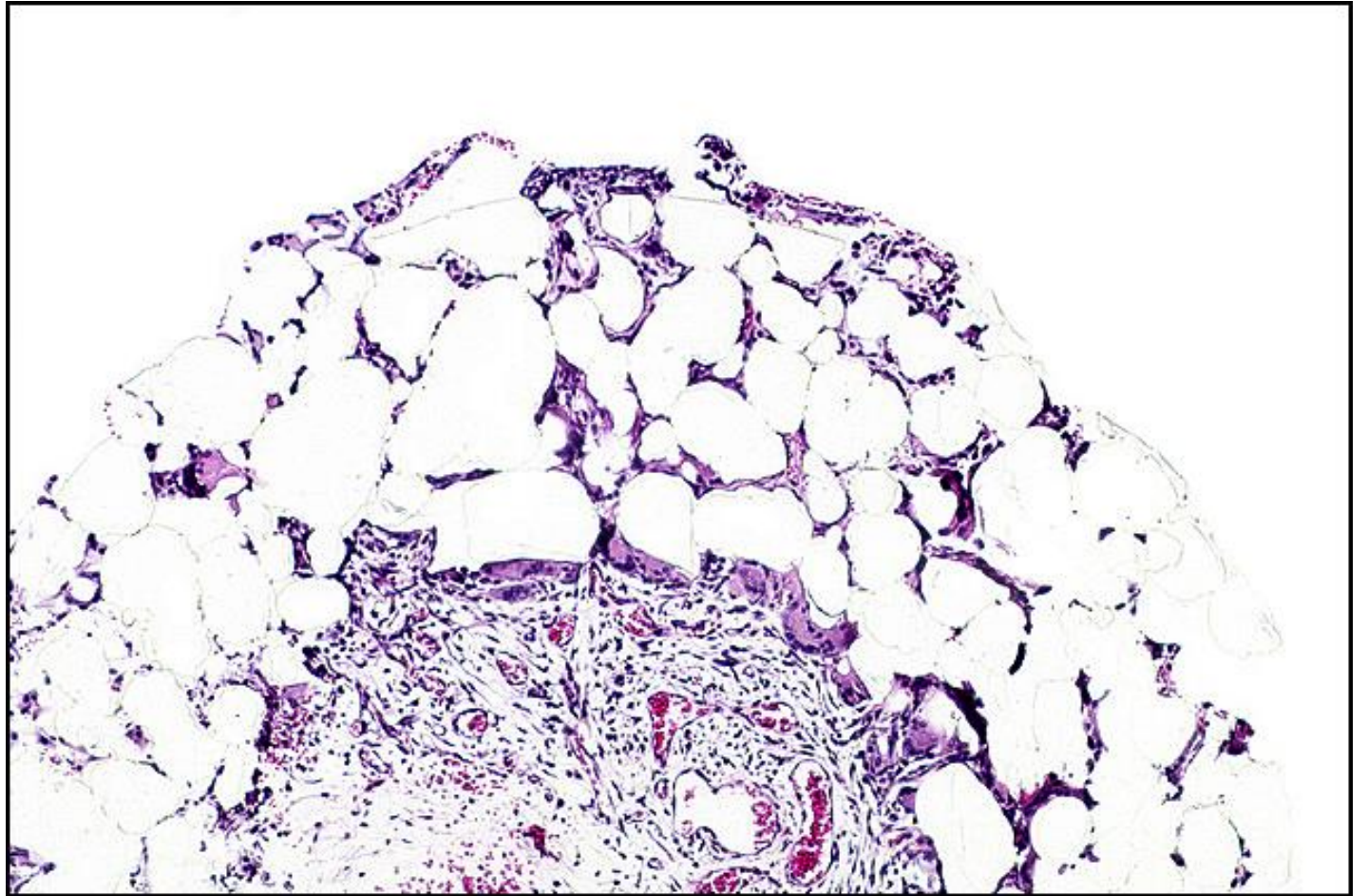


Plastipore PORP, 32

Title: Plastipore PORP, 32

Chapter: Surgical Pathology

Chapter Section: Surgery for Otitis Media
Ossiculoplasty



Cartilage Autograft, R-351

Title: Cartilage Autograft, R-351

Chapter: Surgical Pathology

Chapter Section: Surgery for Otitis Media
Ossiculoplasty

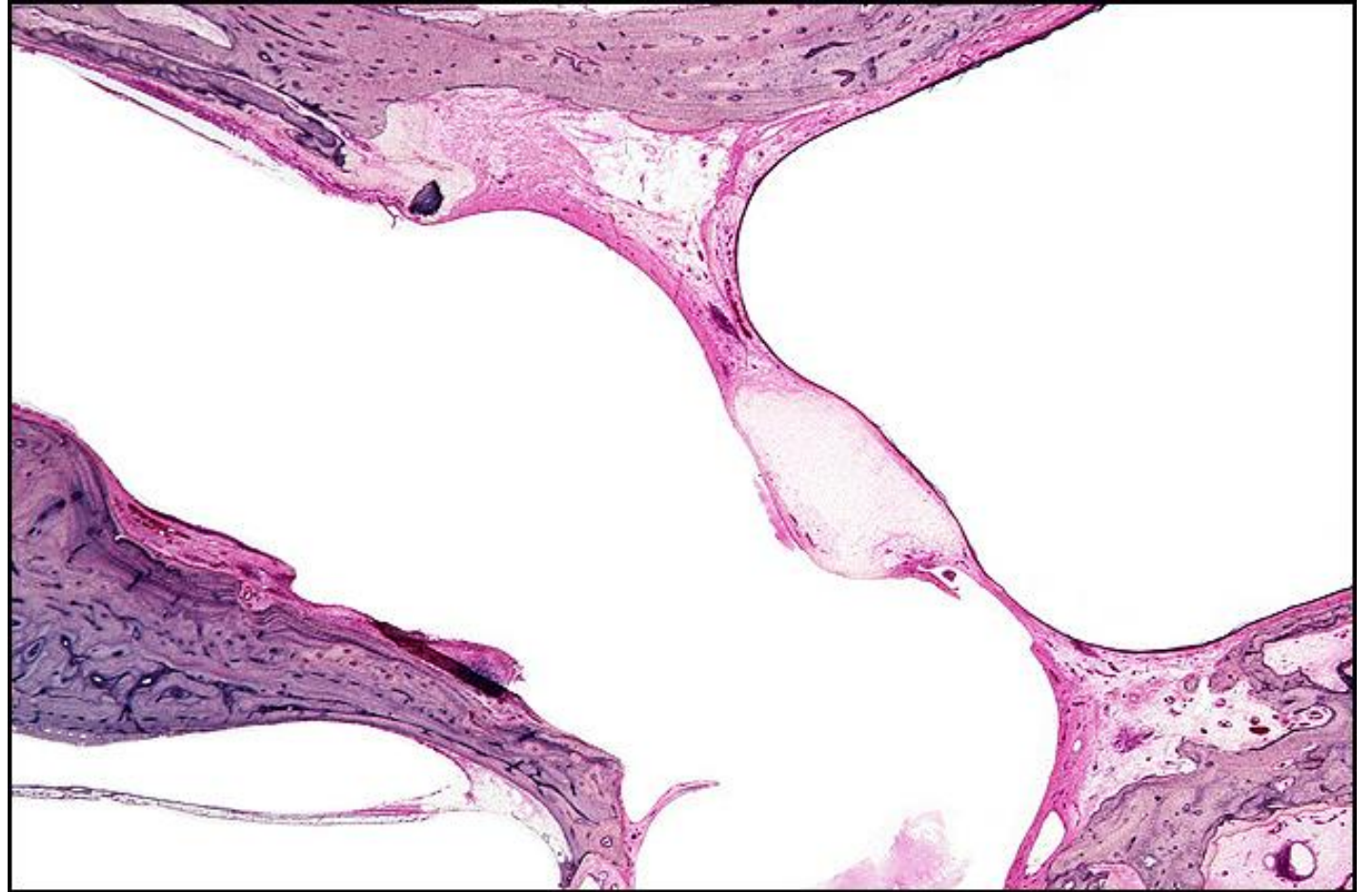
TB Case Number: 440

Gender: Male

Age (yrs.): 62

Otologic Diagnosis:

1. Chronic otitis media, inactive, bilateral
2. Intact canal wall tympanomastoidectomy, showing posterior tympanotomy, fascial graft myringoplasty, cartilage graft, and Silastic implant, right
3. Devitalization and partial resorption of cartilage implant, right



Cartilage Autograft, R-351.2

Title: Cartilage Autograft, R-351-2

Chapter: Surgical Pathology

Chapter Section: Surgery for Otitis Media
Ossiculoplasty

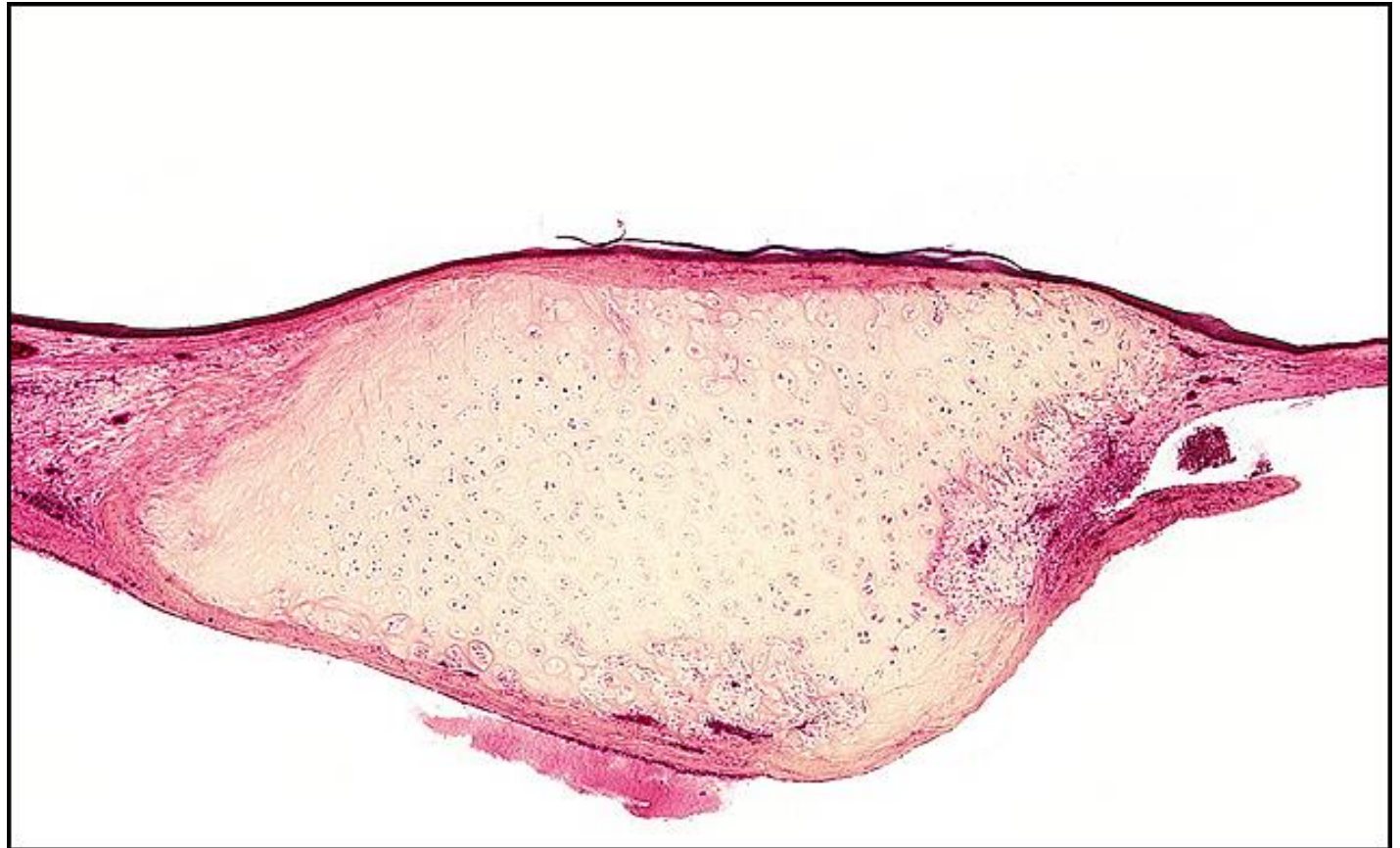TB Case Number: 440

Gender: Male

Age (yrs.): 62

Otologic Diagnosis:

1. Chronic otitis media, inactive, bilateral
2. Intact canal wall tympanomastoidectomy, showing posterior tympanotomy, fascial graft myringoplasty, cartilage graft, and Silastic implant, right
3. Devitalization and partial resorption of cartilage implant, right

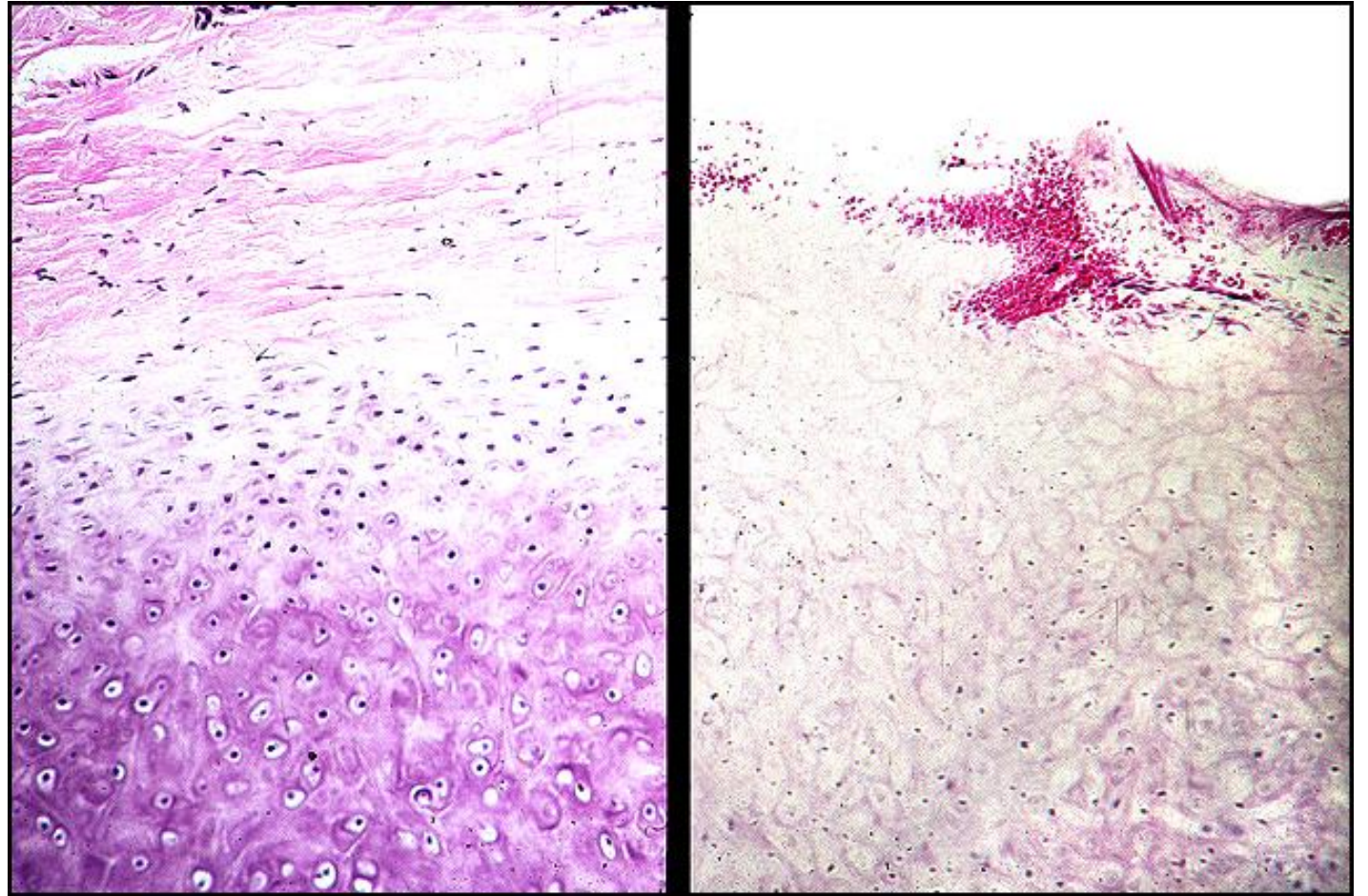


Normal Cartilage vs. Chondromalacia

Title: Normal Cartilage vs. Chondromalacia

Chapter: Surgical Pathology

Chapter Section: Surgery for Otitis Media
Ossiculoplasty



Tympanoplasty with PORP, R-101

Title: Tympanoplasty with PORP, R-101

Chapter: Surgical Pathology

Chapter Section: Surgery for Otitis Media
Ossiculoplasty

TB Case Number: 1015

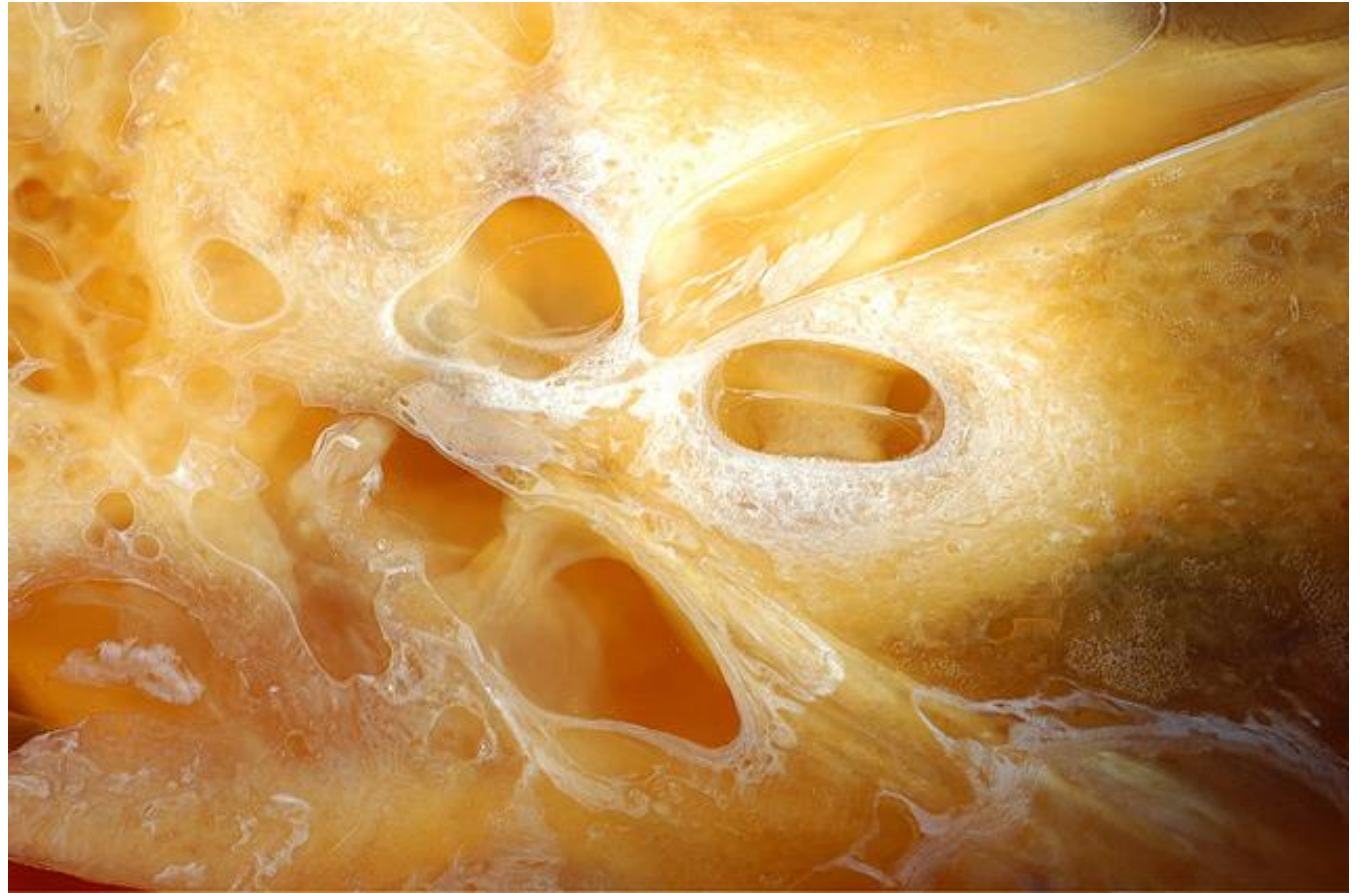Comments: 91 yr. old F with 2 mm polyethylene tube as a strut from stapes head to TM at age 51. Post op large 50 dB air-bone gap. Strut did not make contact with stapes on histology.

Gender: Female

Age (yrs.): 92

Otologic Diagnosis:

1. Otosclerosis, S/P mobilization of stapes footplate with polyethylene tube prosthesis, left
2. Chronic otitis media with central perforation and middle ear cholesteatoma, S/P tympanoplasty type III (minor columella, polyethylene strut), right



Tympanoplasty with PORP, R-155

Title: Tympanoplasty with PORP, R-155

Chapter: Surgical Pathology

Chapter Section: Surgery for Otitis Media
Ossiculoplasty

TB Case Number: 1015

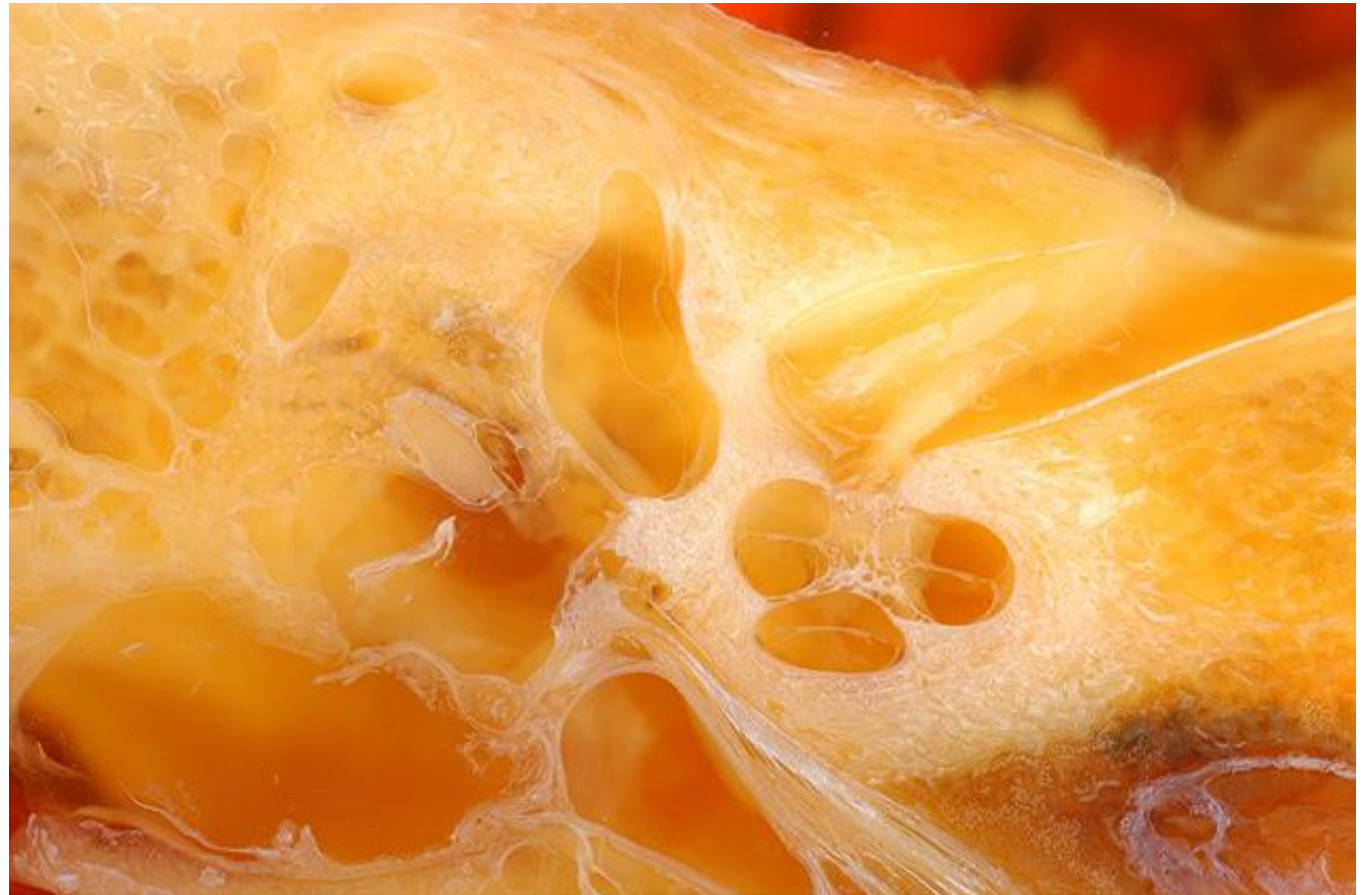Comments: 91 yr. old F with 2 mm polyethylene tube as a strut from stapes head to TM at age 51. Post op large 50 dB air-bone gap. Strut did not make contact with stapes on histology.

Gender: Female

Age (yrs.): 92

Otologic Diagnosis:

1. Otosclerosis, S/P mobilization of stapes footplate with polyethylene tube prosthesis, left
2. Chronic otitis media with central perforation and middle ear cholesteatoma, S/P tympanoplasty type III (minor columella, polyethylene strut), right



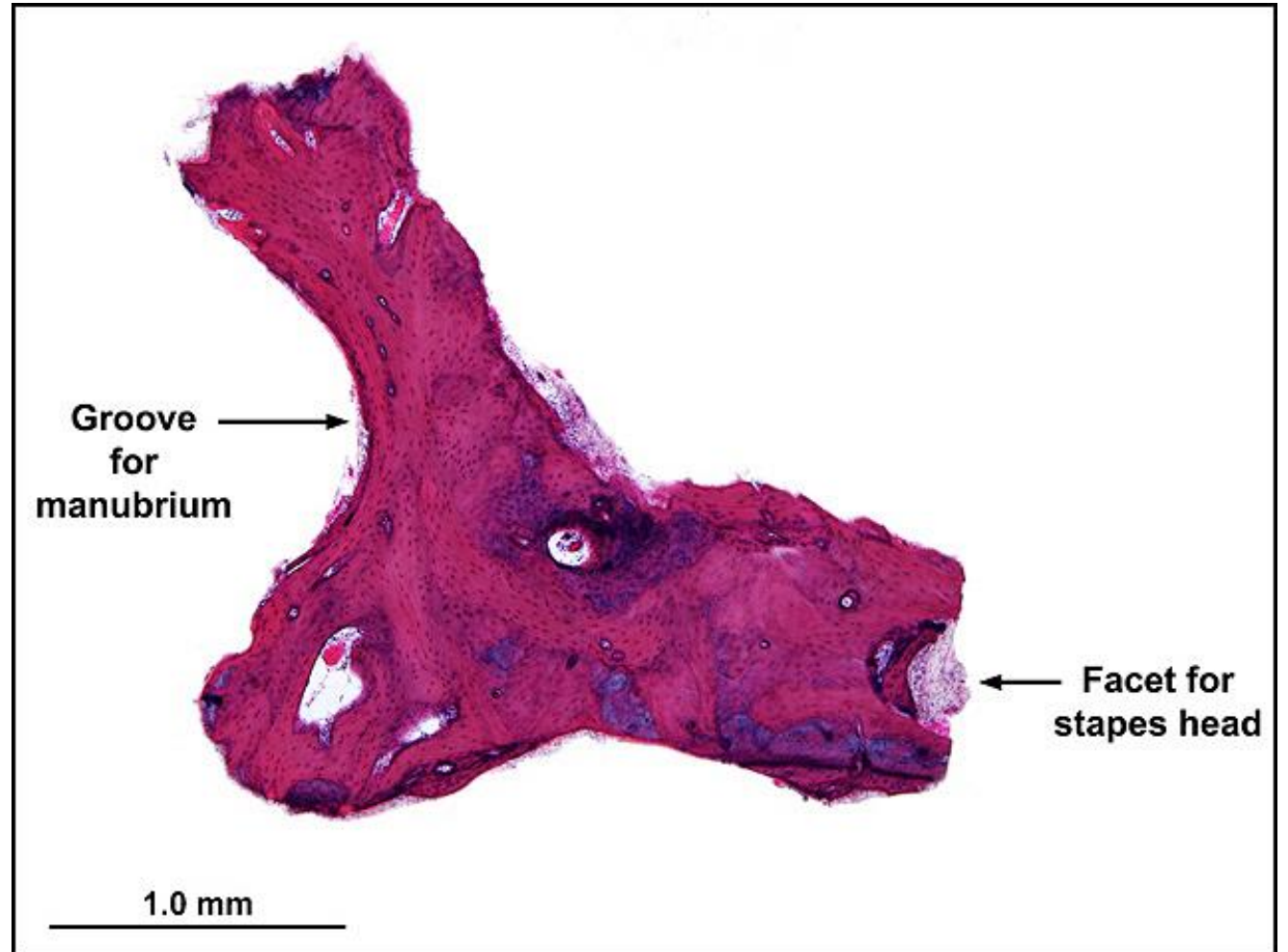
Incus Autograft, 115

Title: Incus Autograft, 115

Chapter: Surgical Pathology

Chapter Section: Surgery for Otitis Media
Ossiculoplasty

Comments: Incus autograft implanted for 2 years.



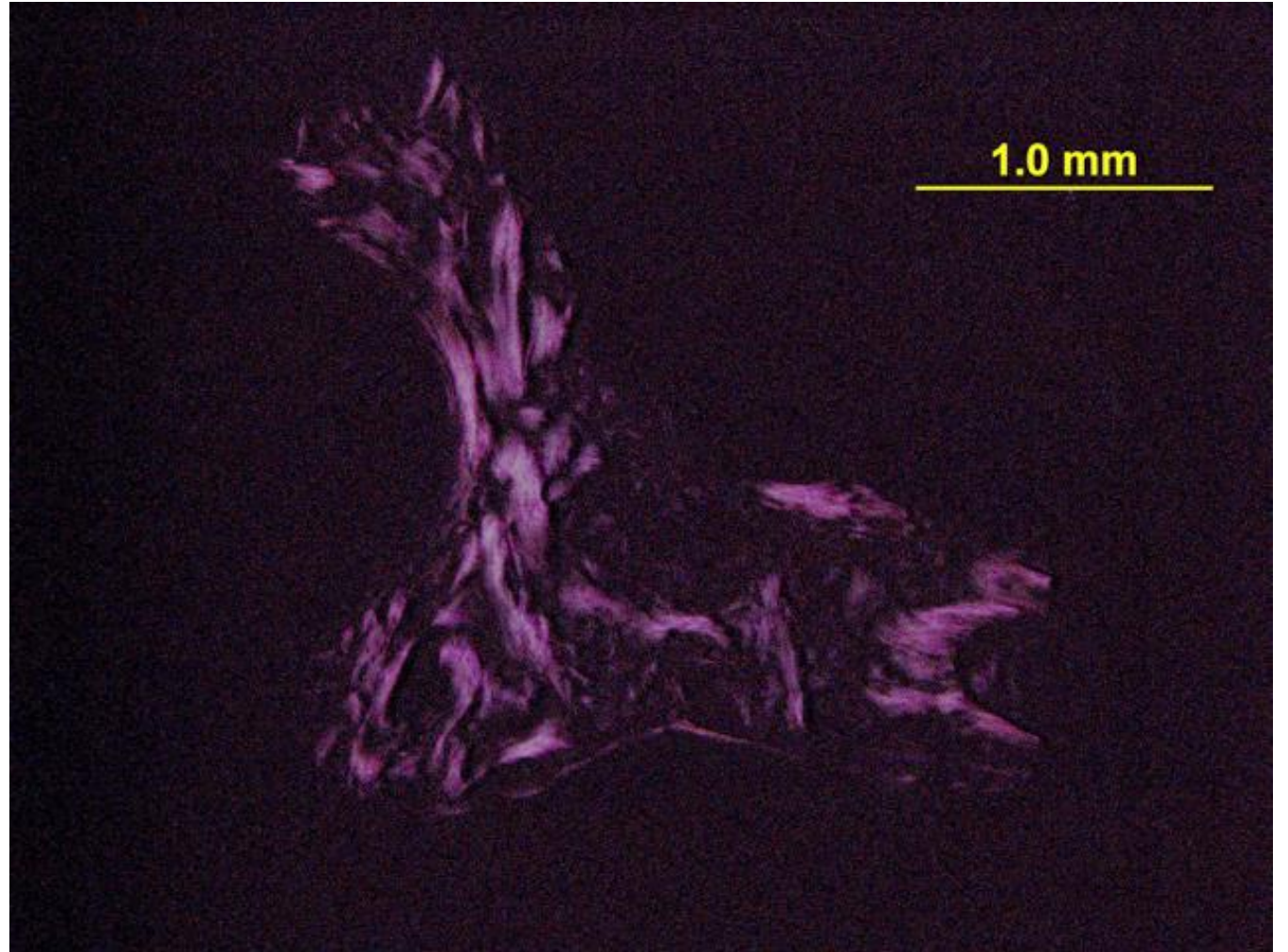
Incus Autograft, 115.3

Title: Incus Autograft, 115.3

Chapter: Surgical Pathology

Chapter Section: Surgery for Otitis Media
Ossiculoplasty

Comments: Incus autograft implanted for 2 years.
Polarized light showing lamellar bone.



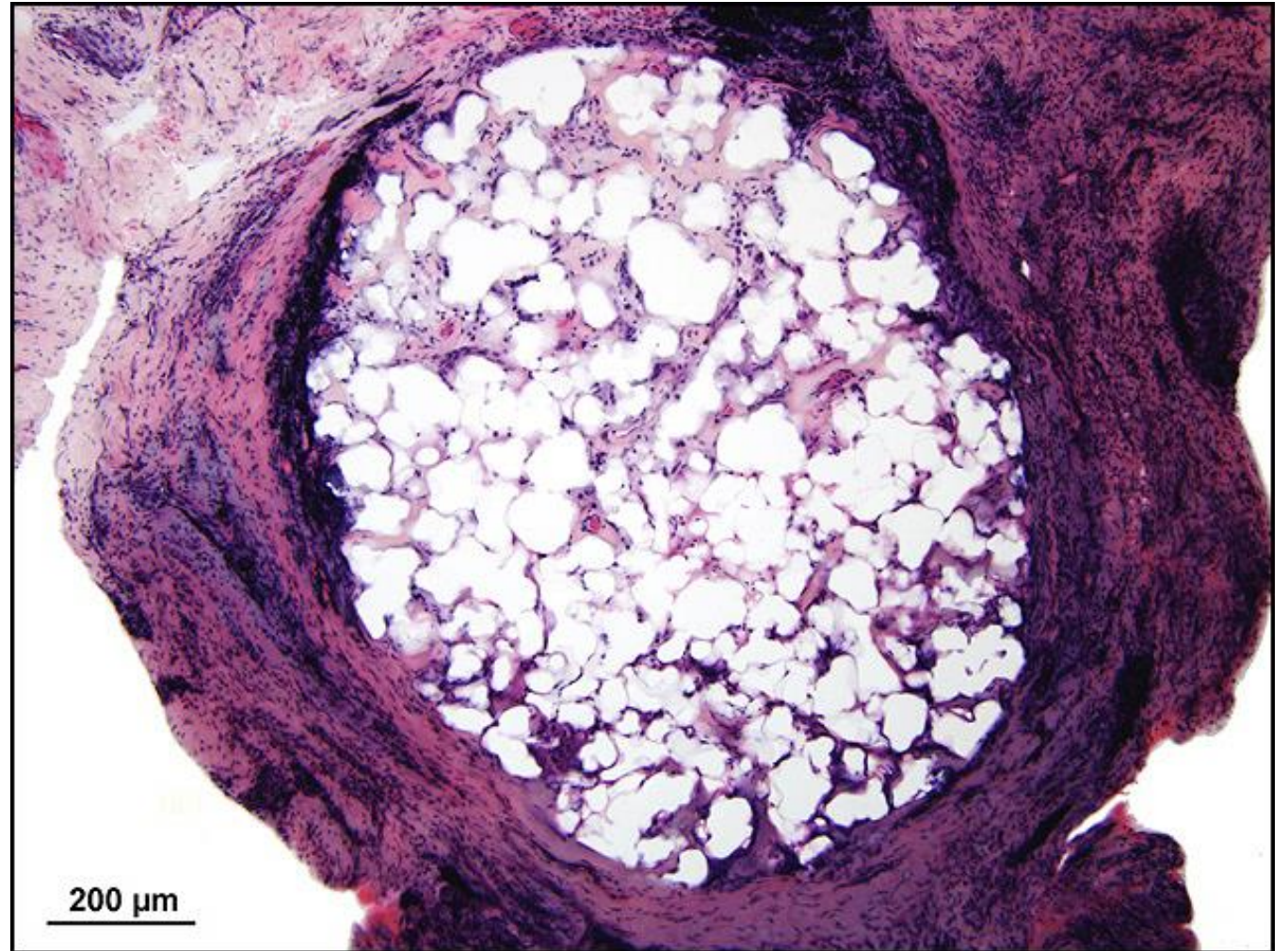
Plastipore TORP, 440.1

Title: Plastipore TORP, 440.1

Chapter: Surgical Pathology

Chapter Section: Surgery for Otitis Media
Ossiculoplasty

Comments: Plastipore TORP implanted for 14 years.
Intense host response with foreign body giant cells
and biodegradation of implant.



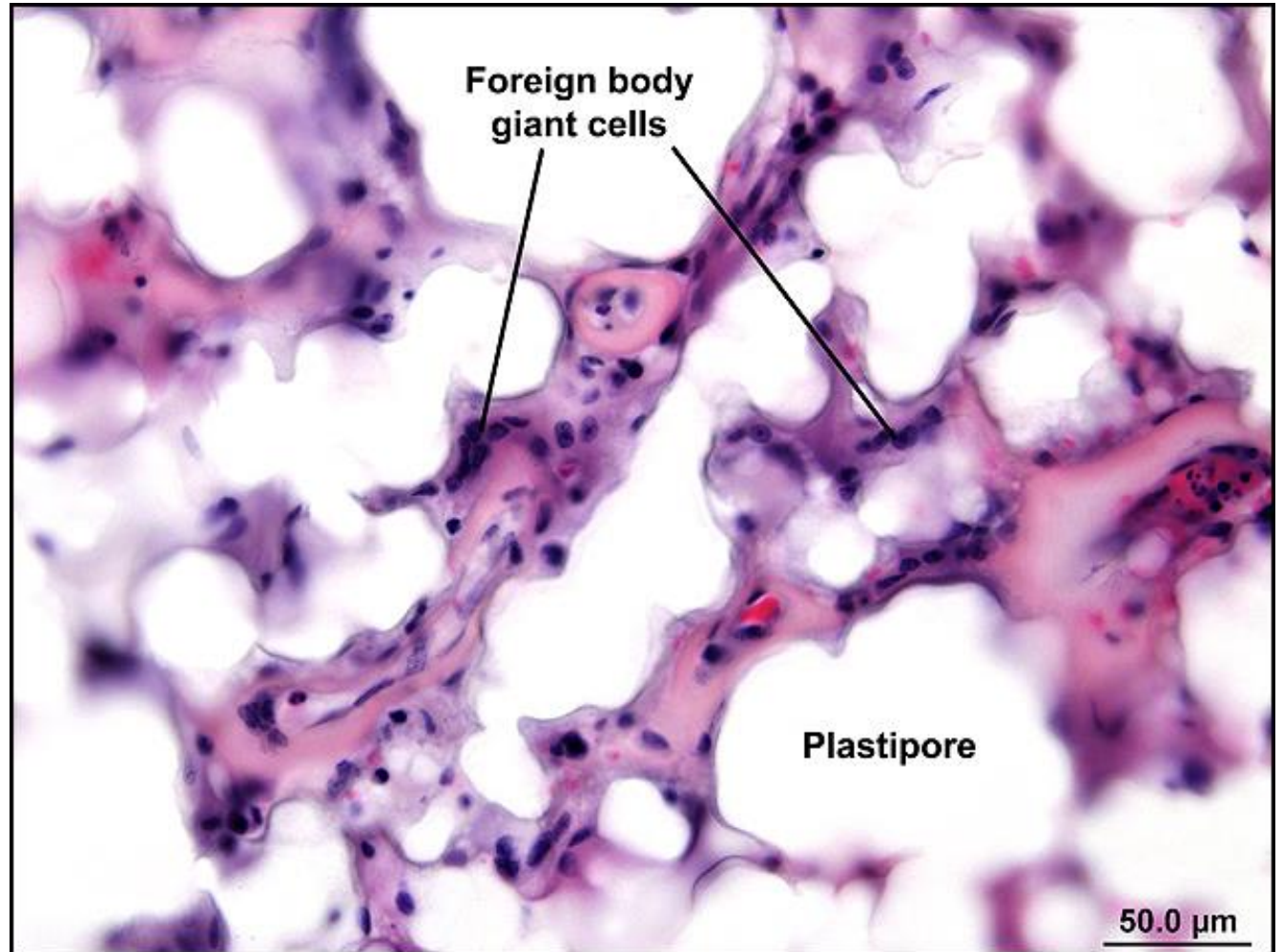
Plastipore TORP, 440

Title: Plastipore TORP, 440

Chapter: Surgical Pathology

Chapter Section: Surgery for Otitis Media
Ossiculoplasty

Comments: Plastipore TORP implanted for 14 years.
Intense host response with foreign body giant cells
and biodegradation of implant.



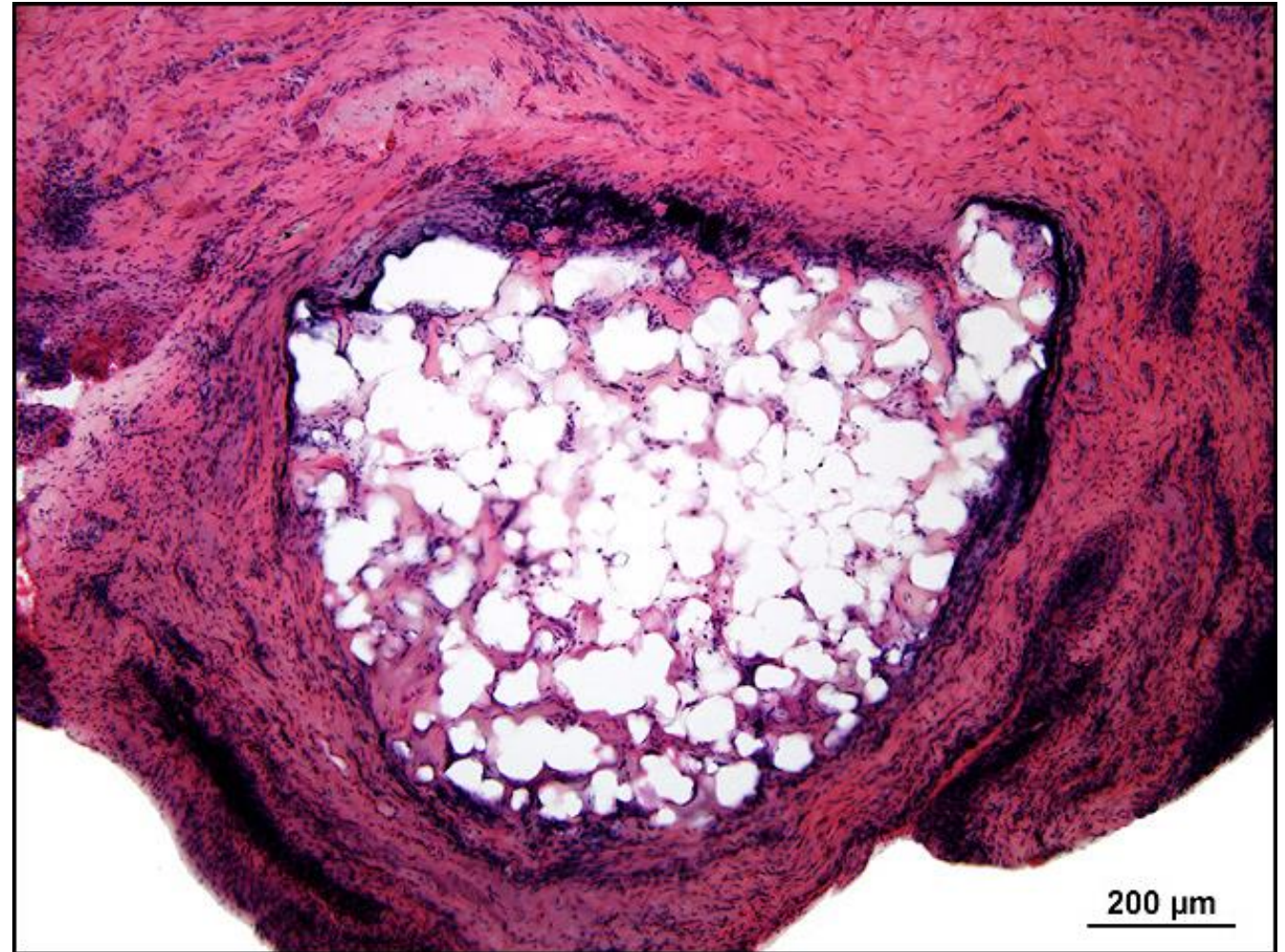Plastipore TORP, 465.1

Title: Plastipore TORP, 465.1

Chapter: Surgical Pathology

Chapter Section: Surgery for Otitis Media
Ossiculoplasty

Comments: Plastipore TORP implanted for 14 years.
Intense host response with foreign body giant cells
and biodegradation of implant.



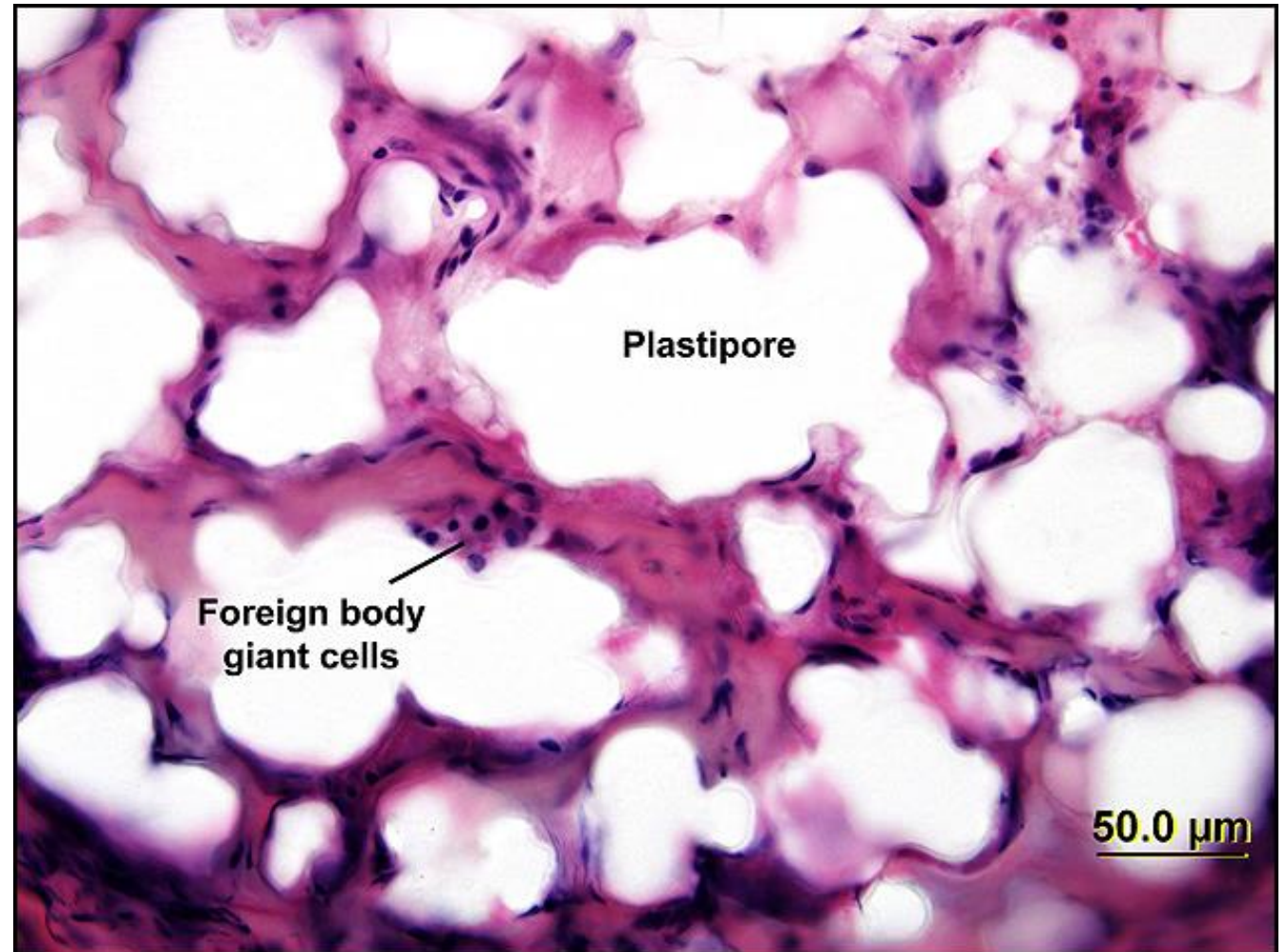
Plastipore TORP, 465

Title: Plastipore TORP, 465

Chapter: Surgical Pathology

Chapter Section: Surgery for Otitis Media
Ossiculoplasty

Comments: Plastipore TORP implanted for 14 years.
Intense host response with foreign body giant cells
and biodegradation of implant.



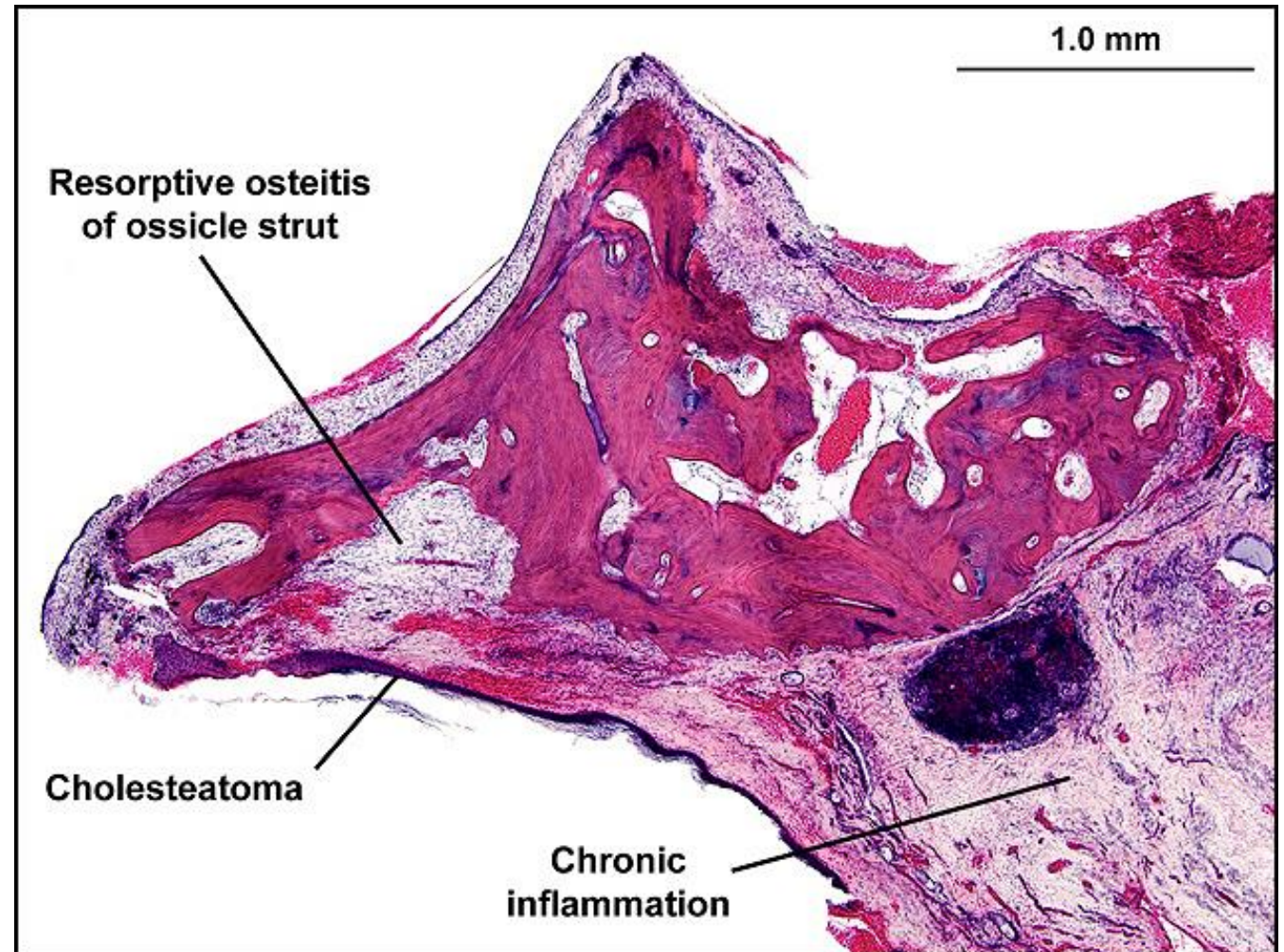
Incus Autograft, 35

Title: Incus Autograft, 35

Chapter: Surgical Pathology

Chapter Section: Surgery for Otitis Media
Ossiculoplasty

Comments: Incus autograft implanted for 8 years.



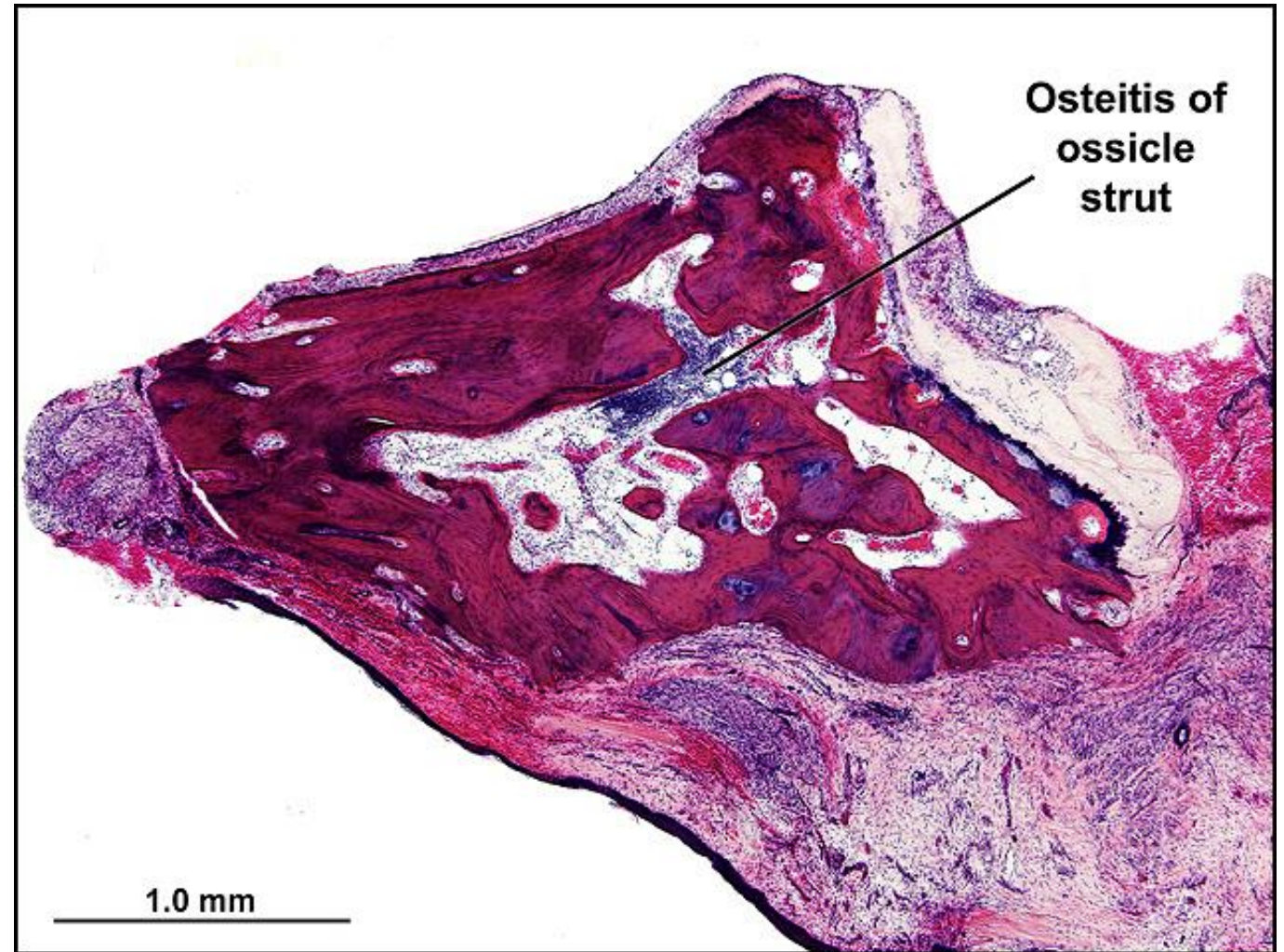
Incus Autograft, 55

Title: Incus Autograft, 55

Chapter: Surgical Pathology

Chapter Section: Surgery for Otitis Media
Ossiculoplasty

Comments: Incus autograft implanted for 8 years.



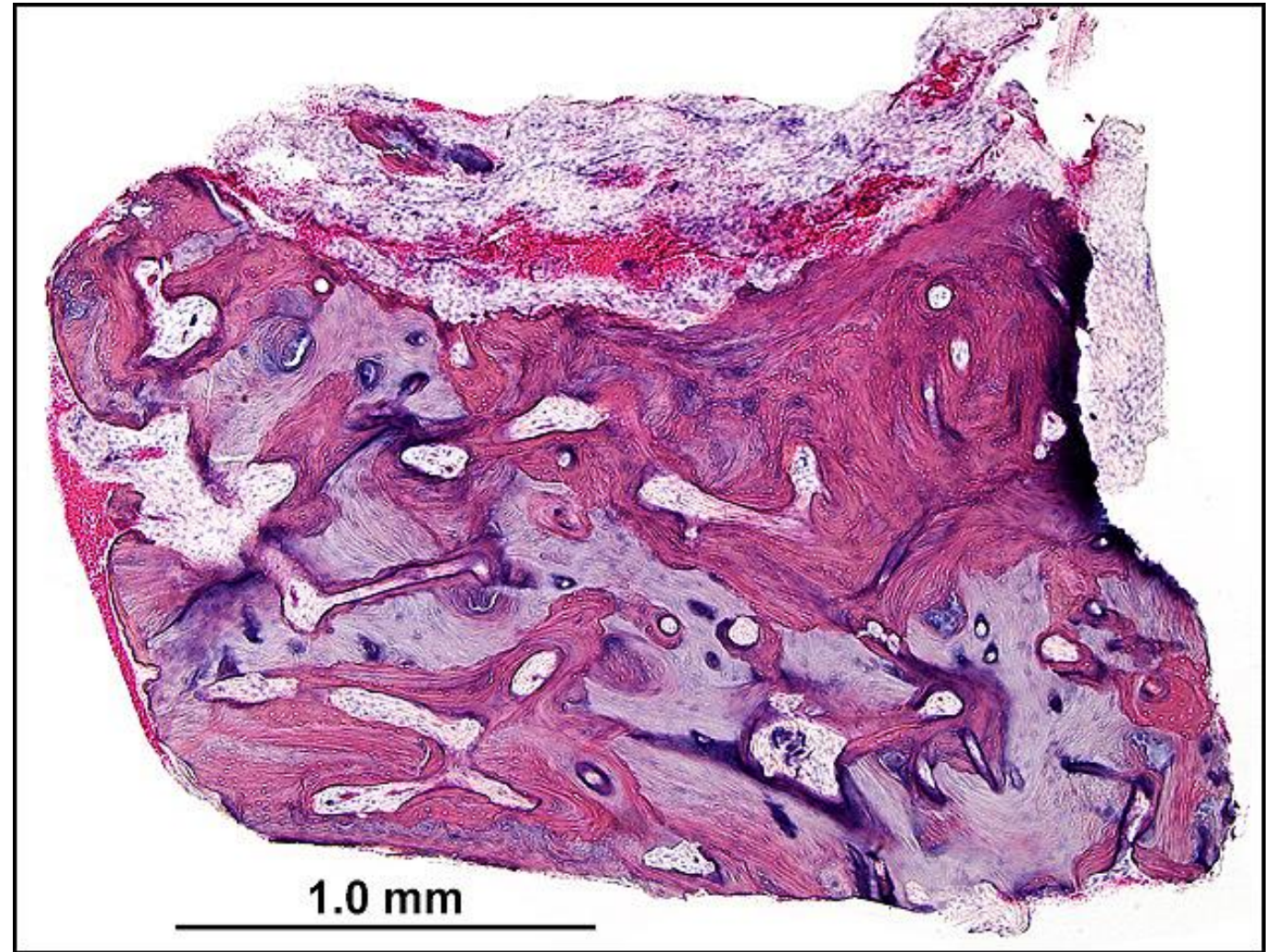
Incus Autograft, 320

Title: Incus Autograft, 320

Chapter: Surgical Pathology

Chapter Section: Surgery for Otitis Media
Ossiculoplasty

Comments: Incus autograft implanted for
20+ years.



Myringoplasty, R-201

Title: Myringoplasty, R-201

Chapter: Surgical Pathology

Chapter Section: Surgery for Otitis Media Myringoplasty

TB Case Number: 1015

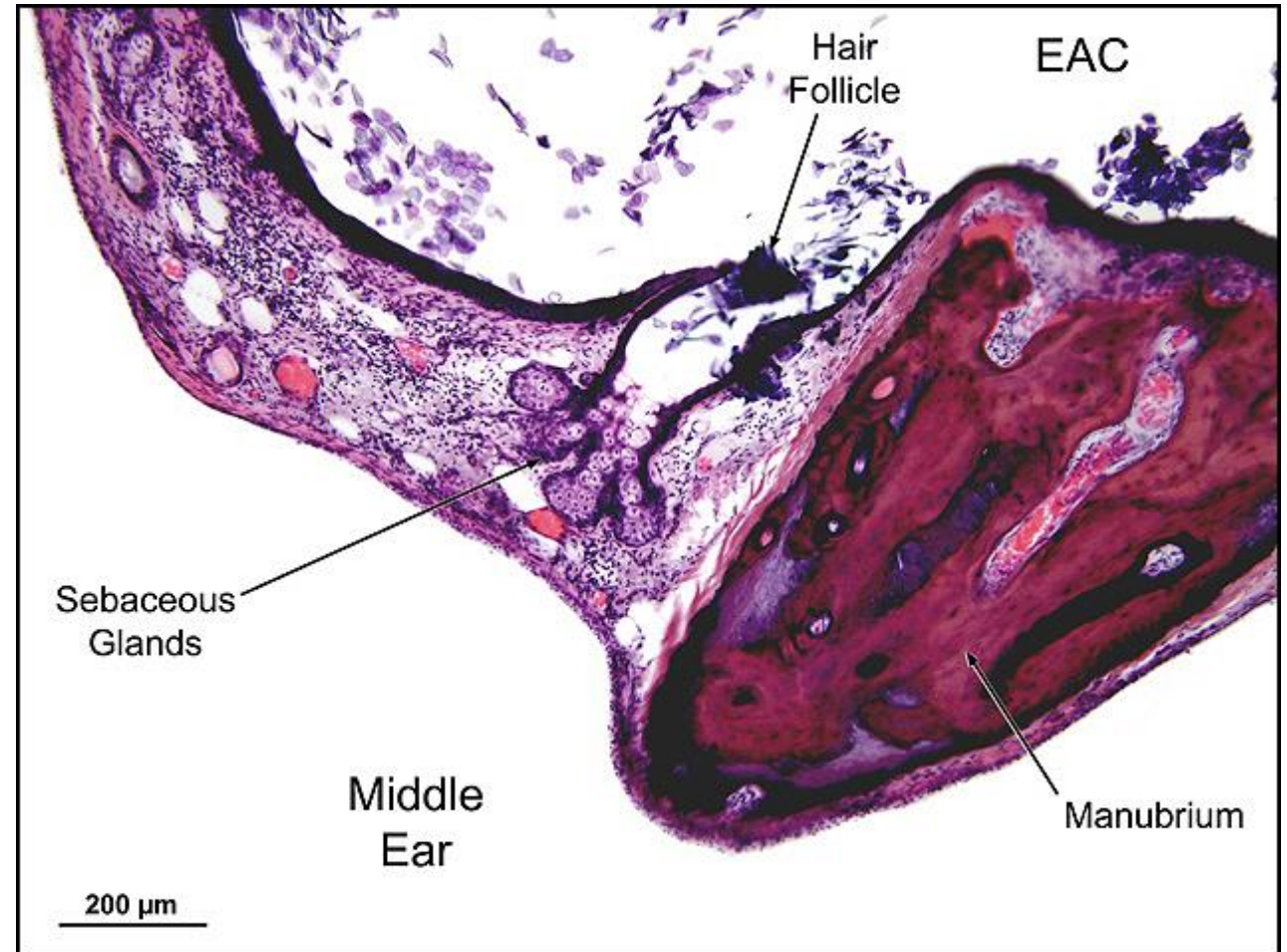
Comments: 91 yr. old F with myringoplasty for a TM perf at ages 51 and 56. Temporalis fascia and post-auricular full thickness skin graft used. Both procedures failed after initial closure of perf.

Gender: Female

Age (yrs.): 92

Otologic Diagnosis:

1. Otosclerosis, S/P mobilization of stapes footplate with polyethylene tube prosthesis, left
2. Chronic otitis media with central perforation and middle ear cholesteatoma, S/P tympanoplasty type III (minor columella, polyethylene strut), right



Myringoplasty, R-201

Title: Myringoplasty, R-201

Chapter: Surgical Pathology

Chapter Section: Surgery for Otitis Media Myringoplasty

TB Case Number: 1015

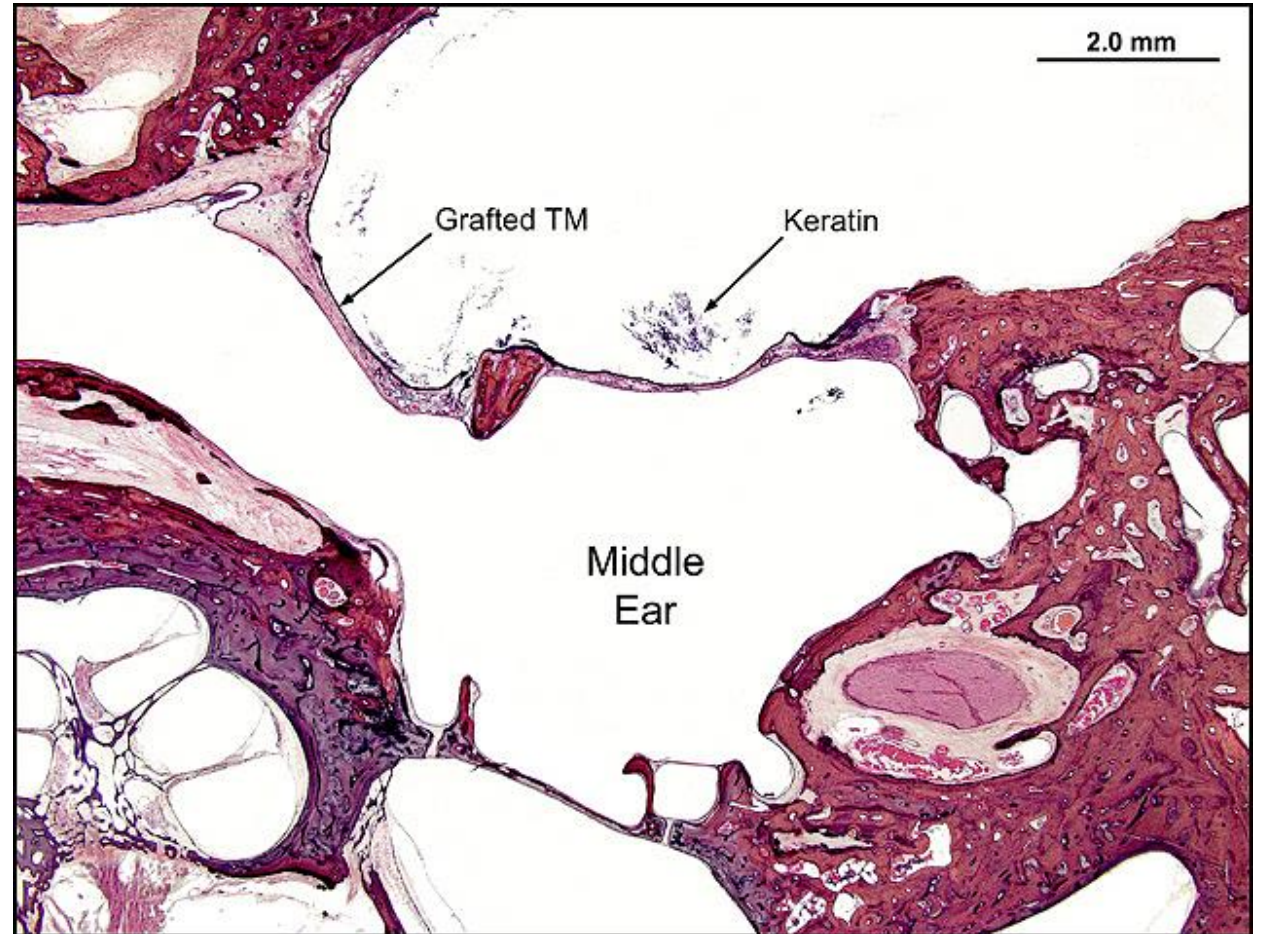
Comments: 91 yr old F with myringoplasty for a TM perf at ages 51 and 56. Temporalis fascia and post-auricular full thickness skin graft used. Both procedures failed after initial closure of perf.

Gender: Female

Age (yrs.): 92

Otologic Diagnosis:

1. Otosclerosis, S/P mobilization of stapes footplate with polyethylene tube prosthesis, left
2. Chronic otitis media with central perforation and middle ear cholesteatoma, S/P tympanoplasty type III (minor columella, polyethylene strut), right



Myringoplasty, R-231

Title: Myringoplasty, R-231

Chapter: Surgical Pathology

Chapter Section: Surgery for Otitis Media Myringoplasty

TB Case Number: 1015

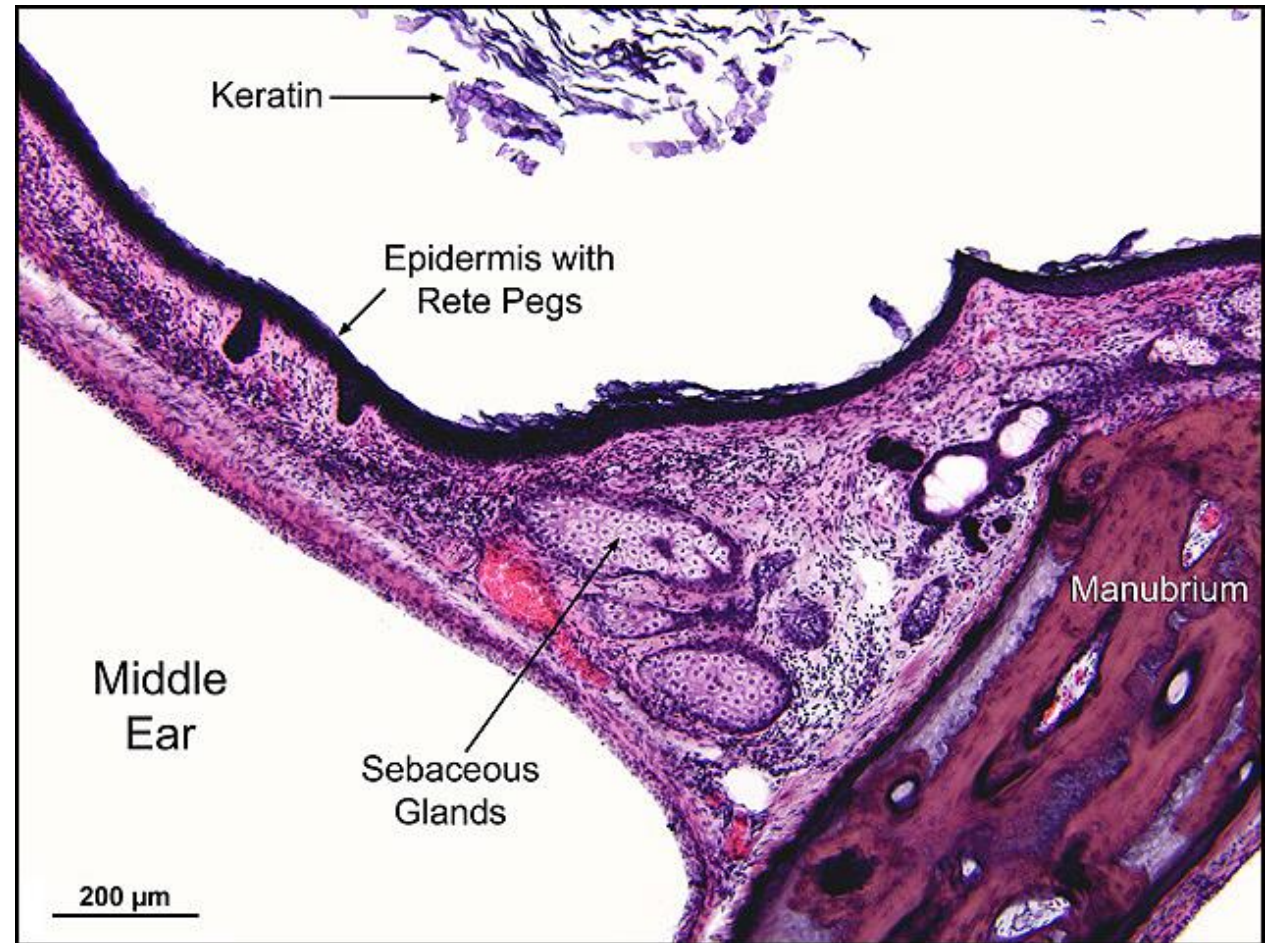
Comments: 91 yr. old F with myringoplasty for a TM perf at ages 51 and 56. Temporalis fascia and post-auricular full thickness skin graft used. Both procedures failed after initial closure of perf.

Gender: Female

Age (yrs.): 92

Otologic Diagnosis:

1. Otosclerosis, S/P mobilization of stapes footplate with polyethylene tube prosthesis, left
2. Chronic otitis media with central perforation and middle ear cholesteatoma, S/P tympanoplasty type III (minor columella, polyethylene strut), right



Myringoplasty, R-231

Title: Myringoplasty, R-231

Chapter: Surgical Pathology

Chapter Section: Surgery for Otitis Media Myringoplasty

TB Case Number: 1015

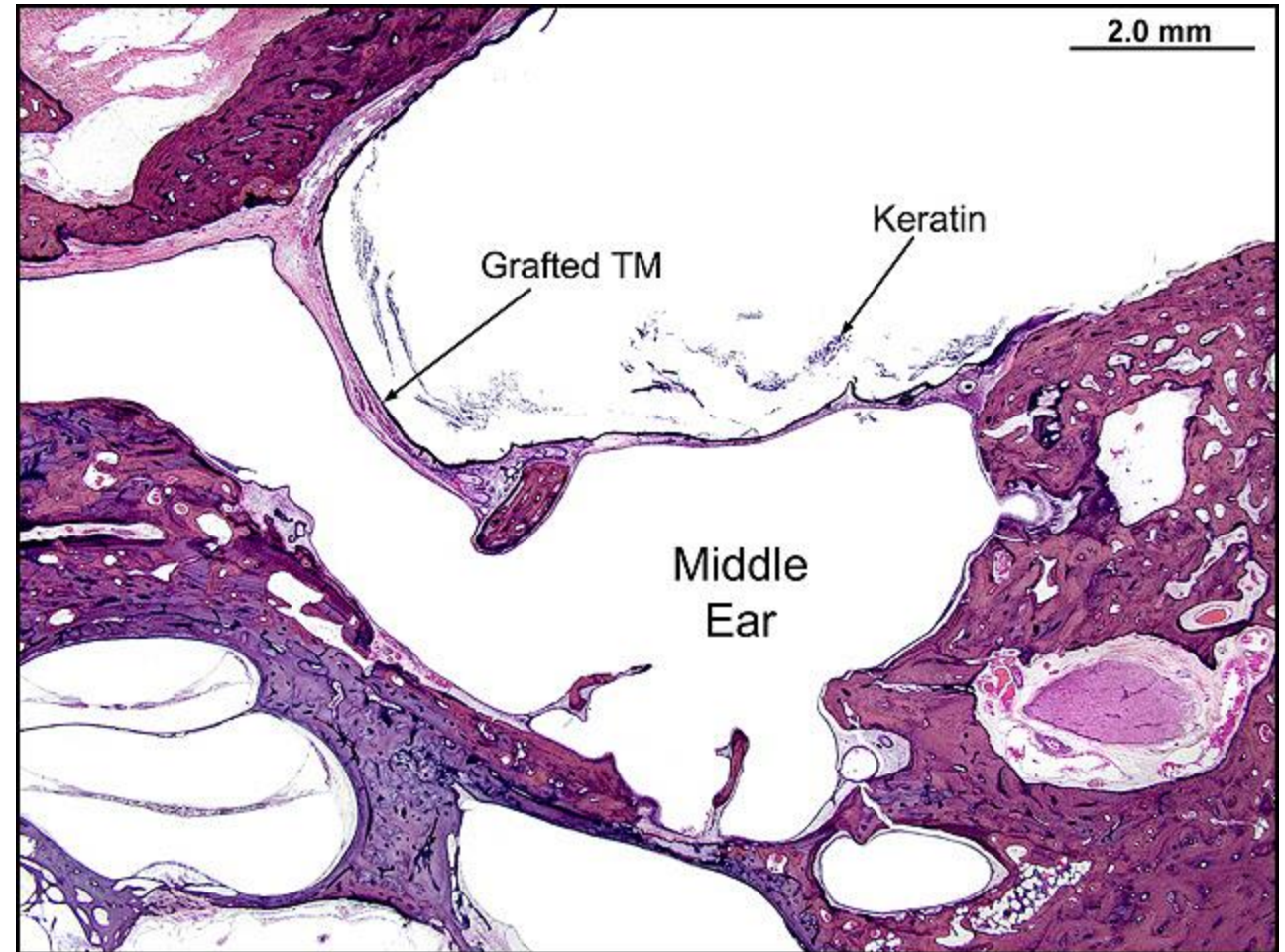
Comments: 91 yr. old F with myringoplasty for a TM perf at ages 51 and 56. Temporalis fascia and post-auricular full thickness skin graft used. Both procedures failed after initial closure of perf.

Gender: Female

Age (yrs.): 92

Otologic Diagnosis:

1. Otosclerosis, S/P mobilization of stapes footplate with polyethylene tube prosthesis, left
2. Chronic otitis media with central perforation and middle ear cholesteatoma, S/P tympanoplasty type III (minor columella, polyethylene strut), right



Myringoplasty, R-331

Title: Myringoplasty, R-331

Chapter: Surgical Pathology

Chapter Section: Surgery for Otitis Media Myringoplasty

TB Case Number: 1015

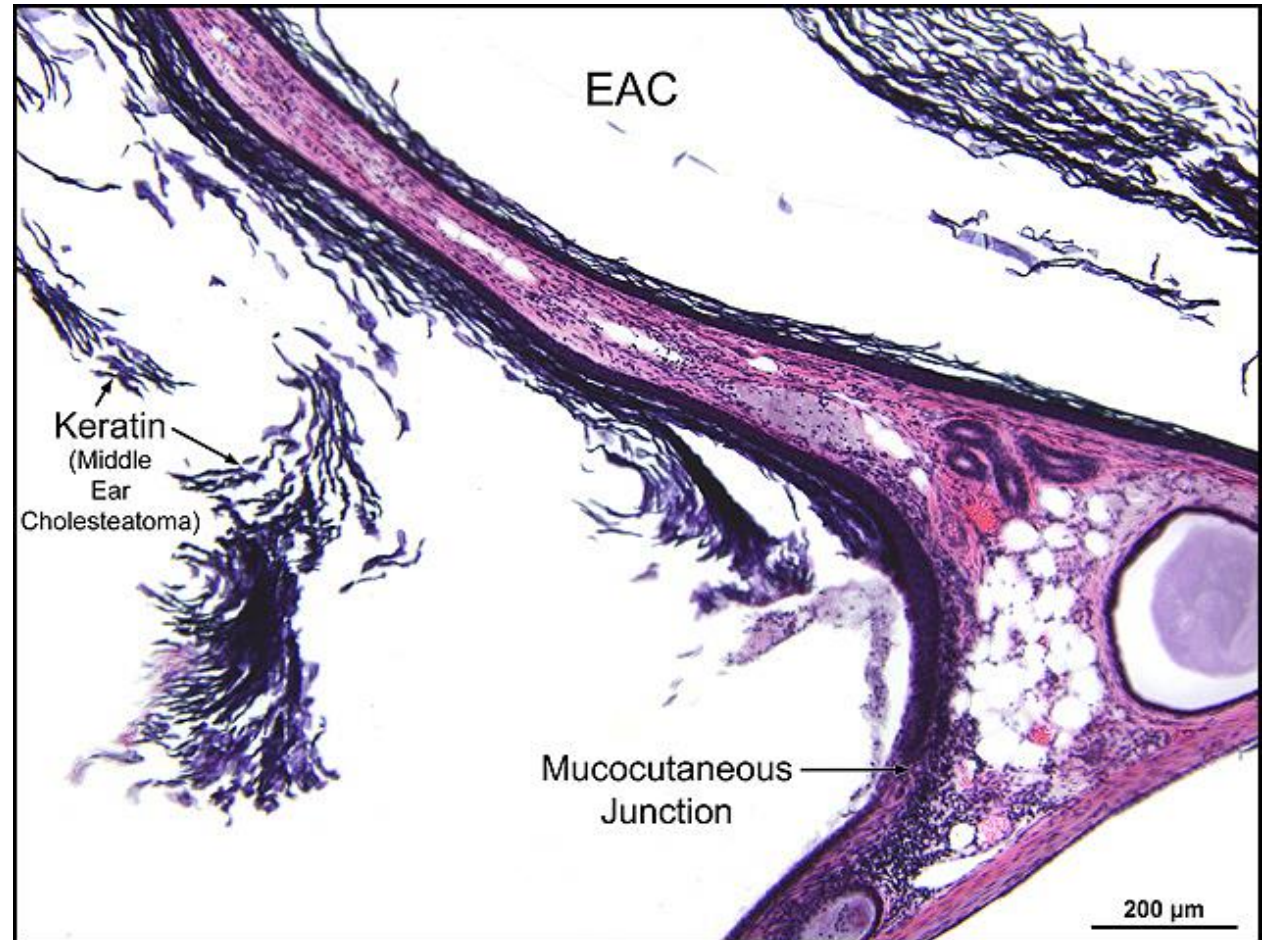
Comments: 91 yr. old F with myringoplasty for a TM perf at ages 51 and 56. Temporalis fascia and post-auricular full thickness skin graft used. Both procedures failed after initial closure of perf.

Gender: Female

Age (yrs.): 92

Otologic Diagnosis:

1. Otosclerosis, S/P mobilization of stapes footplate with polyethylene tube prosthesis, left
2. Chronic otitis media with central perforation and middle ear cholesteatoma, S/P tympanoplasty type III (minor columella, polyethylene strut), right



Myringoplasty, R-331

Title: Myringoplasty, R-331

Chapter: Surgical Pathology

Chapter Section: Surgery for Otitis Media Myringoplasty

TB Case Number: 1015

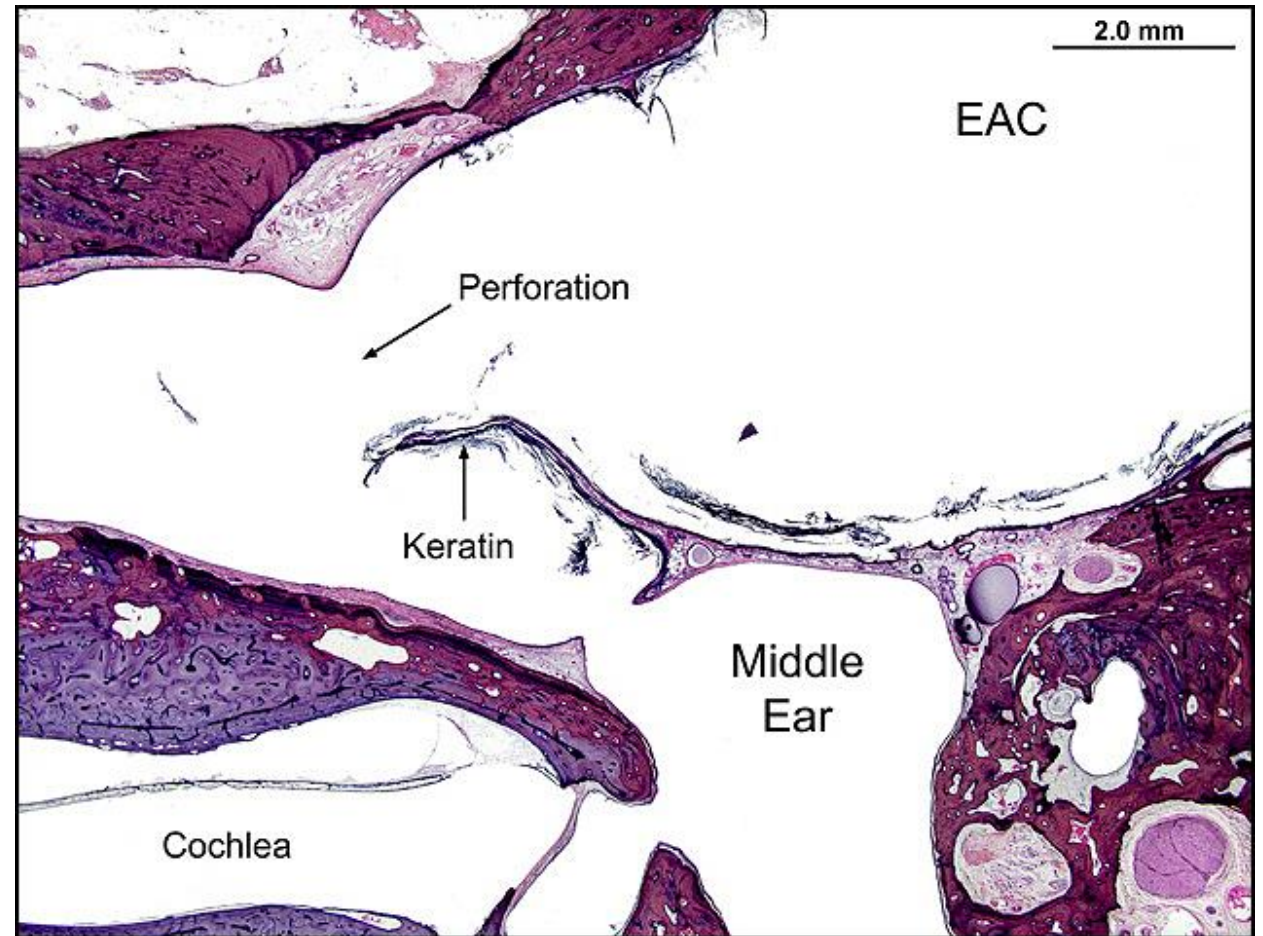
Comments: 91 yr. old F with myringoplasty for a TM perf at ages 51 and 56. Temporalis fascia and post-auricular full thickness skin graft used. Both procedures failed after initial closure of perf.

Gender: Female

Age (yrs.): 92

Otologic Diagnosis:

1. Otosclerosis, S/P mobilization of stapes footplate with polyethylene tube prosthesis, left
2. Chronic otitis media with central perforation and middle ear cholesteatoma, S/P tympanoplasty type III (minor columella, polyethylene strut), right



Myringoplasty, R-331

Title: Myringoplasty, R-331

Chapter: Surgical Pathology

Chapter Section: Surgery for Otitis Media Myringoplasty

TB Case Number: 1015

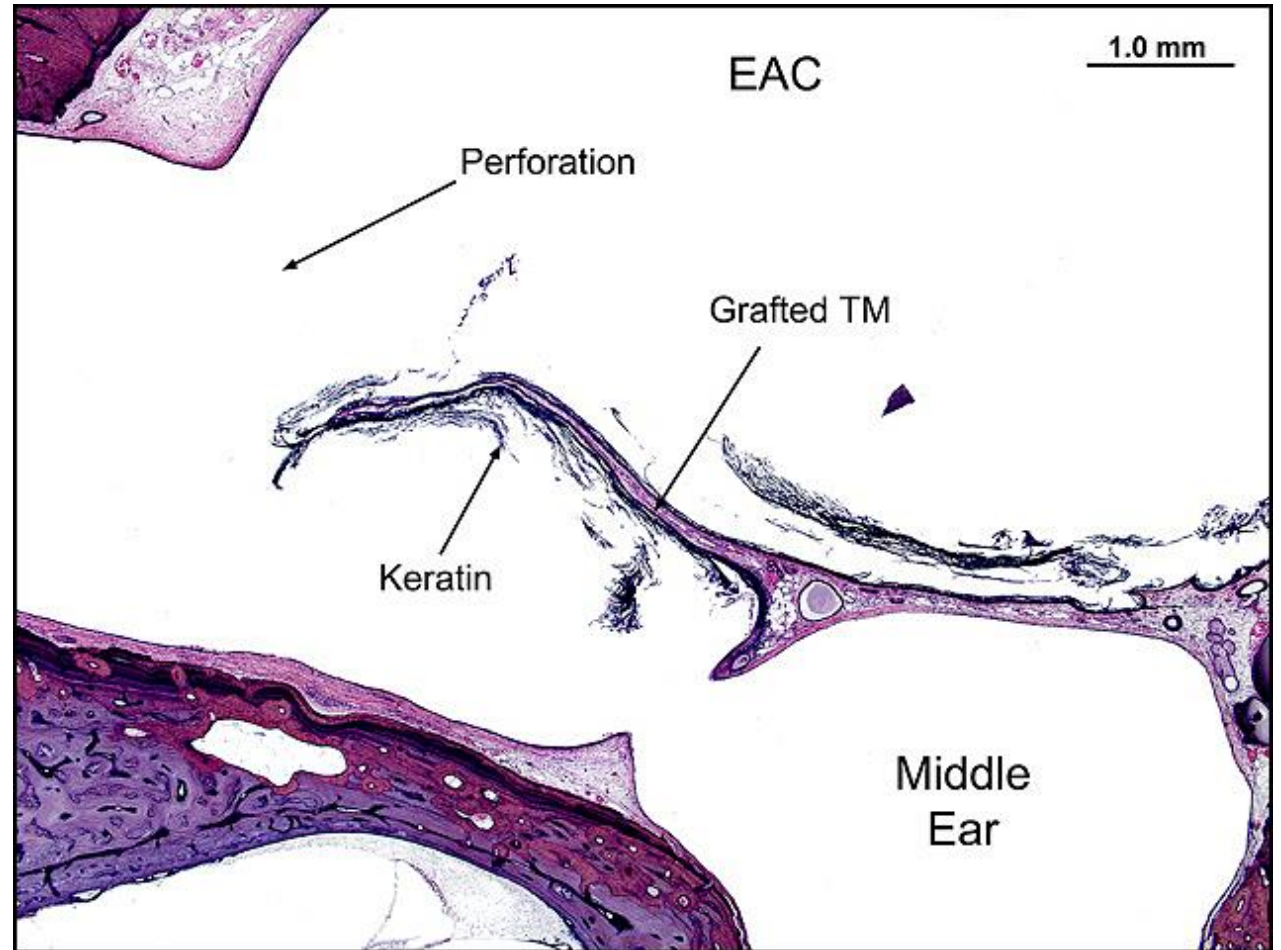
Comments: 91 yr. old F with myringoplasty for a TM perf at ages 51 and 56. Temporalis fascia and post-auricular full thickness skin graft used. Both procedures failed after initial closure of perf.

Gender: Female

Age (yrs.): 92

Otologic Diagnosis:

1. Otosclerosis, S/P mobilization of stapes footplate with polyethylene tube prosthesis, left
2. Chronic otitis media with central perforation and middle ear cholesteatoma, S/P tympanoplasty type III (minor columella, polyethylene strut), right



TM S/P Myringoplasty, L-191.1

Title: TM S/P Myringoplasty, L-191.1

Chapter: Surgical Pathology

Chapter Section: Surgery for Otitis Media
Myringoplasty

TB Case Number: 1005

Comments: 92-year-old female with inactive, healed
COM

Gender: Female

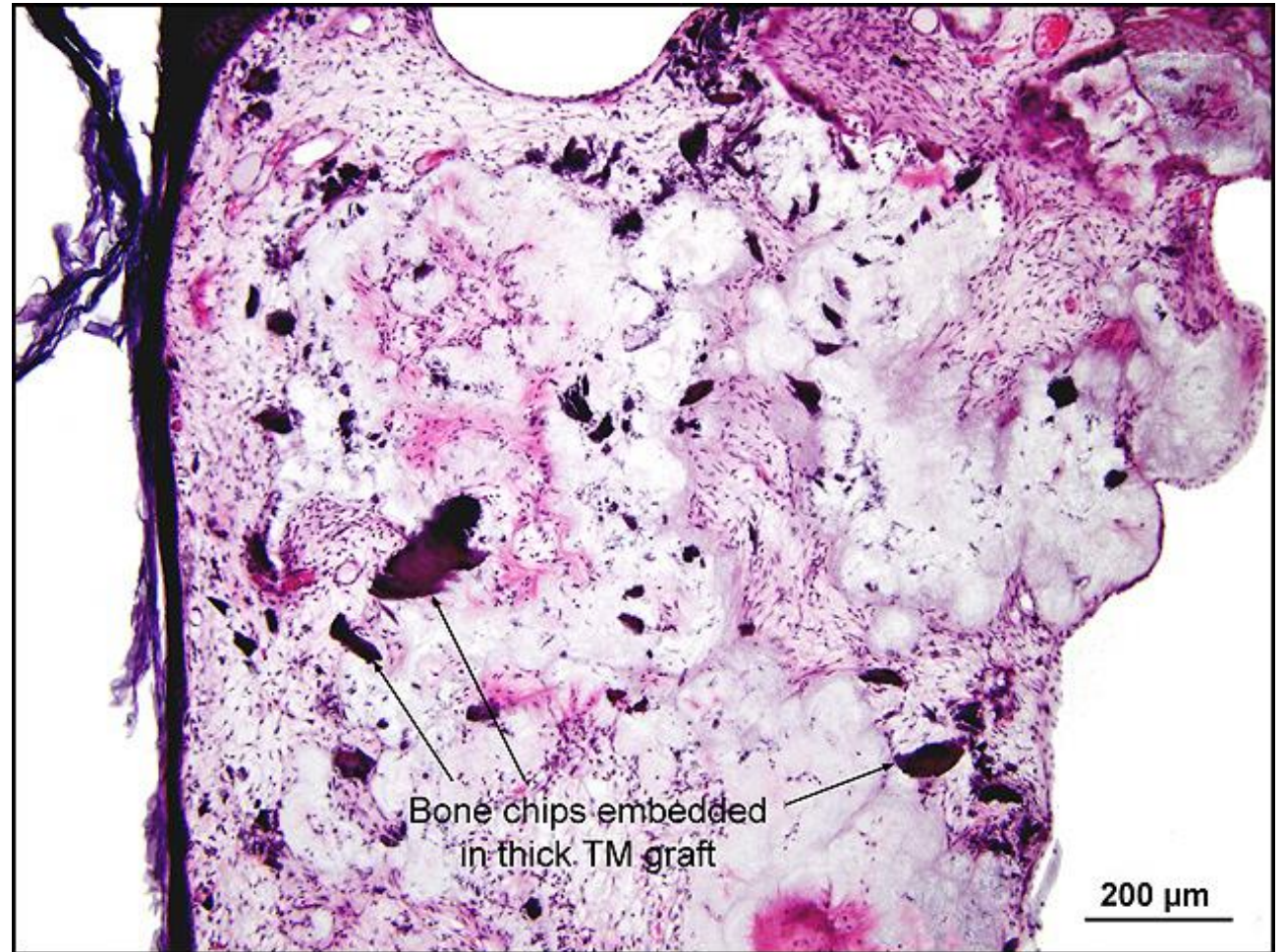
Age (yrs.): 92

Otologic Diagnosis:

Mixed hearing loss, AU, predominantly sensorineural,
due to presbycusis

Otopathologic Diagnoses:

1. Chronic otitis media without cholesteatoma,
inactive and healed, bilateral
2. Retraction pocket of tympanic membrane, bilateral



TM S/P Myringoplasty, R-231.2

Title: TM S/P Myringoplasty, R-231.2

Chapter: Surgical Pathology

Chapter Section: Surgery for Otitis Media
Myringoplasty

TB Case Number: 1005

Comments: 92-year-old female with inactive, healed
COM

Gender: Female

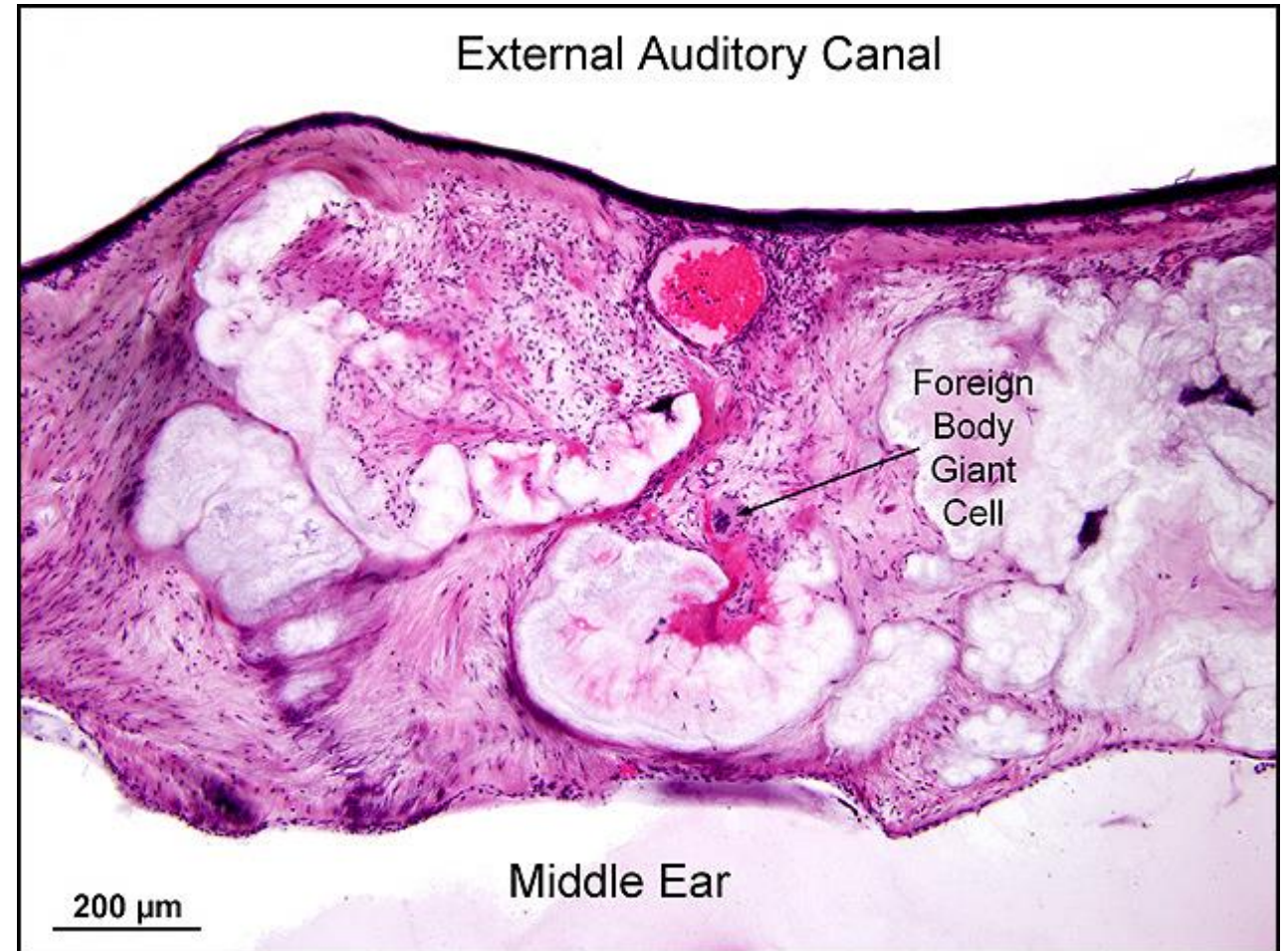
Age (yrs.): 92

Otologic Diagnosis:

Mixed hearing loss, AU, predominantly sensorineural,
due to presbycusis

Otopathologic Diagnoses:

1. Chronic otitis media without cholesteatoma,
inactive and healed, bilateral
2. Retraction pocket of tympanic membrane, bilateral



TM S/P Myringoplasty, R-231.1

Title: TM S/P Myringoplasty, R-231-1

Chapter: Surgical Pathology

Chapter Section: Surgery for Otitis Media Myringoplasty

TB Case Number: 1005

Comments: 92-year-old female with inactive, healed COM

Gender: Female

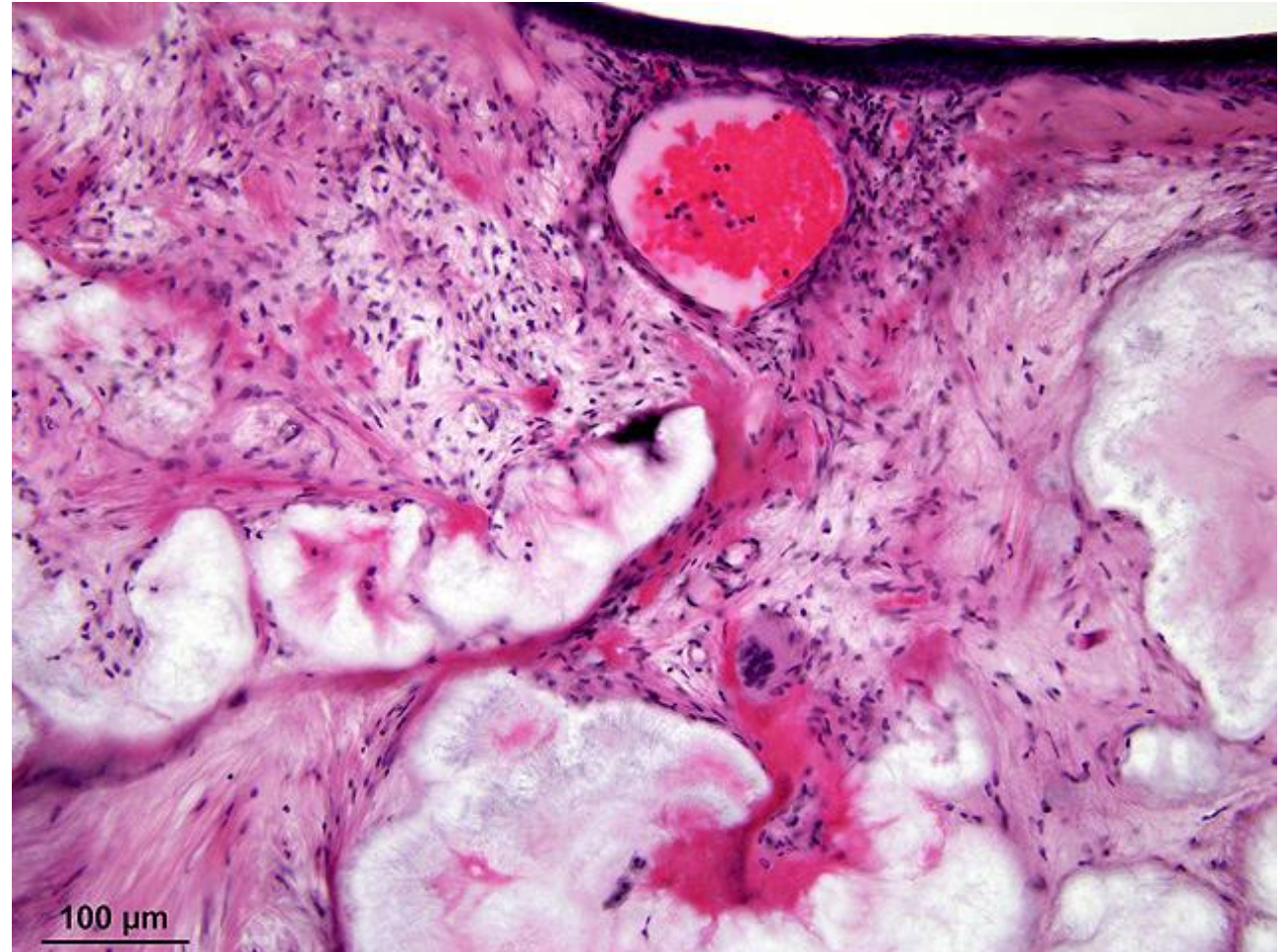
Age (yrs.): 92

Otologic Diagnosis:

Mixed hearing loss, AU, predominantly sensorineural, due to presbycusis

Otopathologic Diagnoses:

1. Chronic otitis media without cholesteatoma, inactive and healed, bilateral
2. Retraction pocket of tympanic membrane, bilateral



Cochlear Implant, L-161

Title: Cochlear Implant, L-161

Chapter: Surgical Pathology

Chapter Section: Surgery for Cochlear Implants

TB Case Number: 927

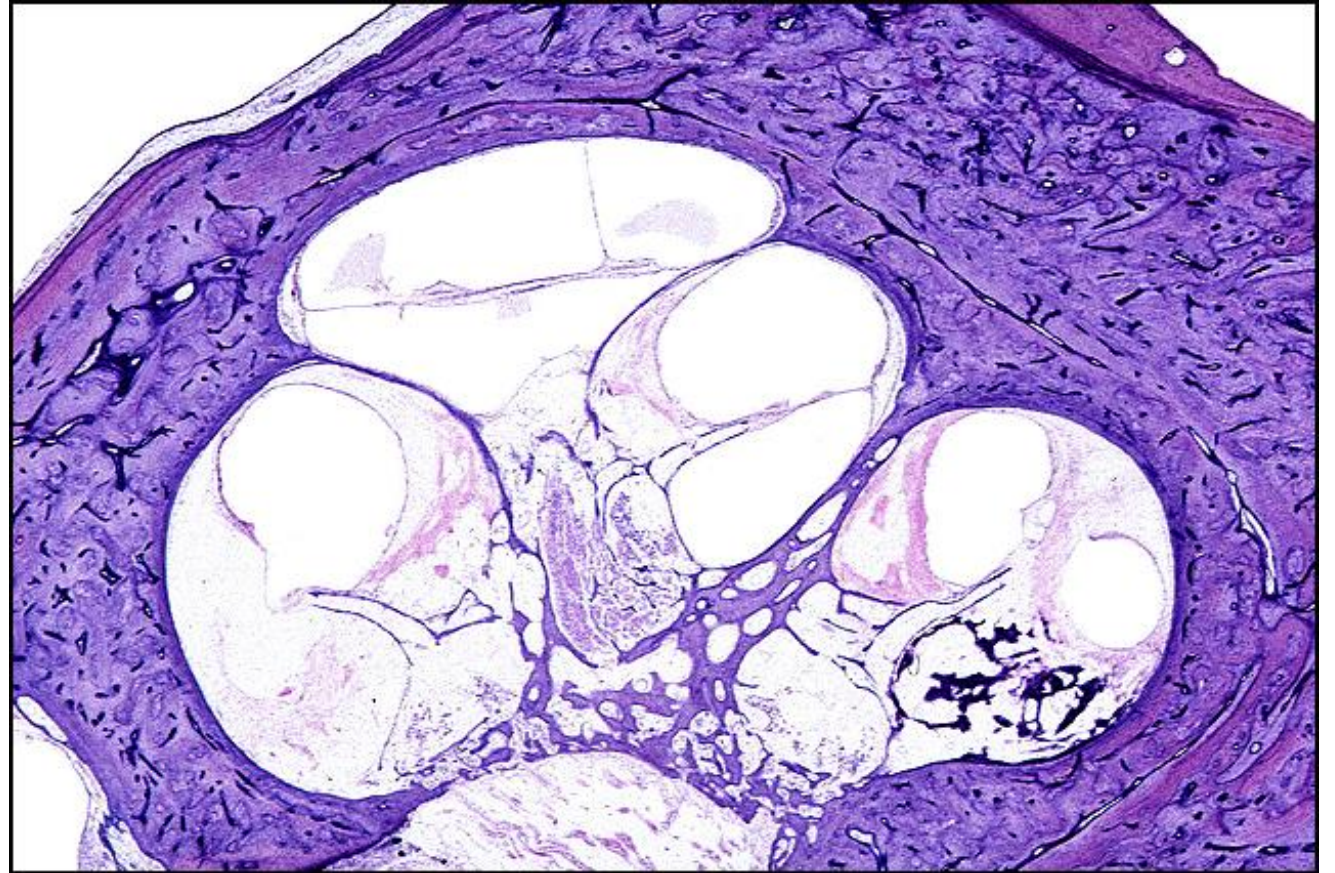
Comments: cochlear implant

Gender: Male

Age (yrs.): 68

Otologic Diagnosis:

1. Profound deafness secondary to bilateral temporal bone fractures (presumed in AS)
2. Traumatic neuroma of superior vestibular nerve (vestibule), AD
3. Traumatic degeneration of superior and inferior vestibular nerves, AD
4. Osteoid and new bone formation



Fenestration, R-202

Title: Fenestration, R-202

Chapter: Surgical Pathology

Chapter Section: Fenestration, Surgery for Otosclerosis

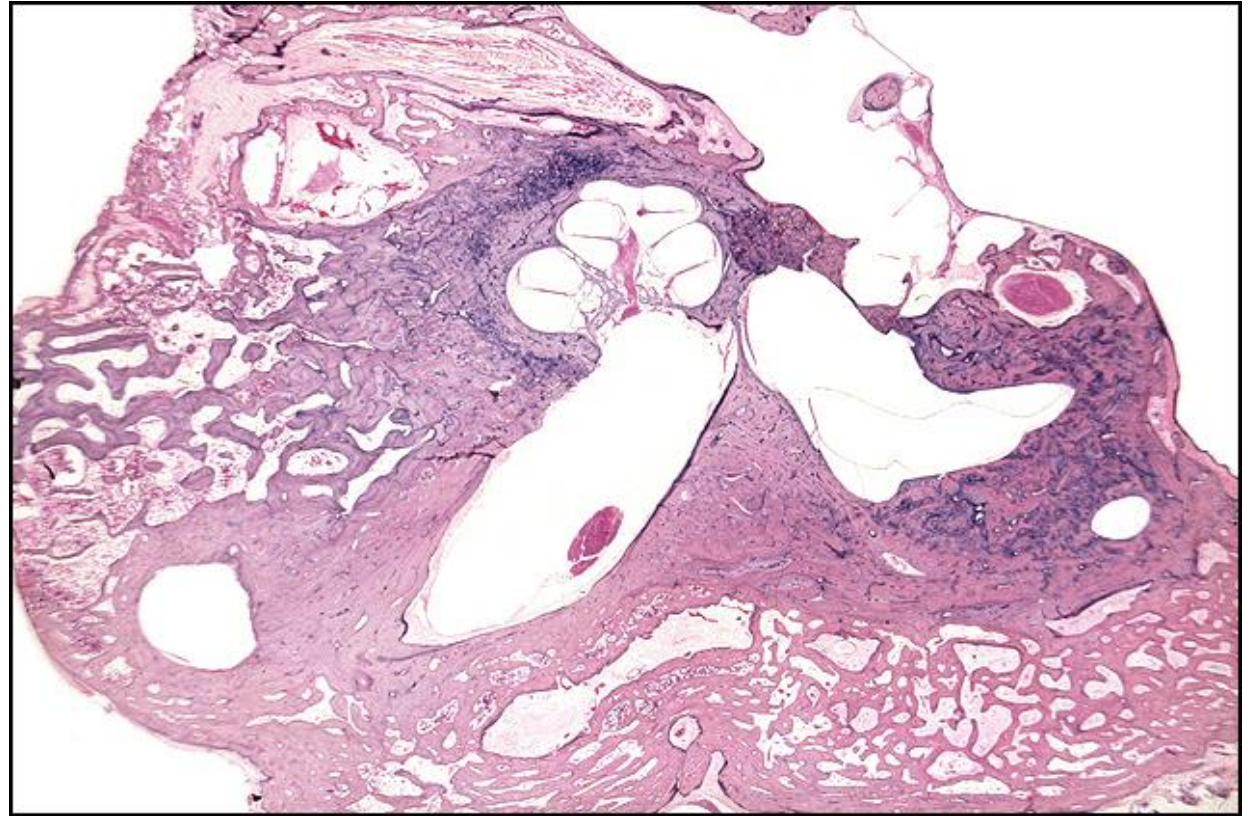
TB Case Number: 49

Gender: Female

Age (yrs.): 49

Otologic Diagnosis:

1. Otosclerosis, round and oval windows, anterior wall of internal auditory canal, bilateral
2. Fenestration operation, lateral canal, right
3. Fenestra, osseous closure, lateral canal, right
4. Semicircular duct, lateral, focally obliterated, right
5. Stapedectomy, wire prosthesis and vein-graft, left
6. Organ of Corti, normal, bilateral
7. Cristae, normal, bilateral
8. Maculae, normal, bilateral
9. Blue mantles, bilateral
10. Artifact, preparation, compression, moderate, bilateral
11. Mastoid bowl, postoperative, fenestration operation, healed, right



Fenestration, R-202

Title: Fenestration, R-202

Chapter: Surgical Pathology

Chapter Section: Fenestration, Surgery for Otosclerosis

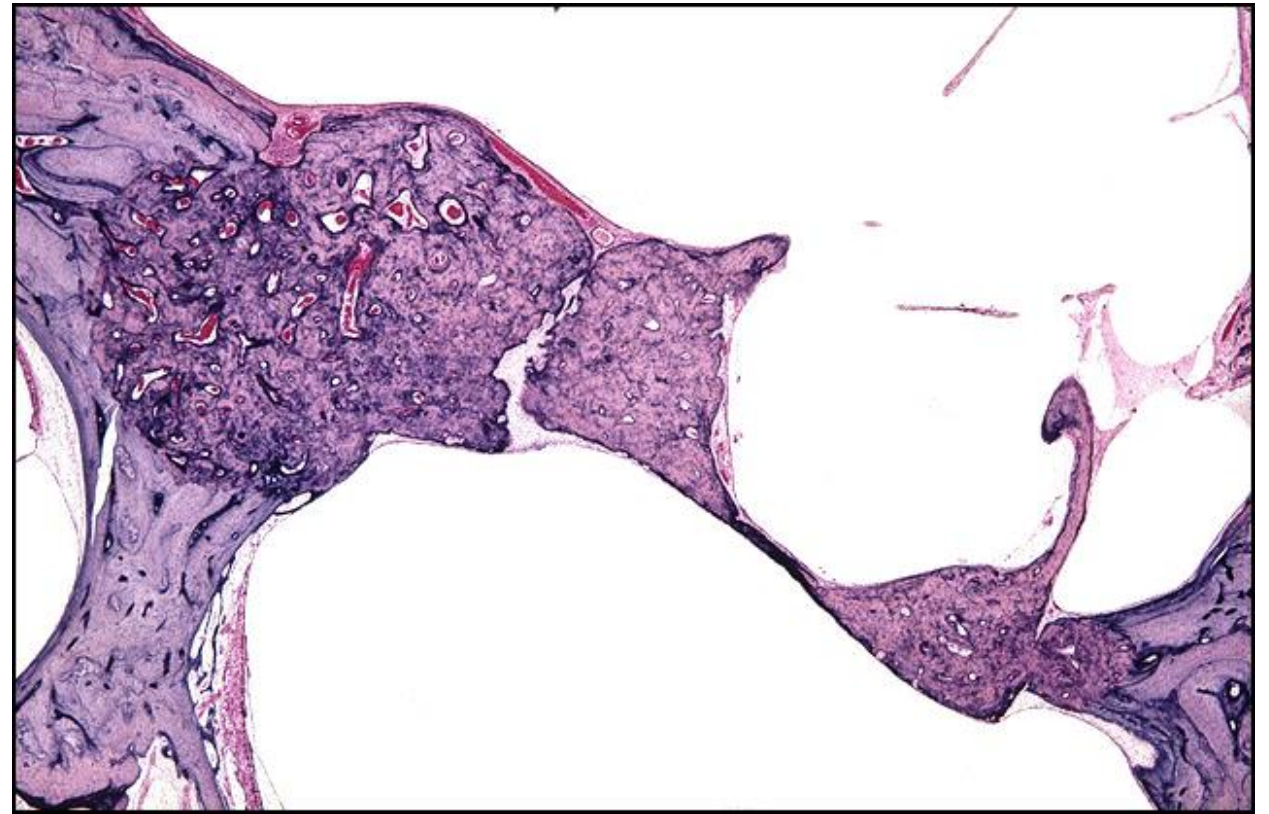
TB Case Number: 49

Gender: Female

Age (yrs.): 49

Otologic Diagnosis:

1. Otosclerosis, round and oval windows, anterior wall of internal auditory canal, bilateral
2. Fenestration operation, lateral canal, right
3. Fenestra, osseous closure, lateral canal, right
4. Semicircular duct, lateral, focally obliterated, right
5. Stapedectomy, wire prosthesis and vein-graft, left
6. Organ of Corti, normal, bilateral
7. Cristae, normal, bilateral
8. Maculae, normal, bilateral
9. Blue mantles, bilateral
10. Artifact, preparation, compression, moderate, bilateral
11. Mastoid bowl, postoperative, fenestration operation, healed, right



Fenestration, L-241

Title: Fenestration, L-241

Chapter: Surgical Pathology

Chapter Section: Fenestration, Surgery for Otosclerosis

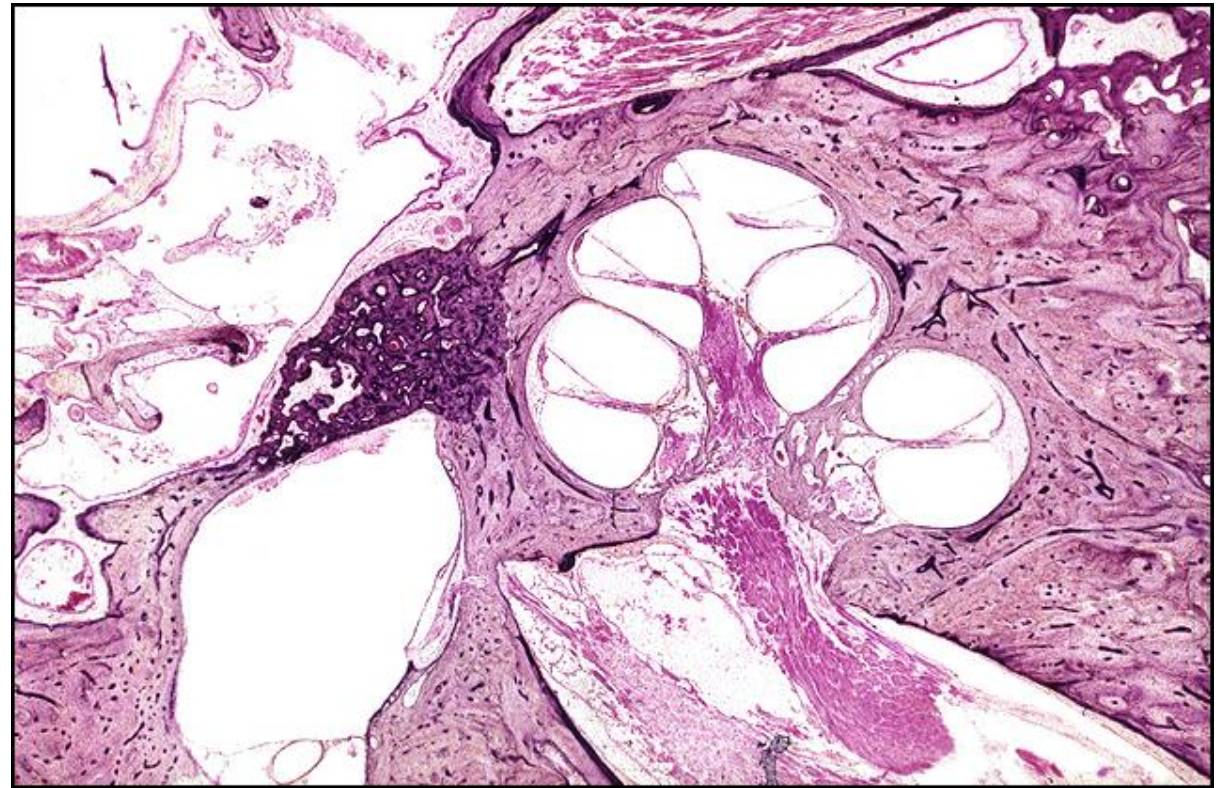
TB Case Number: 56

Gender: Male

Age (yrs.): 63

Otologic Diagnosis:

1. Otosclerosis, clinical, with stapes fixation, bilateral
2. Fenestration operation, lateral canal, left
3. Mastoidectomy, radical, associated with fenestrations, left
4. Mastoid bowl, postoperative, granulating, left
5. Stapedotomy operation, stainless steel prosthesis, right
6. Stapes, fractured, during stapedotomy, right
7. Hemorrhage, subarachnoid space, internal auditory canal, right



Fenestration, L-401

Title: Fenestration, L-401

Chapter: Surgical Pathology

Chapter Section: Fenestration, Surgery for Otosclerosis

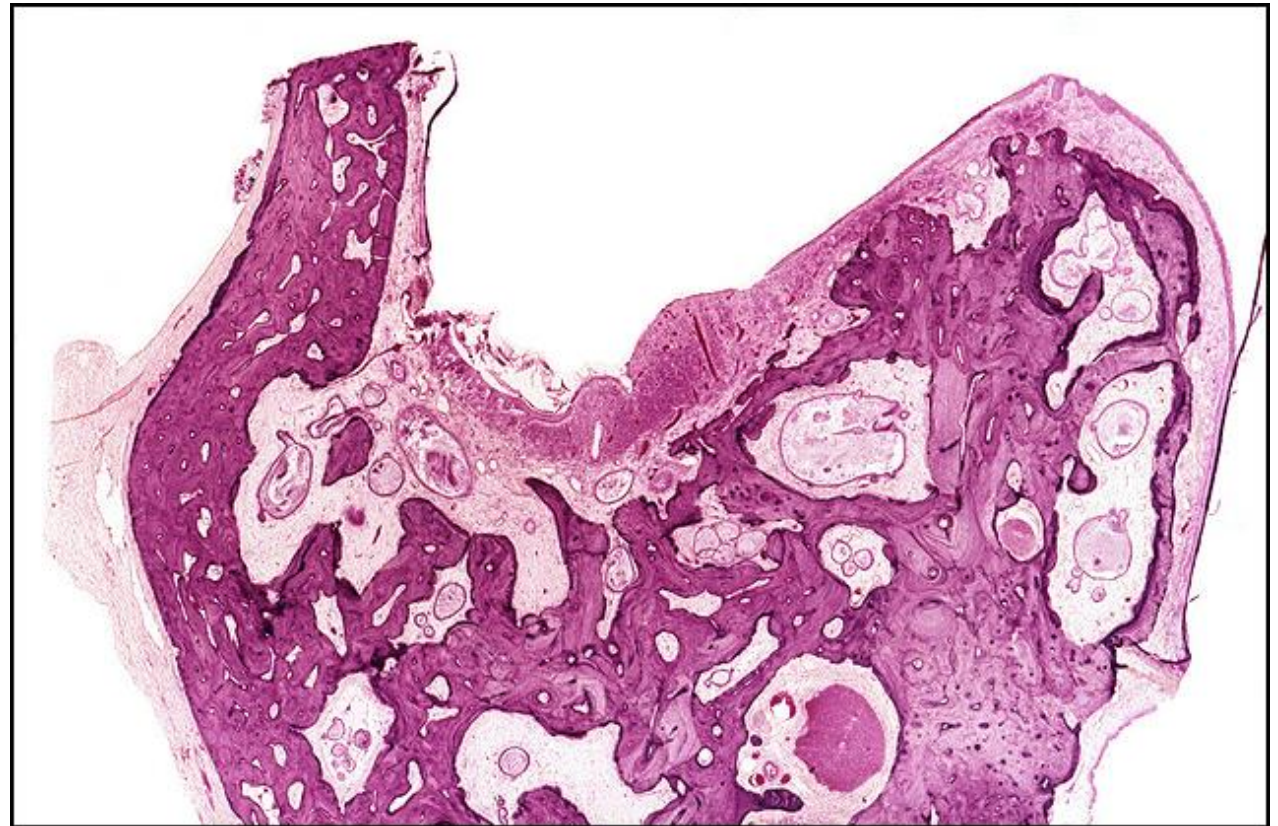TB Case Number: 56

Gender: Male

Age (yrs.): 63

Otologic Diagnosis:

1. Otosclerosis, clinical, with stapes fixation, bilateral
2. Fenestration operation, lateral canal, left
3. Mastoidectomy, radical, associated with fenestrations, left
4. Mastoid bowl, postoperative, granulating, left
5. Stapedotomy operation, stainless steel prosthesis, right
6. Stapes, fractured, during stapedotomy, right
7. Hemorrhage, subarachnoid space, internal auditory canal, right



Fenestration

Title: Fenestration

Chapter: Surgical Pathology

Chapter Section: Fenestration, Surgery for Otosclerosis

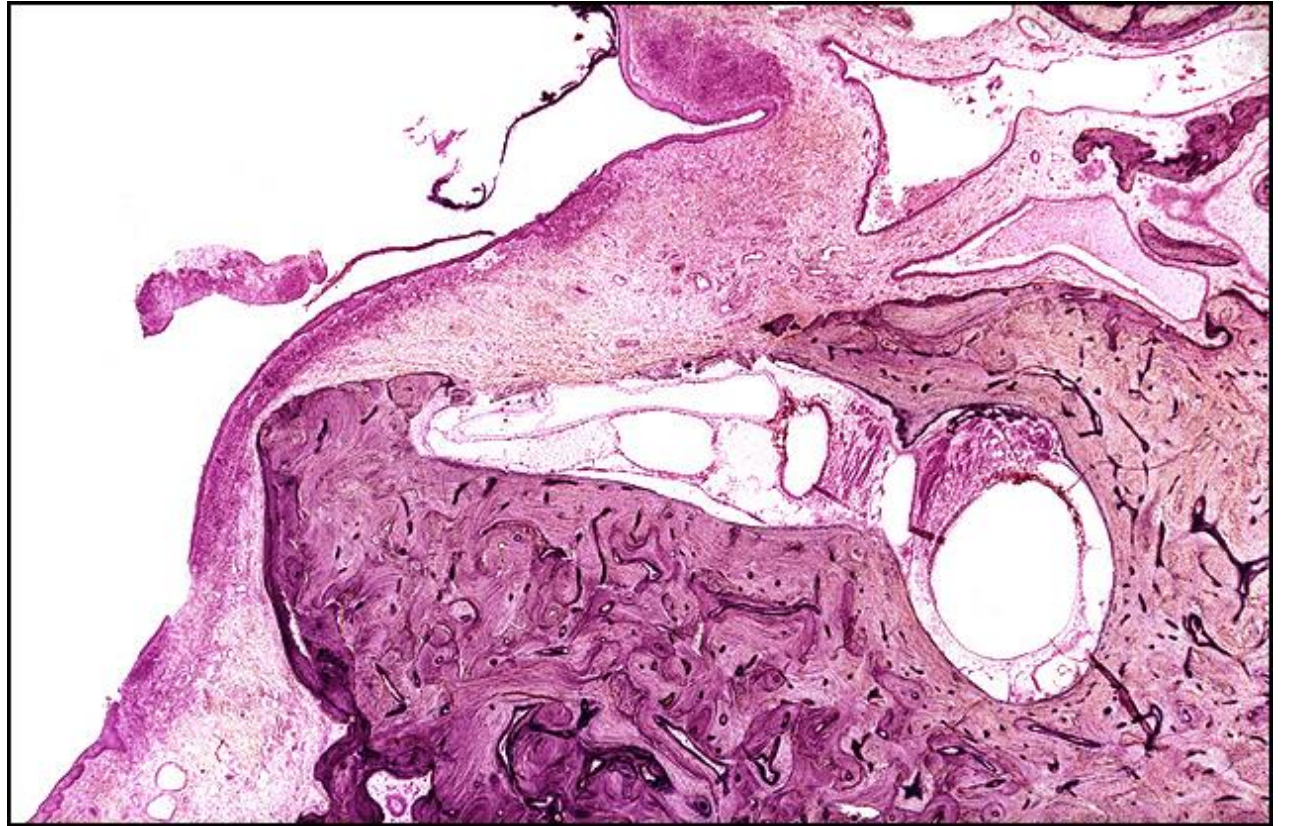
TB Case Number: 56

Gender: Male

Age (yrs.): 63

Otologic Diagnosis:

1. Otosclerosis, clinical, with stapes fixation, bilateral
2. Fenestration operation, lateral canal, left
3. Mastoidectomy, radical, associated with fenestrations, left
4. Mastoid bowl, postoperative, granulating, left
5. Stapedotomy operation, stainless steel prosthesis, right
6. Stapes, fractured, during stapedotomy, right
7. Hemorrhage, subarachnoid space, internal auditory canal, right



Fenestration, R-335

Title: R-335 Fenestration

Chapter: Surgical Pathology

Chapter Section: Fenestration, Surgery for Otosclerosis

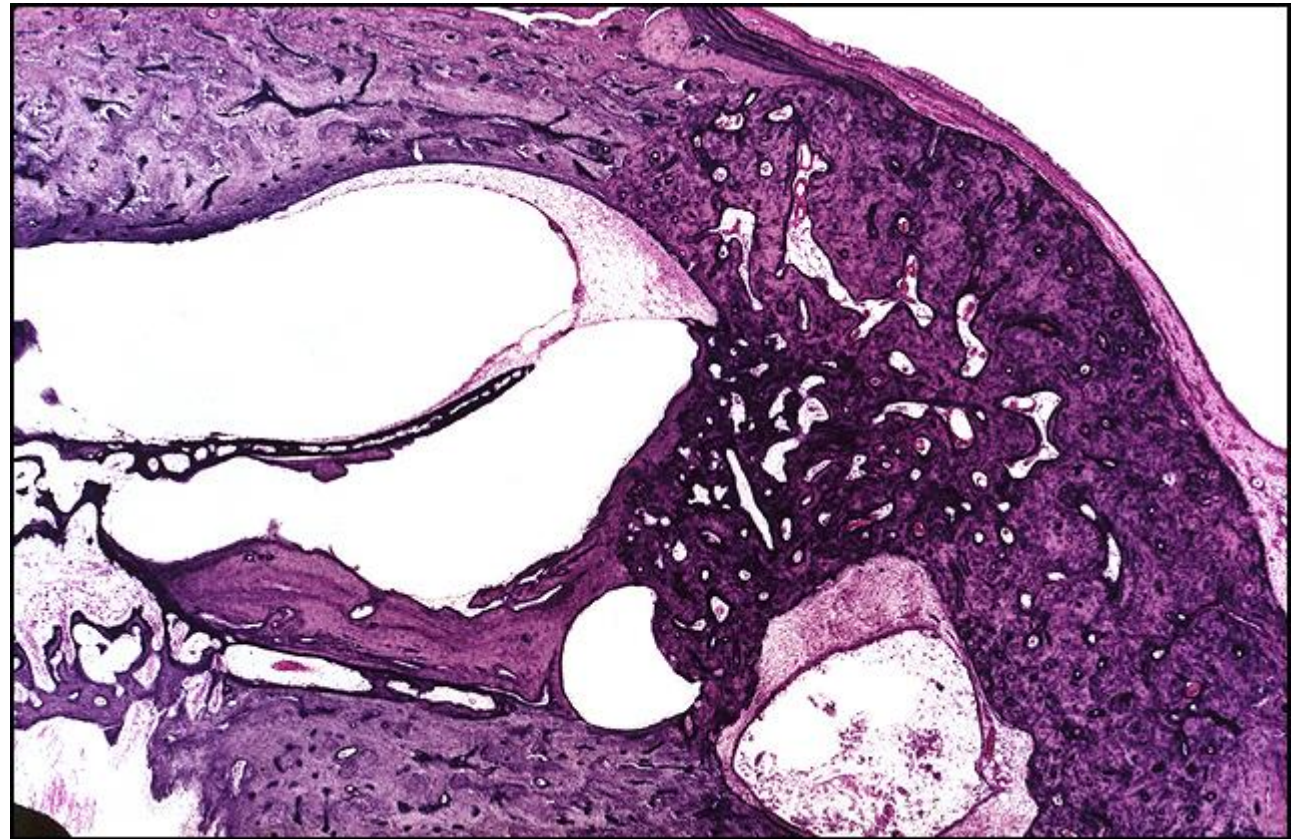
TB Case Number: 70

Gender: Female

Age (yrs.): 64

Otologic Diagnosis:

1. Otosclerosis, severe, bilateral
2. Fenestration, lateral canal, bilateral
3. Semicircular canal, surgical trauma, fenestration, fibrous obliteration, bilateral
4. Mastoid bowl, postoperative, fenestration surgery, healed, bilateral
5. Stapes, fixation, otosclerosis, bilateral
6. Incus, removed, fenestration, bilateral
7. Malleus, capitulum, amputated, bilateral
8. Round window, obliterated, otosclerosis, right



Fenestration, R-27

Title: Fenestration, R-27

Chapter: Surgical Pathology

Chapter Section: Fenestration, Surgery for Otosclerosis

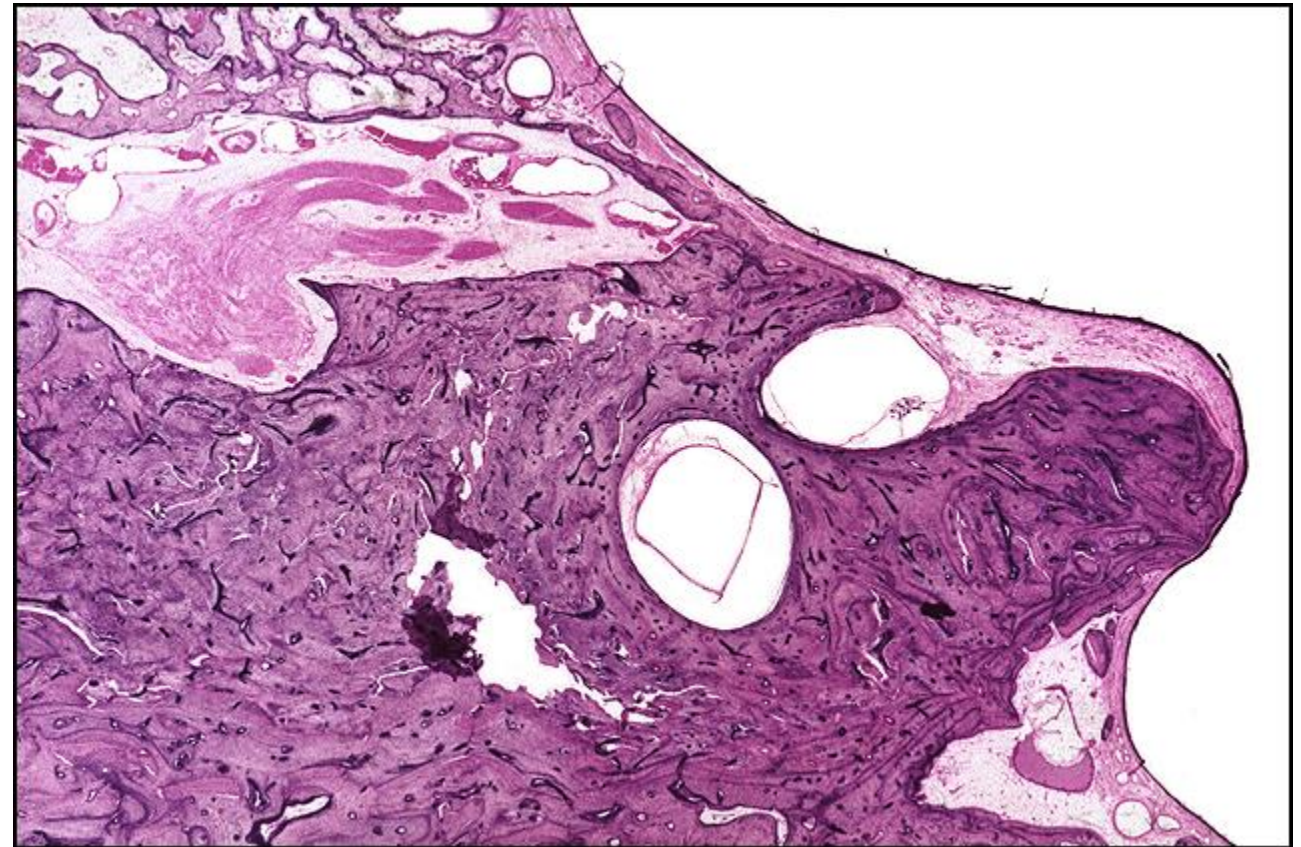
TB Case Number: 70

Gender: Male

Age (yrs.): 64

Otologic Diagnosis:

1. Otosclerosis, severe, bilateral
2. Fenestration, lateral canal, bilateral
3. Semicircular canal, surgical trauma, fenestration, fibrous obliteration, bilateral
4. Mastoid bowl, postoperative, fenestration surgery, healed, bilateral
5. Stapes, fixation, otosclerosis, bilateral
6. Incus, removed, fenestration, bilateral
7. Malleus, capitulum, amputated, bilateral
8. Round window, obliterated, otosclerosis, right



Fenestration, L-171

Title: Fenestration, L-171

Chapter: Surgical Pathology

Chapter Section: Fenestration, Surgery for Otosclerosis

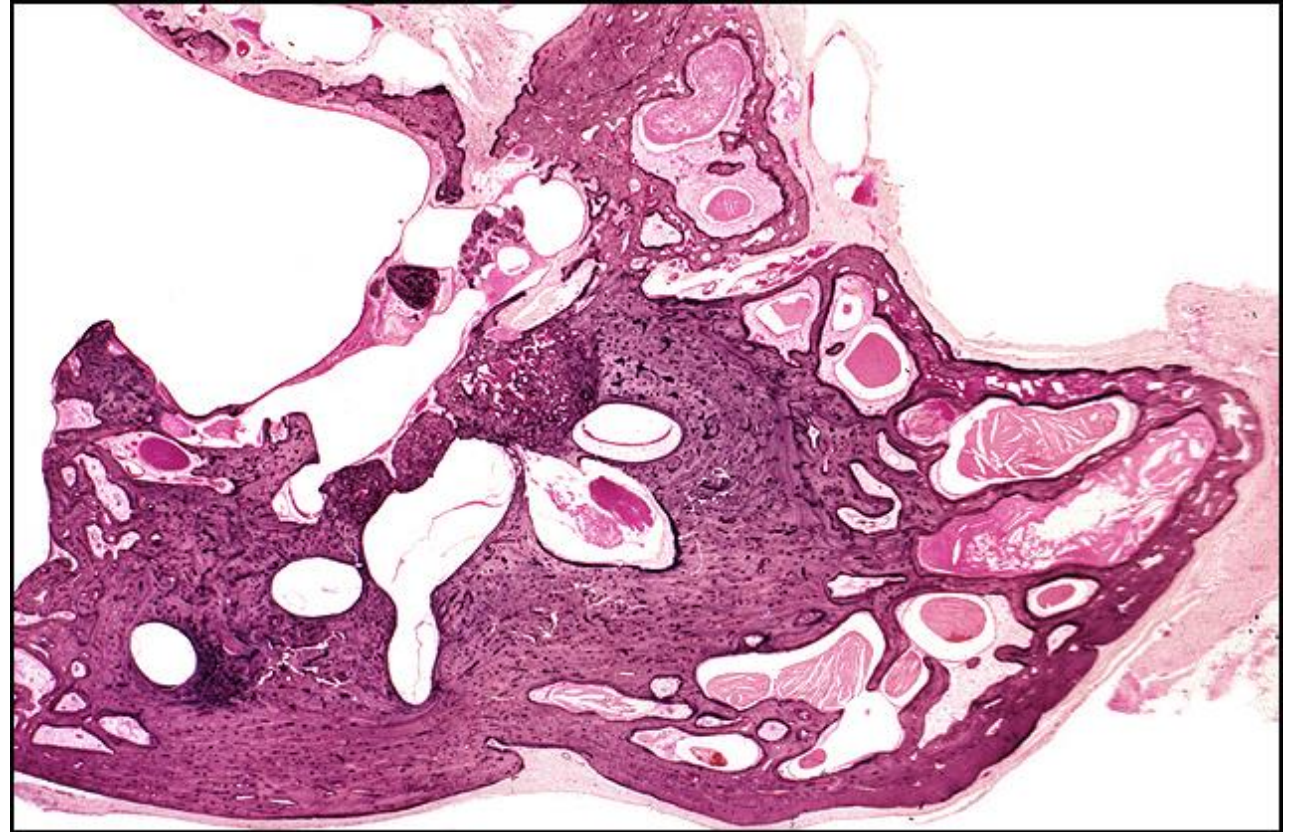
TB Case Number: 70

Gender: Female

Age (yrs.): 64

Otologic Diagnosis:

1. Otosclerosis, severe, bilateral
2. Fenestration, lateral canal, bilateral
3. Semicircular canal, surgical trauma, fenestration, fibrous obliteration, bilateral
4. Mastoid bowl, postoperative, fenestration surgery, healed, bilateral
5. Stapes, fixation, otosclerosis, bilateral
6. Incus, removed, fenestration, bilateral
7. Malleus, capitulum, amputated, bilateral
8. Round window, obliterated, otosclerosis, right



Fenestration

Title: Fenestration

Chapter: Surgical Pathology

Chapter Section: Fenestration, Surgery for Otosclerosis

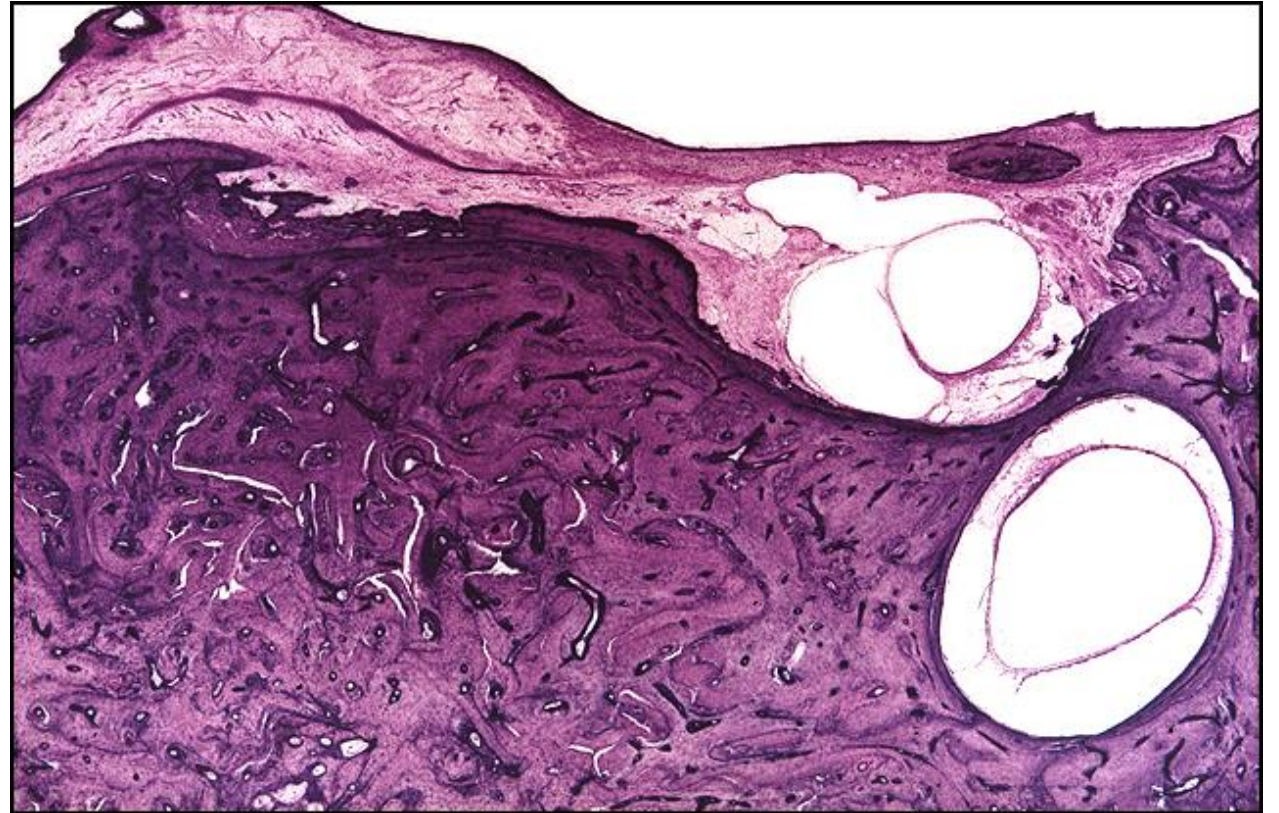
TB Case Number: 70

Gender: Female

Age (yrs.): 64

Otologic Diagnosis:

1. Otosclerosis, severe, bilateral
2. Fenestration, lateral canal, bilateral
3. Semicircular canal, surgical trauma, fenestration, fibrous obliteration, bilateral
4. Mastoid bowl, postoperative, fenestration surgery, healed, bilateral
5. Stapes, fixation, otosclerosis, bilateral
6. Incus, removed, fenestration, bilateral
7. Malleus, capitulum, amputated, bilateral
8. Round window, obliterated, otosclerosis, right



Fenestration, R-120

Title: R-120 Fenestration

Chapter: Surgical Pathology

Chapter Section: Fenestration, Surgery for
Otosclerosis

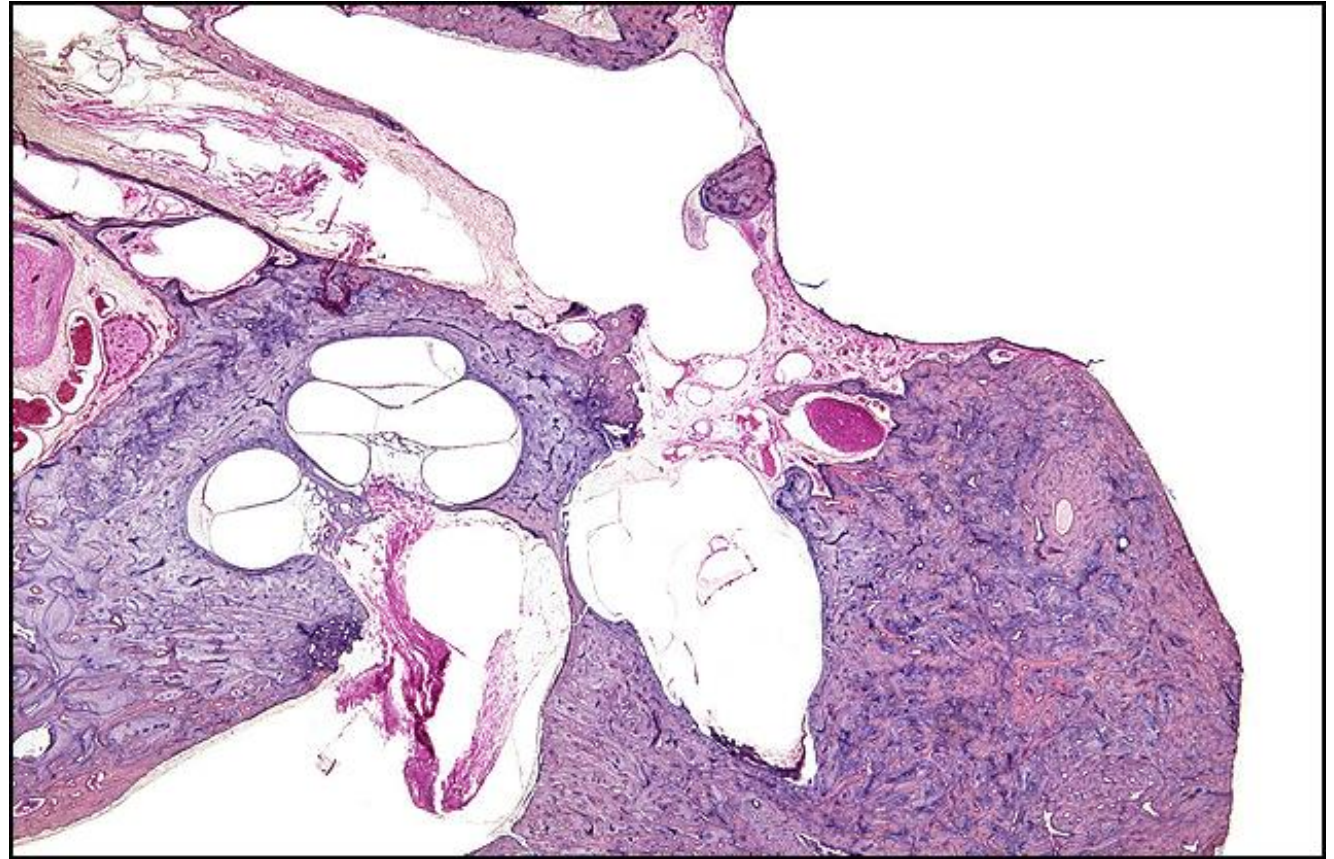
TB Case Number: 381

Gender: Male

Age (yrs.): 79

Otologic Diagnosis:

1. Otosclerosis, bilateral
2. Multiple surgeries including fenestration, revision fenestration, and stapedectomy, right ear as evidenced by, (a) Surgical mastoid cavity (b) Fenestration of the lateral semicircular canal (c) Absence of the stapes
3. Atrophy, severe, auditory and vestibular labyrinths, secondary to surgical procedures for otosclerosis, right ear
4. Schwannoma, occult, internal auditory canal, without compression of nerve trunks



Fenestration, R-40

Title: Fenestration, R-40

Chapter: Surgical Pathology

Chapter Section: Fenestration, Surgery for
Otosclerosis

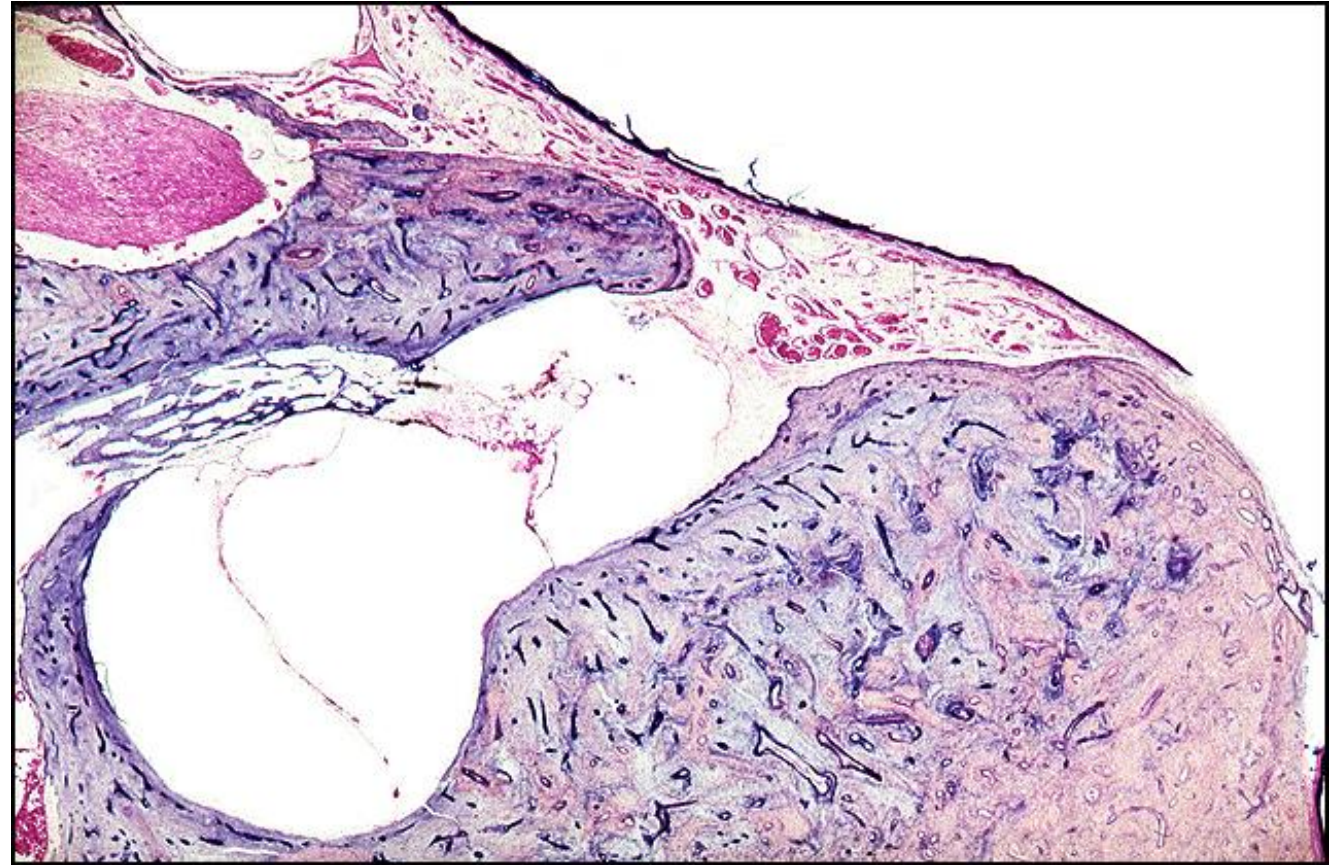
TB Case Number: 381

Gender: Male

Age (yrs.): 79

Otologic Diagnosis:

1. Otosclerosis, bilateral
2. Multiple surgeries including fenestration, revision fenestration, and stapedectomy, right ear as evidenced by, (a) Surgical mastoid cavity (b) Fenestration of the lateral semicircular canal (c) Absence of the stapes
3. Atrophy, severe, auditory and vestibular labyrinths, secondary to surgical procedures for otosclerosis, right ear
4. Schwannoma, occult, internal auditory canal, without compression of nerve trunks



Fenestration, R-260

Title: Fenestration, R-260

Chapter: Surgical Pathology

Chapter Section: Fenestration, Surgery for
Otosclerosis

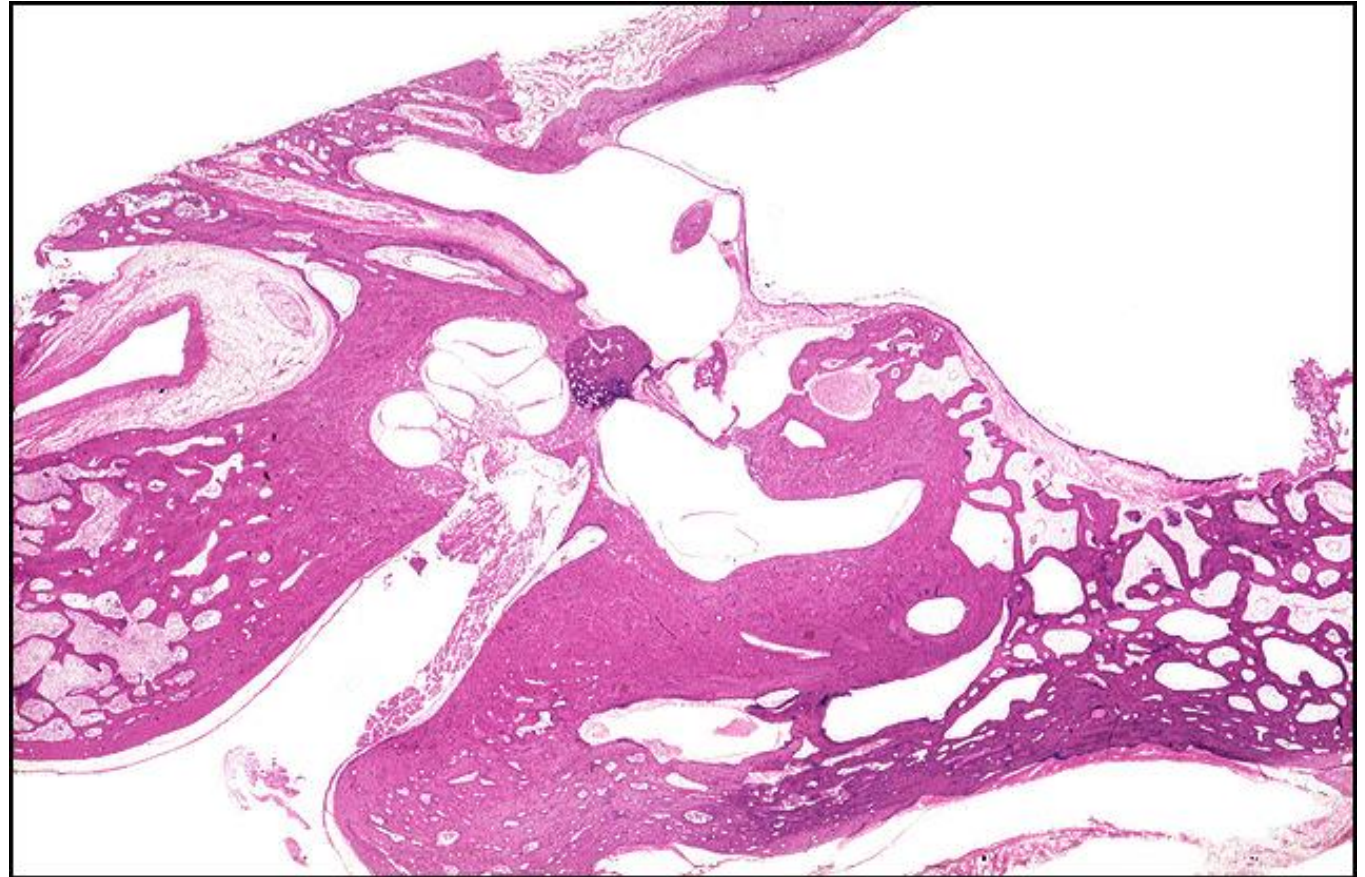
TB Case Number: 477

Gender: Female

Age (yrs.): 51

Otologic Diagnosis:

1. Otosclerosis, bilateral
2. Stapes mobilization, right
3. Fenestration operation, right
4. Partial stapedectomy and prosthesis operation, left



Fenestration, R-260

Title: Fenestration, R-260

Chapter: Surgical Pathology

Chapter Section: Fenestration, Surgery for
Otosclerosis

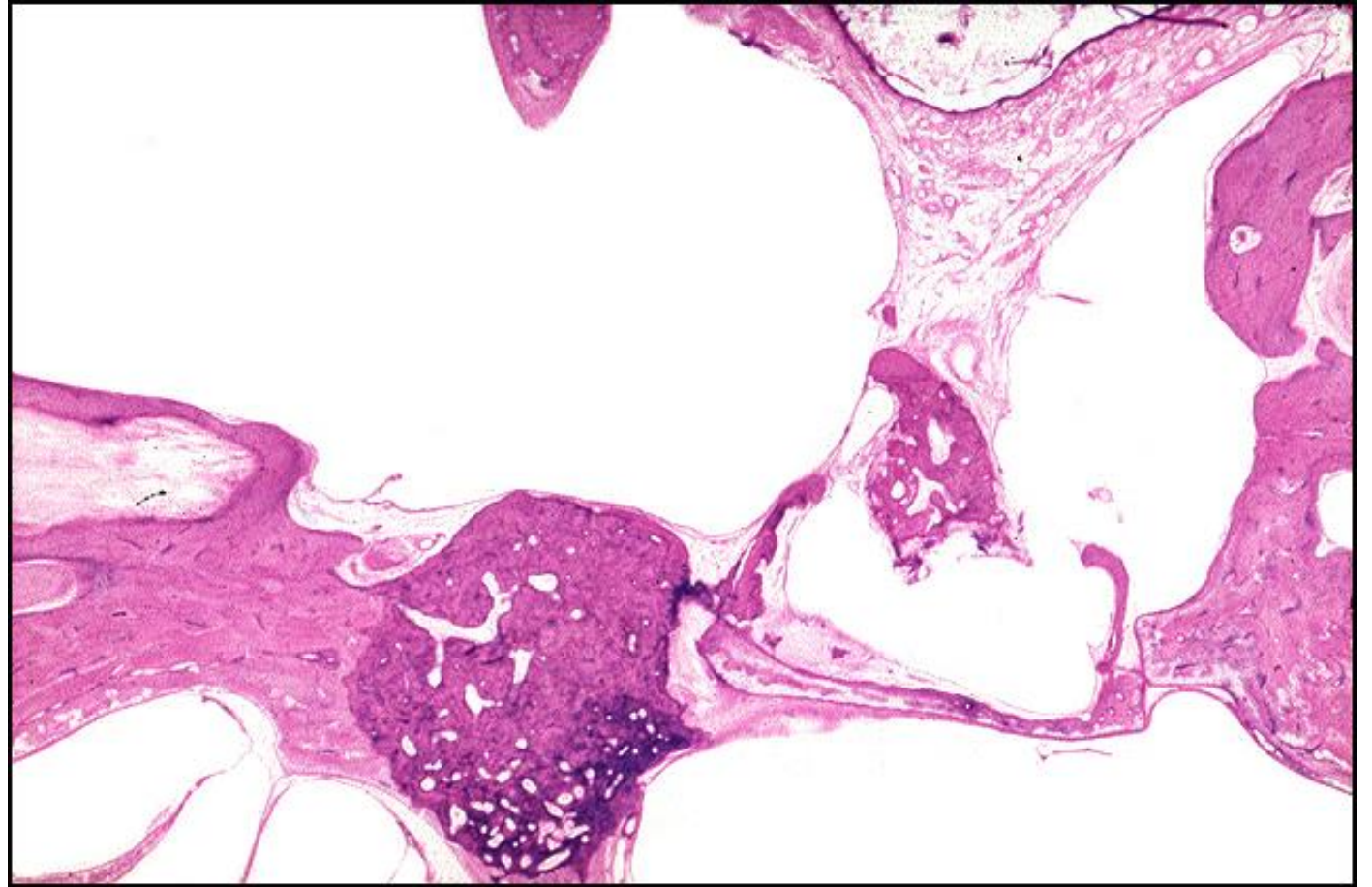
TB Case Number: 477

Gender: Female

Age (yrs.): 51

Otologic Diagnosis:

1. Otosclerosis, bilateral
2. Stapes mobilization, right
3. Fenestration operation, right
4. Partial stapedectomy and prosthesis operation, left



Fenestration, R-141

Title: Fenestration, R-141

Chapter: Surgical Pathology

Chapter Section: Fenestration, Surgery for
Otosclerosis

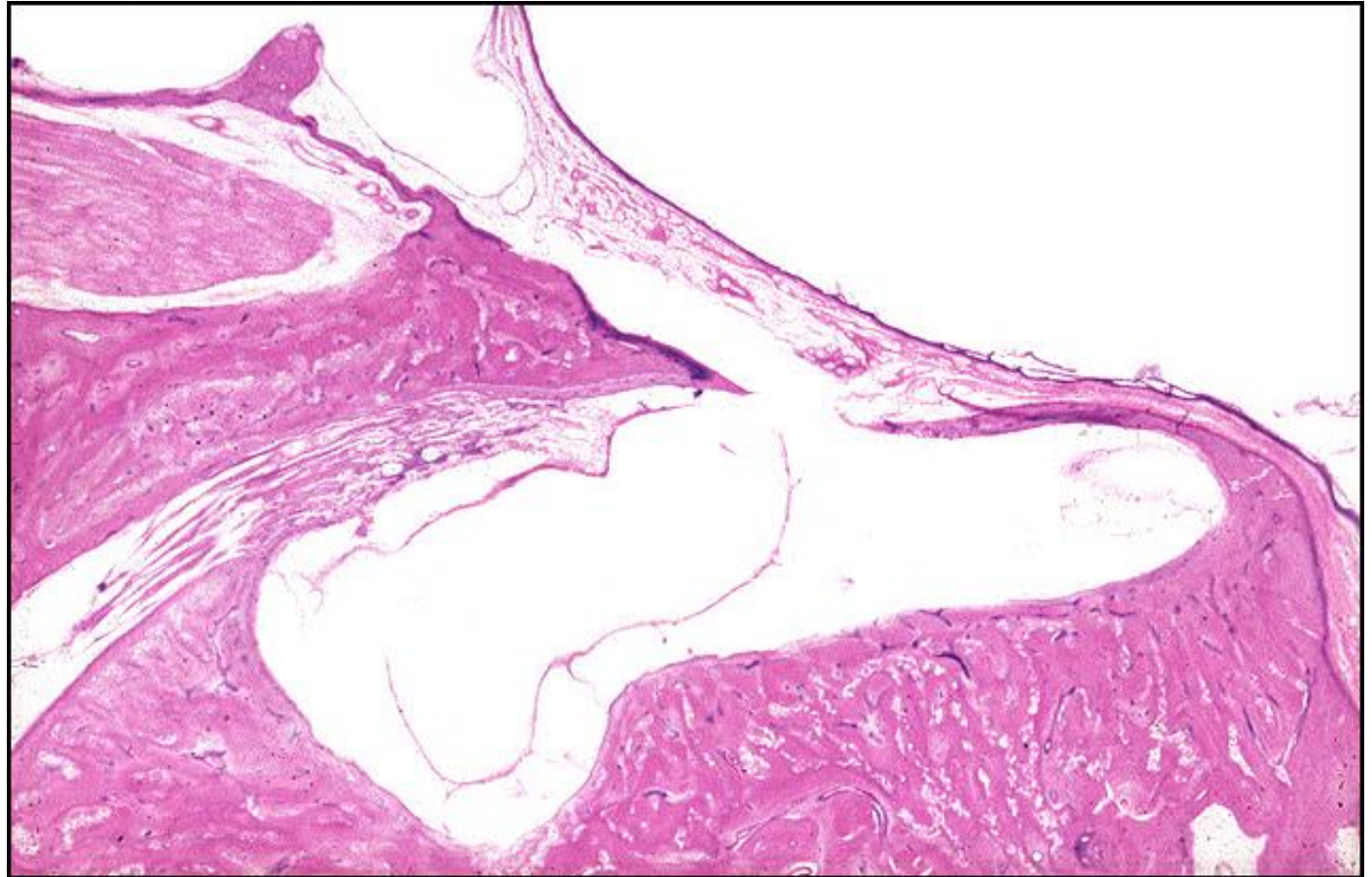
TB Case Number: 477

Gender: Female

Age (yrs.): 51

Otologic Diagnosis:

1. Otosclerosis, bilateral
2. Stapes mobilization, right
3. Fenestration operation, right
4. Partial stapedectomy and prosthesis operation, left



Fenestration, R-130

Title: Fenestration, R-130

Chapter: Surgical Pathology

Chapter Section: Fenestration, Surgery for
Otosclerosis

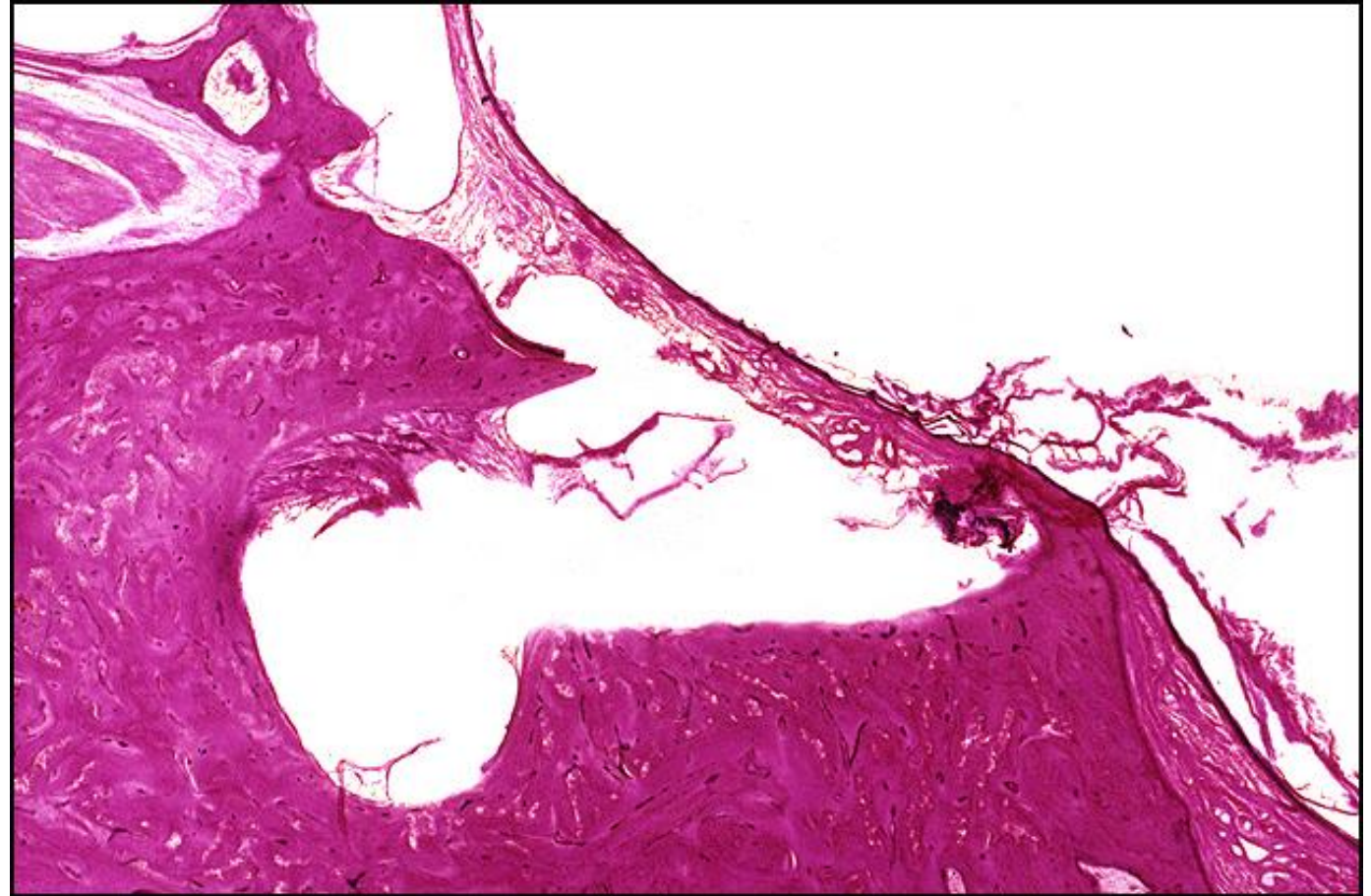TB Case Number: 477

Gender: Female

Age (yrs.): 51

Otologic Diagnosis:

1. Otosclerosis, bilateral
2. Stapes mobilization, right
3. Fenestration operation, right
4. Partial stapedectomy and prosthesis operation, left



Fenestration, R-191

Title: Fenestration, R-191

Chapter: Surgical Pathology

Chapter Section: Fenestration, Surgery for
Otosclerosis

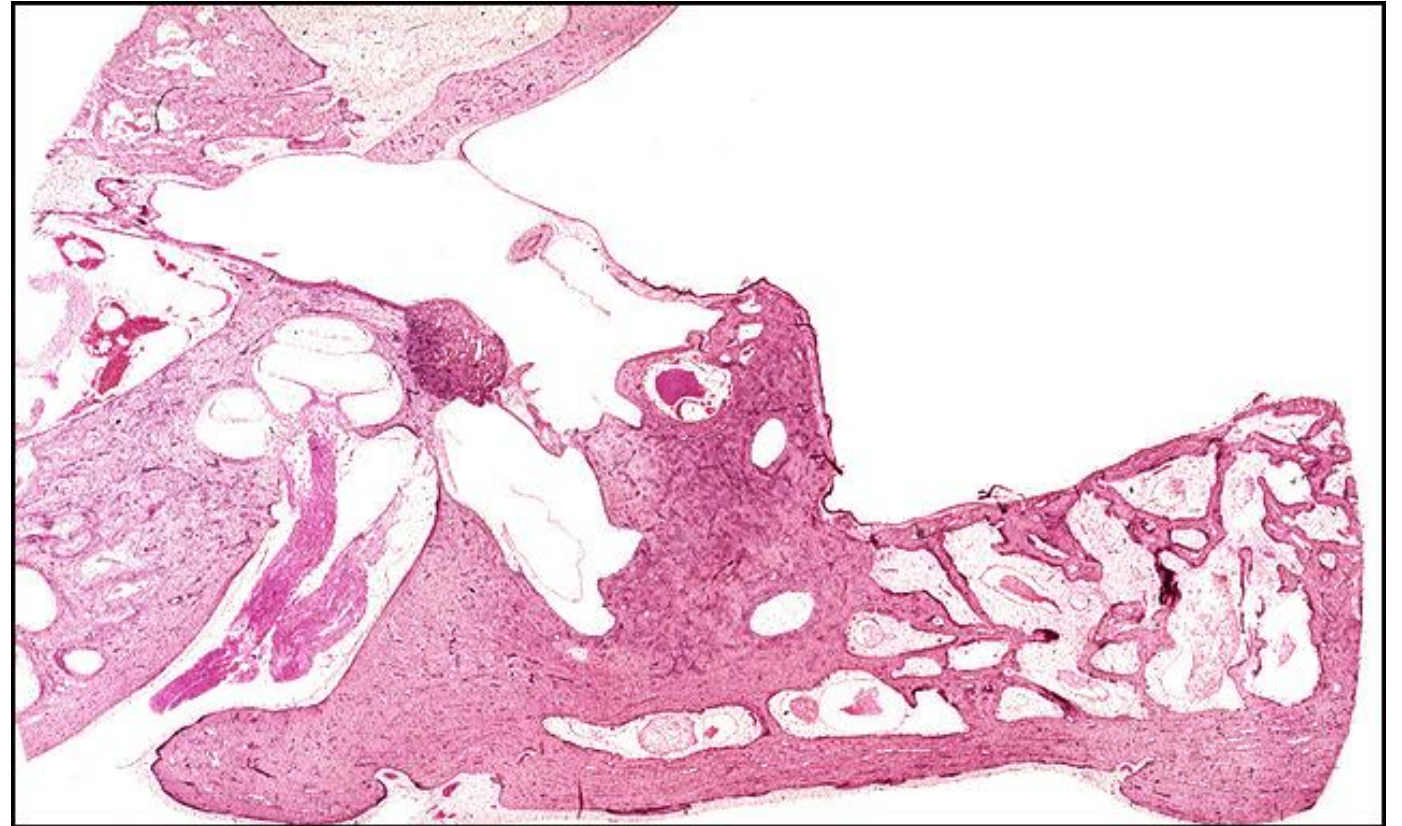
TB Case Number: 843

Gender: Female

Age (yrs.): 56

Otologic Diagnosis:

1. Otosclerosis, with stapes fixation, bilateral
2. Fenestra nov-ovalis, right (at patient age 38)



Fenestration, R-321

Title: Fenestration, R-321

Chapter: Surgical Pathology

Chapter Section: Fenestration, Surgery for
Otosclerosis

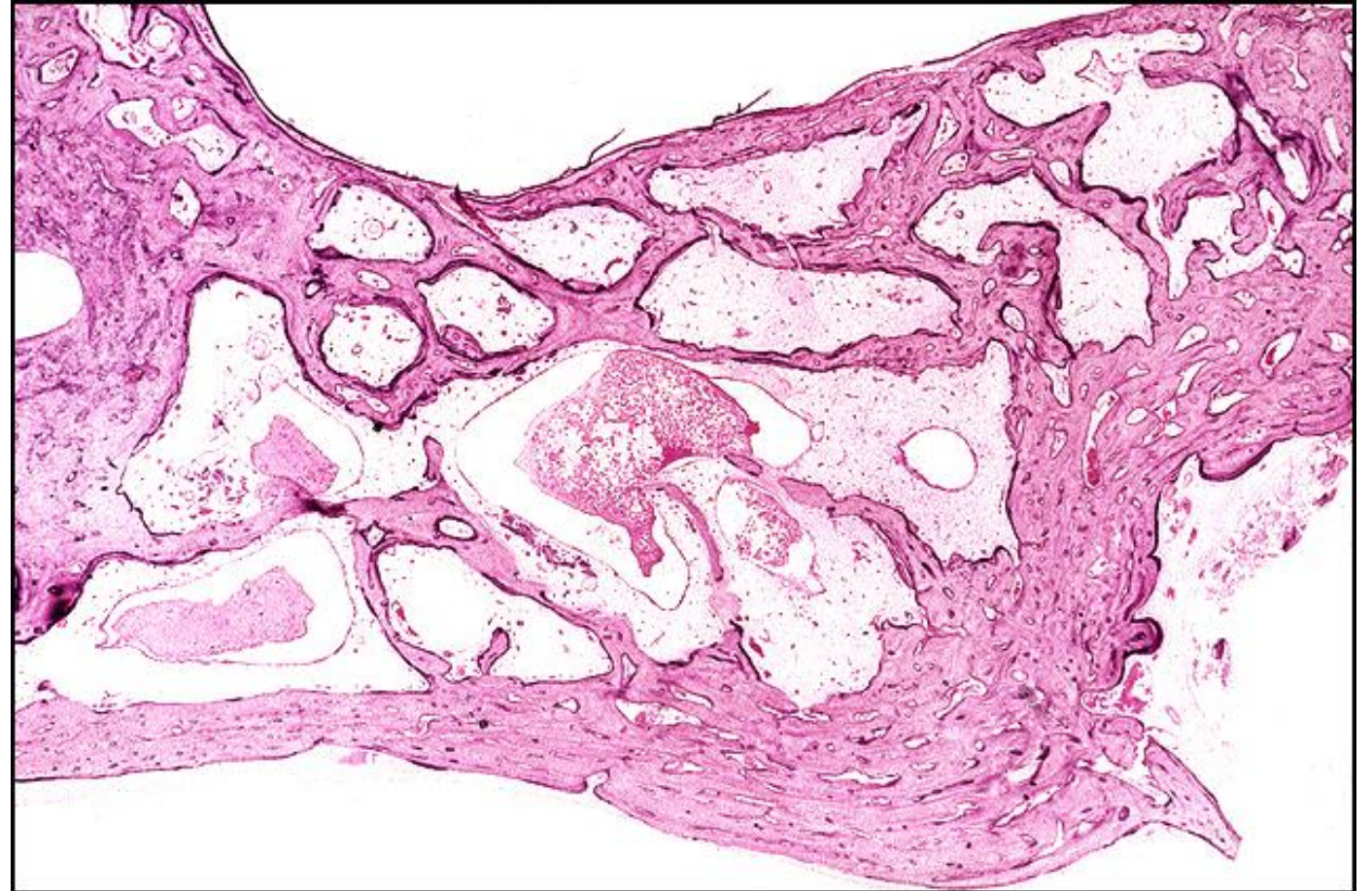
TB Case Number: 843

Gender: Female

Age (yrs.): 56

Otologic Diagnosis:

1. Otosclerosis, with stapes fixation, bilateral
2. Fenestra nov-ovalis, right (at patient age 38)



Fenestration, R-25

Title: Fenestration, R-25

Chapter: Surgical Pathology

Chapter Section: Fenestration, Surgery for
Otosclerosis

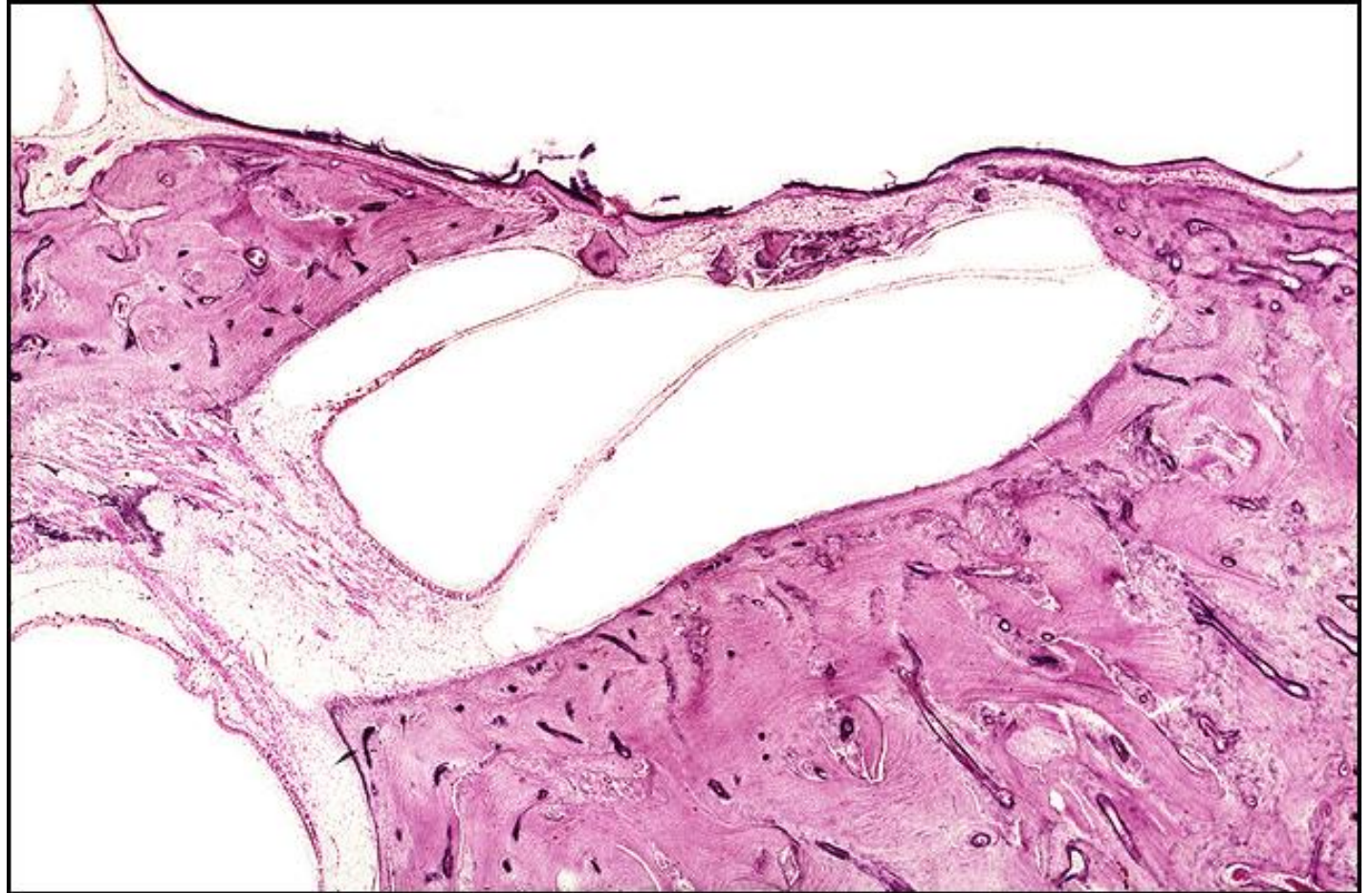TB Case Number: 843

Gender: Female

Age (yrs.): 56

Otologic Diagnosis:

1. Otosclerosis, with stapes fixation, bilateral
2. Fenestra nov-ovalis, right (at patient age 38)



Fenestration, R-181

Title: Fenestration, R-181

Chapter: Surgical Pathology

Chapter Section: Fenestration, Surgery for Otosclerosis

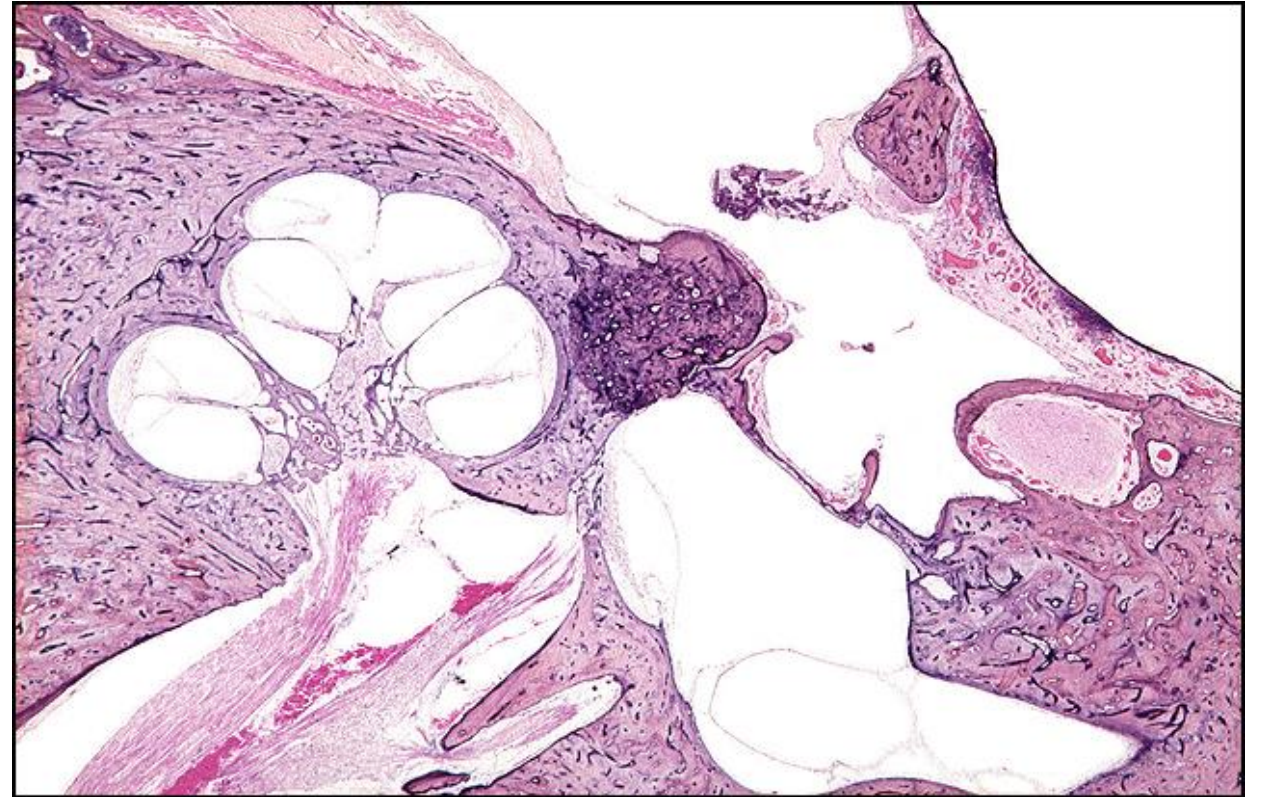
TB Case Number: 868

Gender: Female

Age (yrs.): 76

Otologic Diagnosis:

1. Otosclerosis, bony labyrinth, anterior to oval window, right
2. Stapes fixation caused by otosclerosis, right
3. Fenestration, surgical, lateral semicircular canal, right
4. Modified tympanomastoidectomy, subsequent to fenestration surgery, right
5. Incus, surgical removal, with fenestration surgery, right
6. Malleus, removal of head of malleus with fenestration surgery, right
7. Cochlea, normal, right
8. Vestibular labyrinth, normal, right



Fenestration, R-50

Title: Fenestration, R-50

Chapter: Surgical Pathology

Chapter Section: Fenestration, Surgery for Otosclerosis

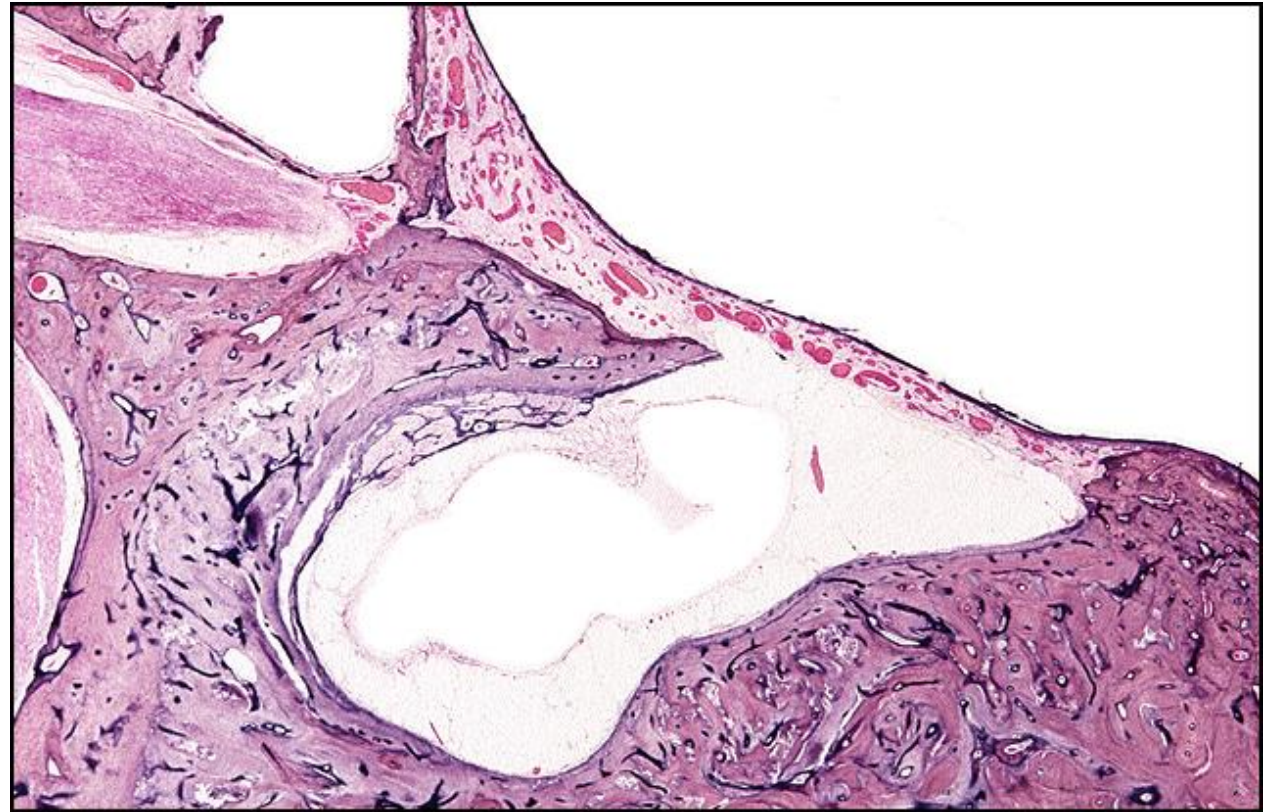
TB Case Number: 868

Gender: Female

Age (yrs.): 76

Otologic Diagnosis:

1. Otosclerosis, bony labyrinth, anterior to oval window, right
2. Stapes fixation caused by otosclerosis, right
3. Fenestration, surgical, lateral semicircular canal, right
4. Modified tympanomastoidectomy, subsequent to fenestration surgery, right
5. Incus, surgical removal, with fenestration surgery, right
6. Malleus, removal of head of malleus with fenestration surgery, right
7. Cochlea, normal, right
8. Vestibular labyrinth, normal, right



Fenestration, L-31

Title: Fenestration, L-31

Chapter: Surgical Pathology

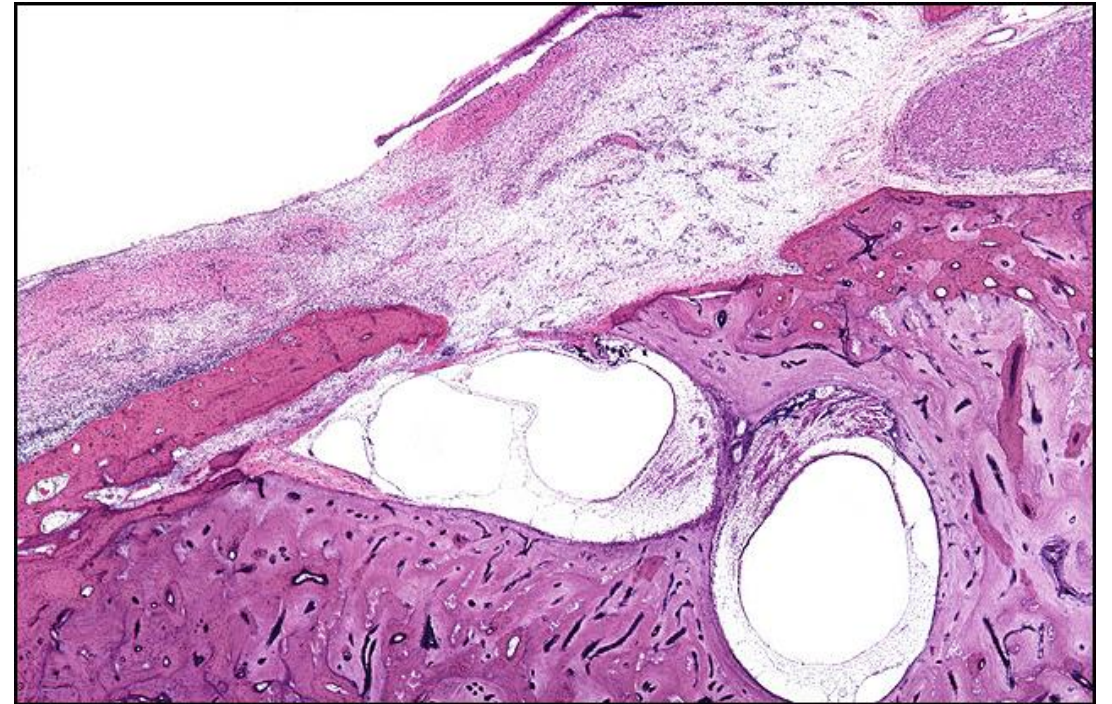
Chapter Section: Fenestration, Surgery for Otosclerosis

TB Case Number: 358

Gender: Female **Age (yrs.):** 83

Otologic Diagnosis:

1. Fenestration operation, left ear, as evidenced by restricted radical mastoidectomy
2. Advancement of the tympanic membrane, removal of incus, and fenestration of the lateral semicircular canal
3. Partial osseous closure of fenestra, left lateral semicircular canal
4. Skin graft myringoplasties causing thickening of the tympanic membrane with glandular tissue and cysts
5. Missing incus, presumably inadvertently subluxed, right ear
6. Stapedectomy, right ear, with introduction of malleusto-oval window prosthesis
7. Degeneration of the organ of Corti characterized by missing organ of Corti in the basal two-thirds of the cochlea and partial loss of hair cells in the apical one-third
8. Primary neural degeneration of aging (presbycusis), severe



Fenestration, R-84

Title: Fenestration, R-84

Chapter: Surgical Pathology

Chapter Section: Fenestration, Surgery for Otosclerosis

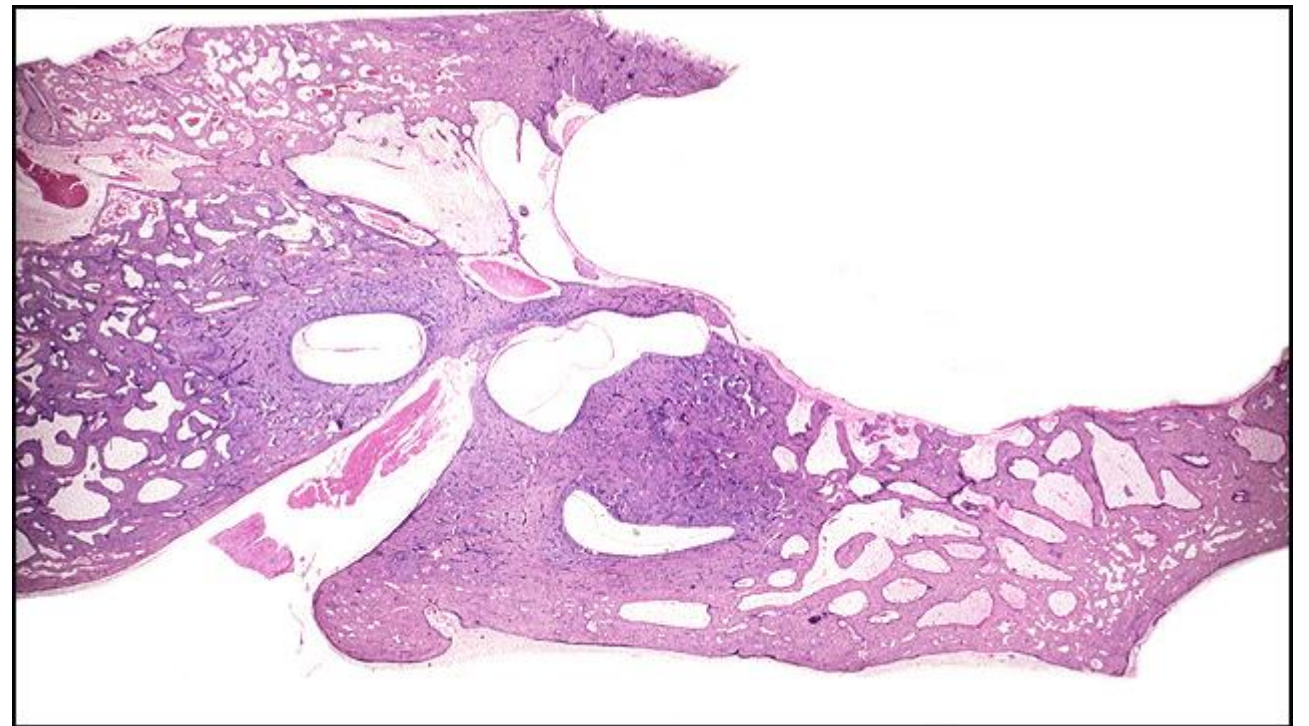
TB Case Number: 256

Gender: Male

Age (yrs.): 80

Otologic Diagnosis:

1. Otosclerosis, clinical, bilateral
2. Fenestration, lateral canal, surgical, right
3. Semicircular canal, lateral, fenestra, surgical, right
4. Stapedectomy, malleus-oval window plastic prosthesis, right
5. Stapes, surgical removal, otosclerosis, bilateral
6. Stapedectomy, partial, incus-oval window plastic prosthesis, left
7. Incus, resorptive osteitis, stapedectomy, left
8. Artifact, preparation, membranous labyrinth, tears, bilateral
9. Artifact, postmortem autolysis, membranous labyrinth, bilateral



Fenestration, R-142

Title: Fenestration, R-142

Chapter: Surgical Pathology

Chapter Section: Fenestration, Surgery for Otosclerosis

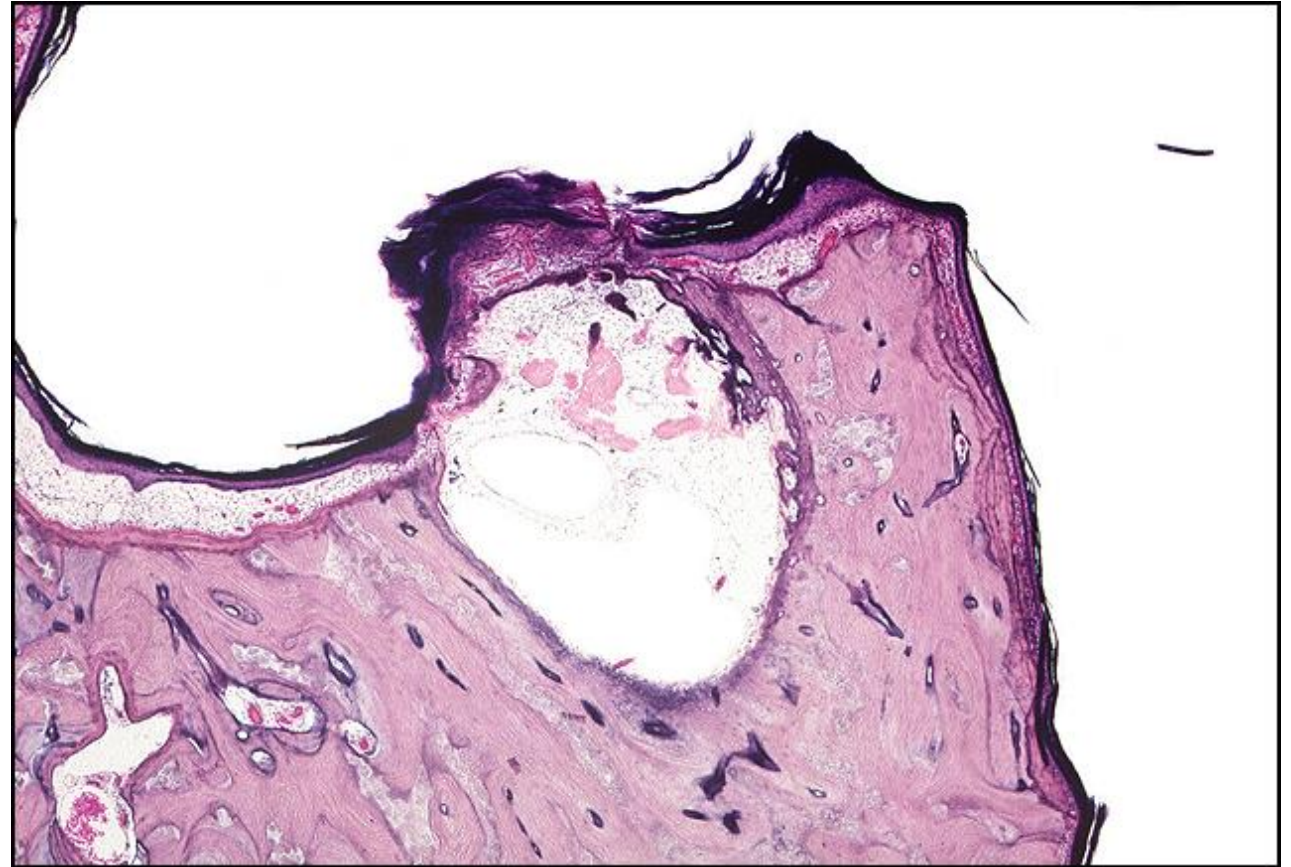
TB Case Number: 892

Gender: Female

Age (yrs.): 87

Otologic Diagnosis:

1. Otosclerosis, clinical, mild, bilateral
2. Fenestration, nov ovalis, lateral canal, unsuccessful, age 37, right
3. Fenestration, bony obliteration, right
4. Stapedotomy, Tef-wire piston, age 64, fenestrated ear, right
5. Stapes mobilization, successful, age 51, left
6. Cholesteatoma, fenestration cavity, right



Stapedectomy, Fat Wire, R-201

Title: Stapedectomy, Fat Wire, R-201

Chapter: Surgical Pathology

Chapter Section: Fat and Wire, Stapedectomy, Surgery for Otosclerosis

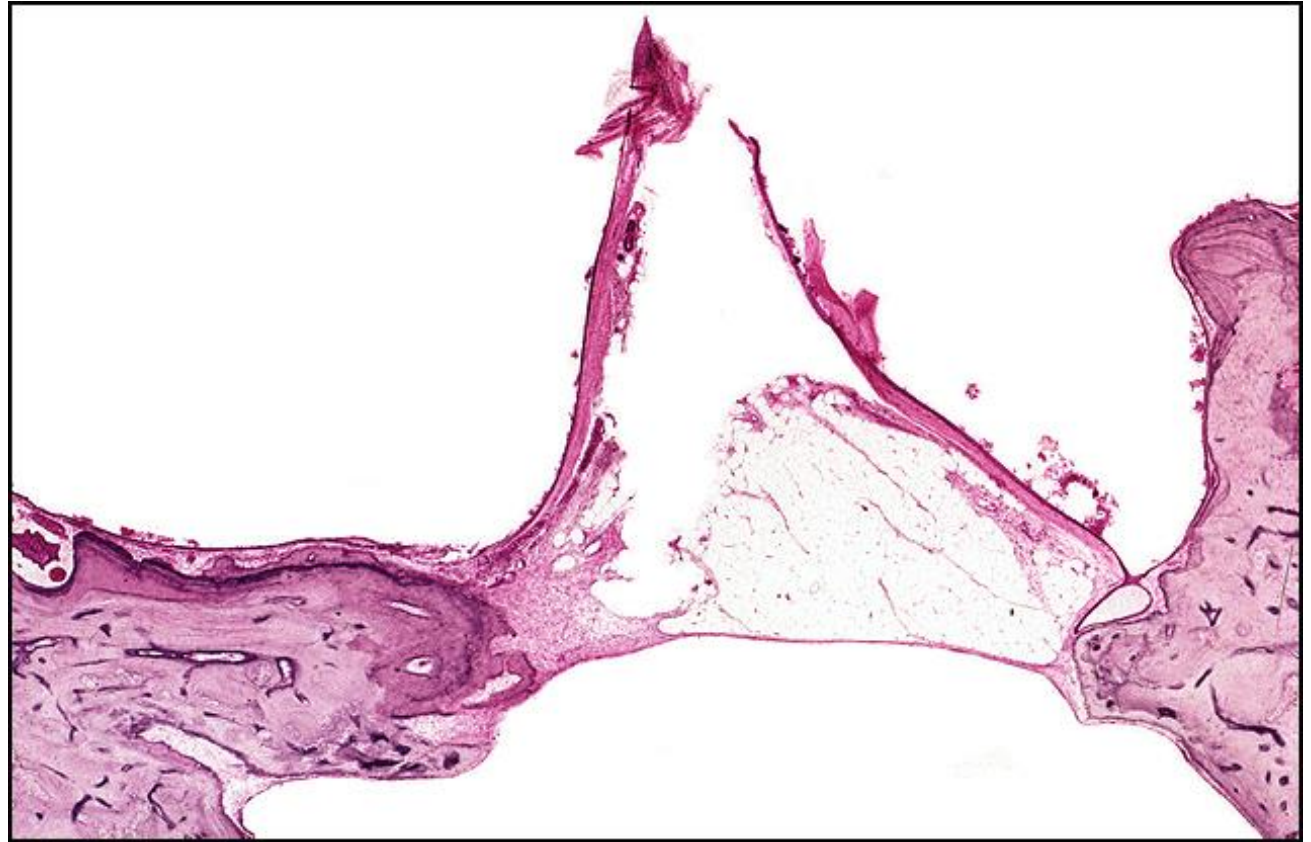
TB Case Number: 33

Gender: Male

Age (yrs.): 60

Otologic Diagnosis:

1. Otosclerosis with stapes fixation, clinical, bilateral
2. Stapedectomy, fat-wire prosthesis, right
3. Stapedectomy, gel-wire prosthesis, left
4. Tympanic membrane, surgical trauma, healed, bilateral
5. Compression artifact, severe, bilateral
6. Chorda tympani nerve, severe atrophy, iatrogenic, bilateral
7. Exostoses, external auditory canal, left



Stapedectomy Tef-wire, R-191

Title: R-191 Stapedectomy Tef-wire

Chapter: Surgical Pathology

Chapter Section: Stapedectomy, Surgery for
Otosclerosis, Wire and Teflon

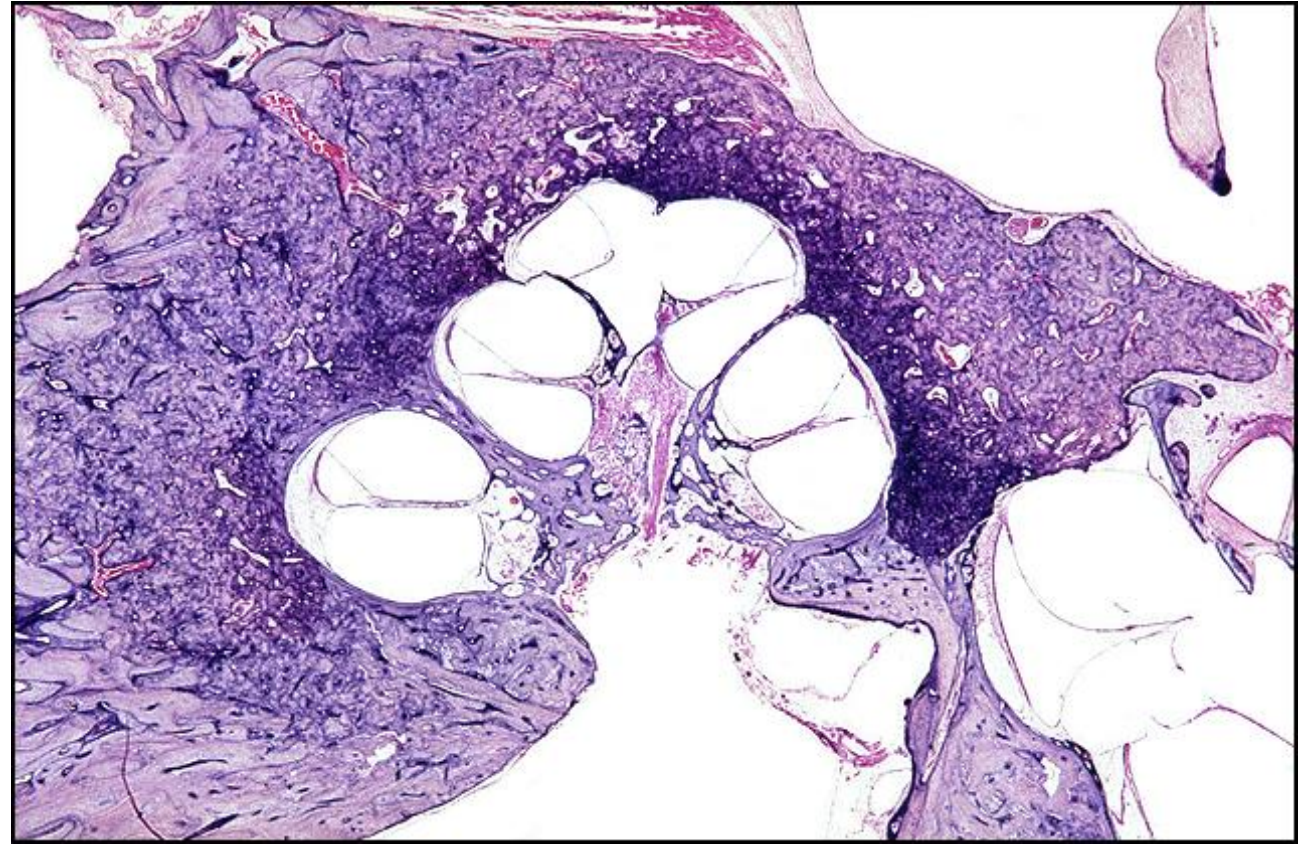
TB Case Number: 52

Gender: Male

Age (yrs.): 56

Otologic Diagnosis:

1. Meniere's disease, left
2. Endolymphatic hydrops, severe, cochlea and saccule
3. Acoustic trauma, right
4. Sigmoid sinus, anomalies, bilateral
5. Presbycusis, neural
6. Epitympanic retraction pockets, mild, bilateral
7. Heterotopia, auricle tissue, external auditory canal, bilateral
8. Malleus, head, resorptive osteitis, remote, left



Stapedectomy Tef-wire, R-191

Title: Stapedectomy Tef-wire, R-191

Chapter: Surgical Pathology

Chapter Section: Stapedectomy, Surgery for
Otosclerosis, Wire and Teflon

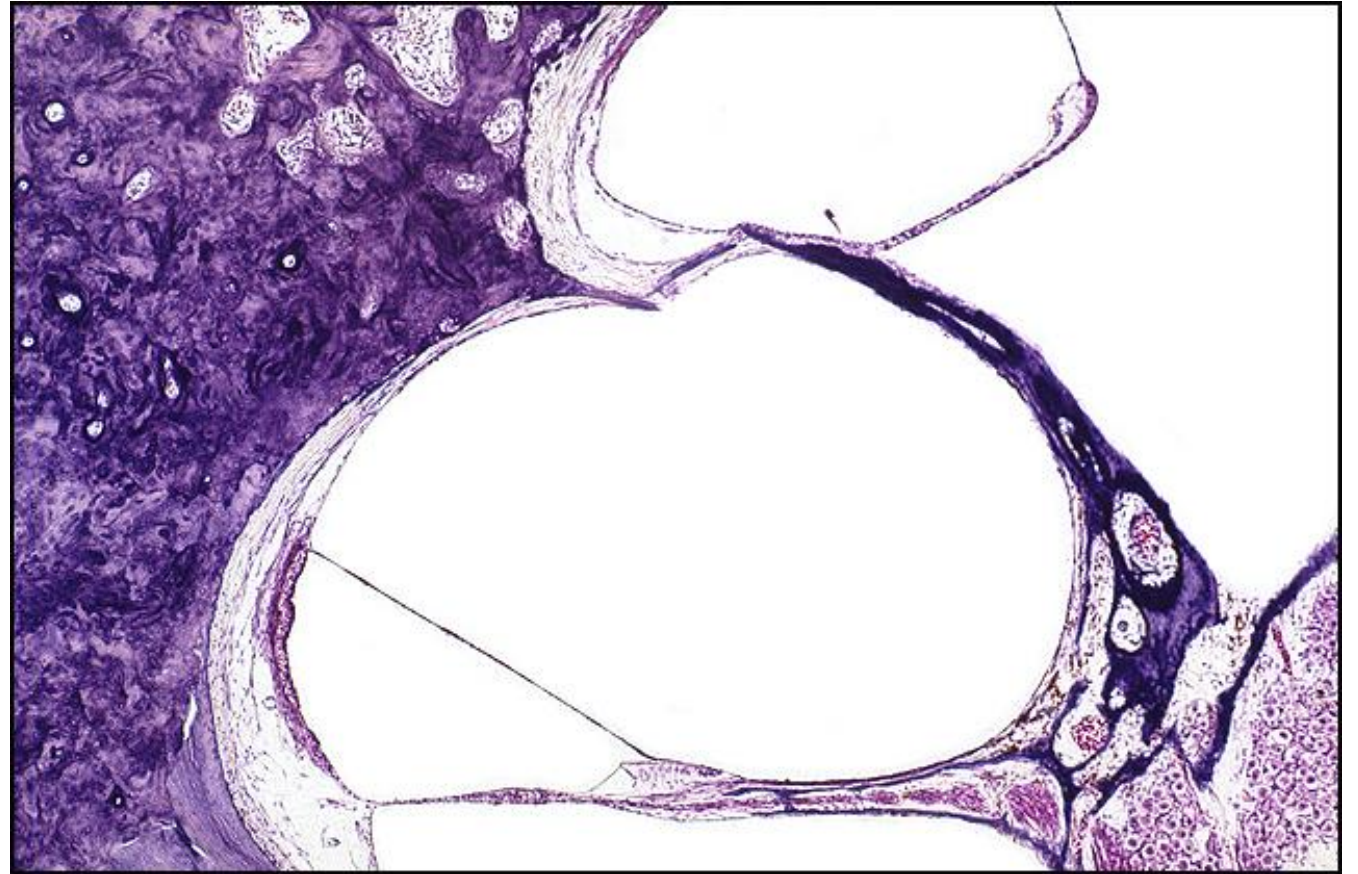
TB Case Number: 52

Gender: Male

Age (yrs.): 56

Otologic Diagnosis:

1. Meniere's disease, left
2. Endolymphatic hydrops, severe, cochlea and saccule
3. Acoustic trauma, right
4. Sigmoid sinus, anomalies, bilateral
5. Presbycusis, neural
6. Epitympanic retraction pockets, mild, bilateral
7. Heterotopia, auricle tissue, external auditory canal, bilateral
8. Malleus, head, resorptive osteitis, remote, left



Stapedectomy, Tef-wire, R-201

Title: Stapedectomy, Tef-wire, R-201

Chapter: Surgical Pathology

Chapter Section: Stapedectomy, Surgery for
Otosclerosis, Wire and Teflon

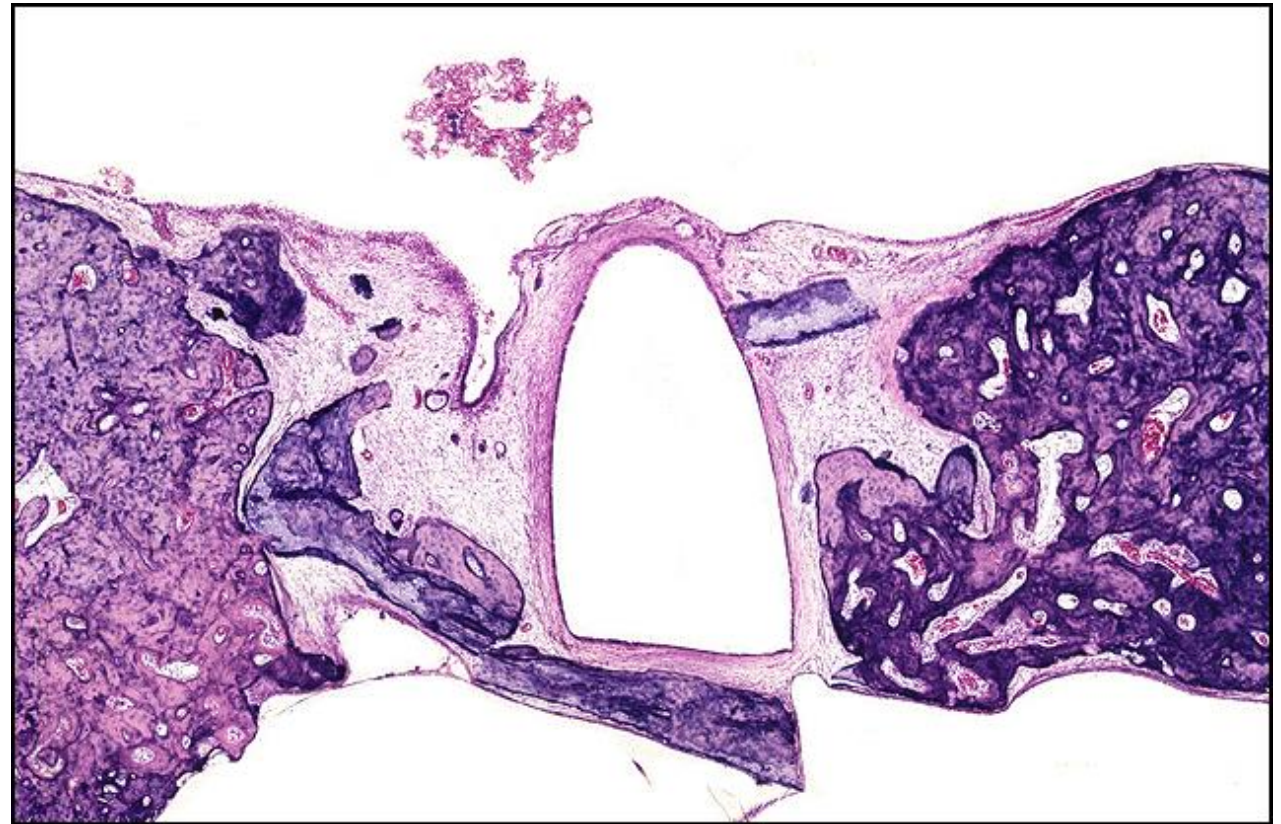
TB Case Number: 52

Gender: Male

Age (yrs.): 56

Otologic Diagnosis:

1. Meniere's disease, left
2. Endolymphatic hydrops, severe, cochlea and saccule
3. Acoustic trauma, right
4. Sigmoid sinus, anomalies, bilateral
5. Presbycusis, neural
6. Epitympanic retraction pockets, mild, bilateral
7. Heterotopia, auricle tissue, external auditory canal, bilateral
8. Malleus, head, resorptive osteitis, remote, left



Stapedectomy, Tef-wire (piston), R-311

Title: Stapedectomy, Tef-wire (piston), R-311

Chapter: Surgical Pathology

Chapter Section: Stapedectomy, Surgery for Otosclerosis, Wire and Teflon

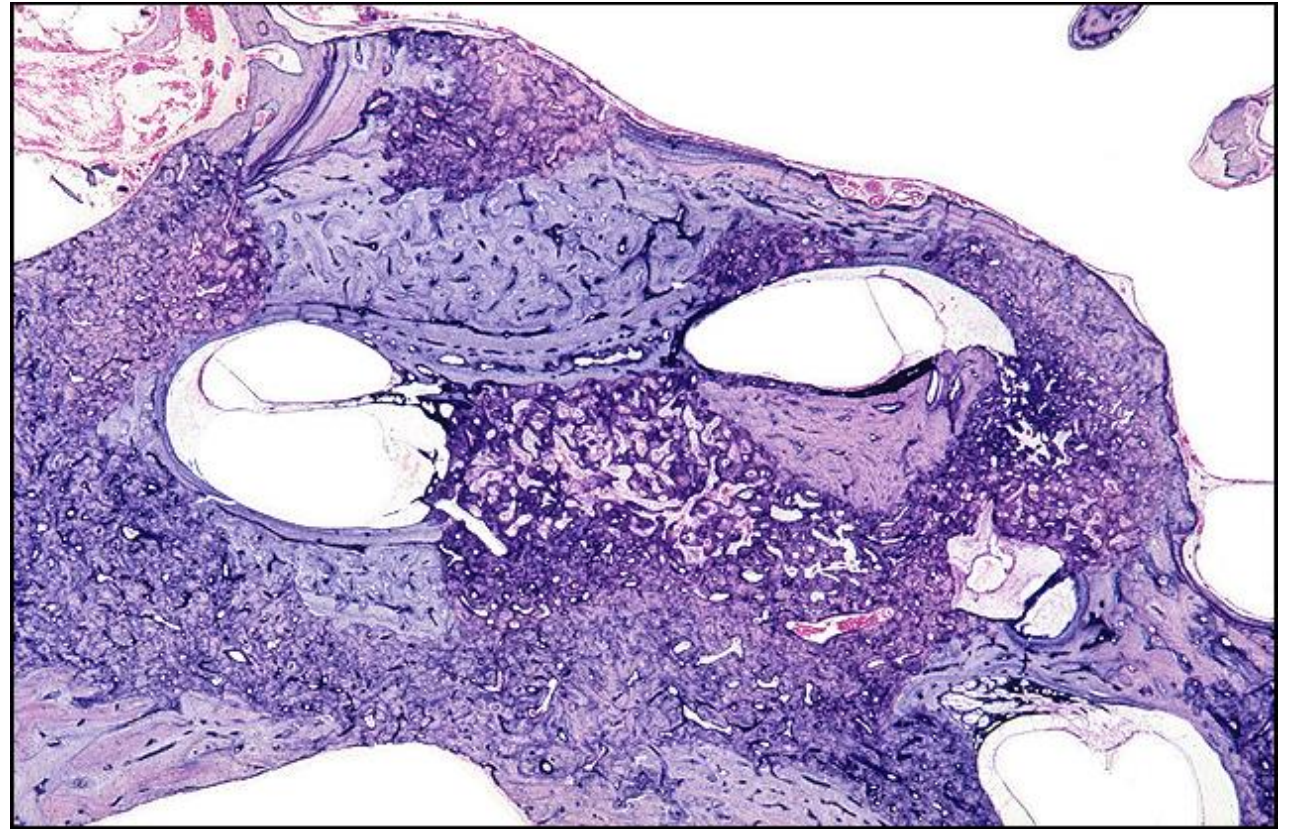
TB Case Number: 52

Gender: Male

Age (yrs.): 56

Otologic Diagnosis:

1. Meniere's disease, left
2. Endolymphatic hydrops, severe, cochlea and saccule
3. Acoustic trauma, right
4. Sigmoid sinus, anomalies, bilateral
5. Presbycusis, neural
6. Epitympanic retraction pockets, mild, bilateral
7. Heterotopia, auricle tissue, external auditory canal, bilateral
8. Malleus, head, resorptive osteitis, remote, left



Stapedectomy Tef-wire (piston), R-286

Title: Stapedectomy Tef-wire (piston), R-286

Chapter: Surgical Pathology

Chapter Section: Stapedectomy, Surgery for
Otosclerosis, Wire and Teflon

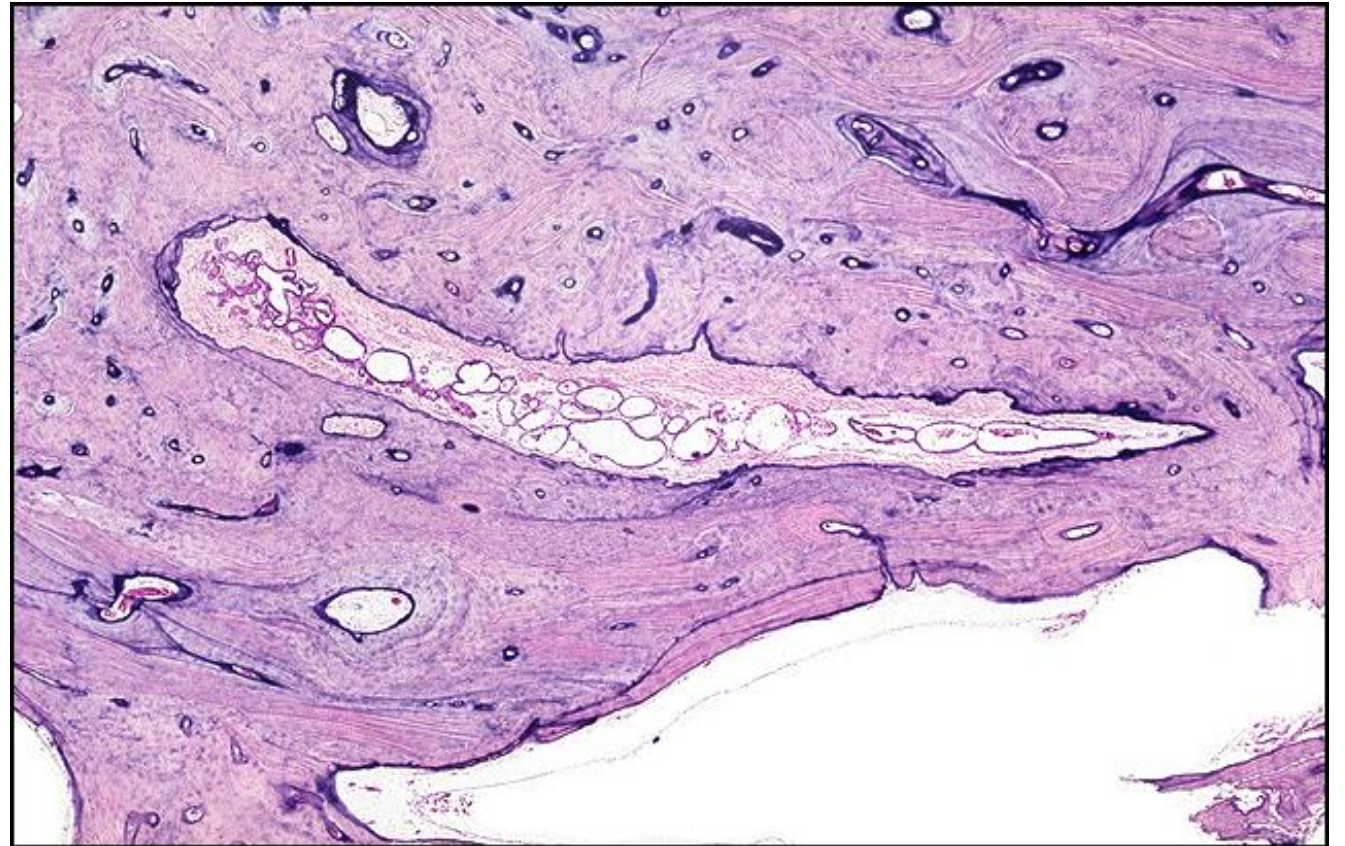
TB Case Number: 52

Gender: Male

Age (yrs.): 56

Otologic Diagnosis:

1. Meniere's disease, left
2. Endolymphatic hydrops, severe, cochlea and saccule
3. Acoustic trauma, right
4. Sigmoid sinus, anomalies, bilateral
5. Presbycusis, neural
6. Epitympanic retraction pockets, mild, bilateral
7. Heterotopia, auricle tissue, external auditory canal, bilateral
8. Malleus, head, resorptive osteitis, remote, left



Stapedectomy, L-230

Title: Stapedectomy, L-230

Chapter: Surgical Pathology

Chapter Section: Polyethylene Tube, Stapedectomy,
Surgery for Otosclerosis

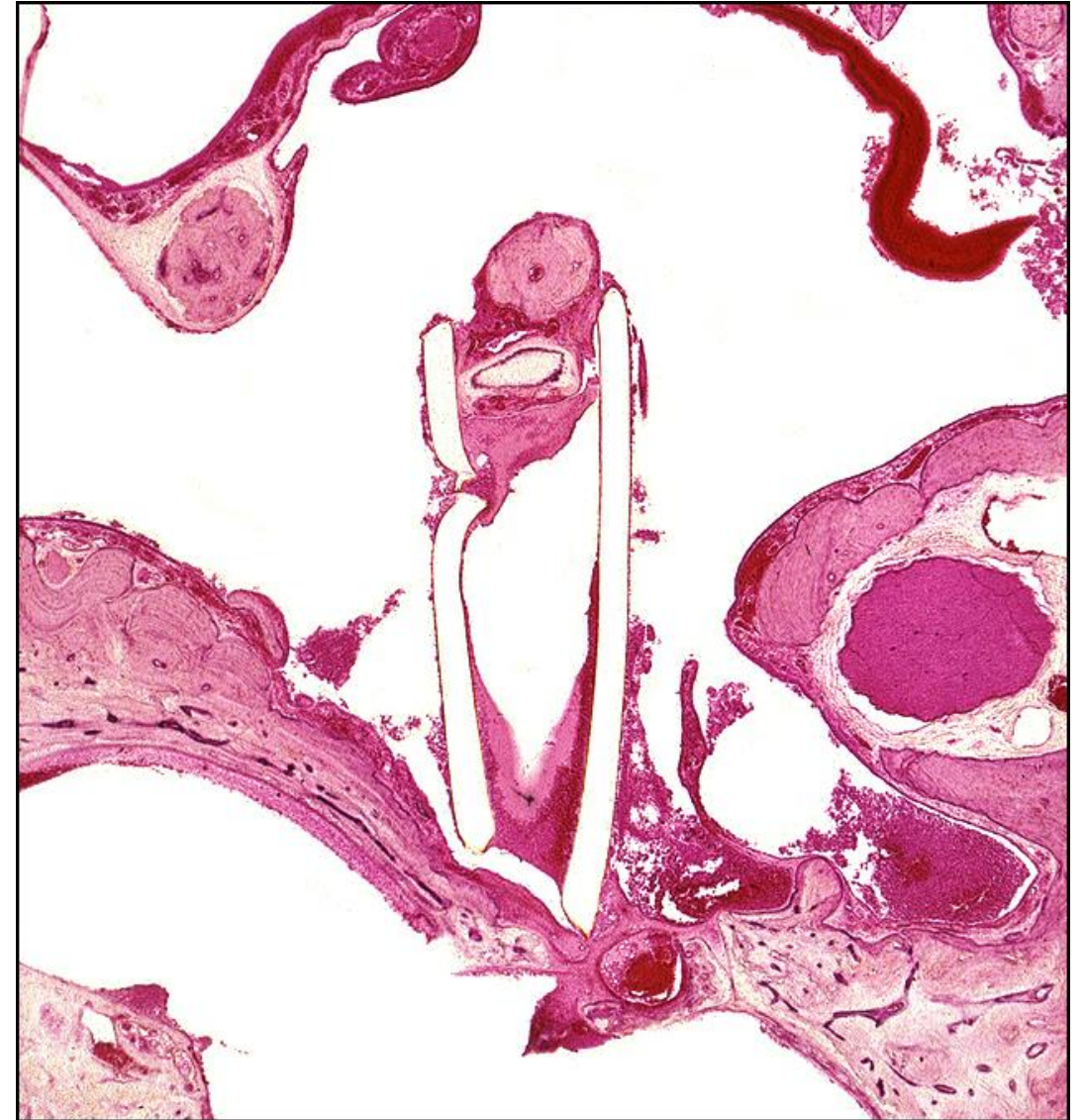TB Case Number: 236

Gender: Male

Age (yrs.): 39

Otologic Diagnosis:

1. Otosclerosis, clinical, small, left
2. Stapedectomy, partial, polyethylene tube prosthesis, 1959 (age 37), left
3. Fistula, perilymph, oval window, postoperative, left
4. Otitis media, suppurative, pneumococcal, left
5. Labyrinthitis, suppurative, pneumococcal, left
6. Meningitis, suppurative, pneumococcal



PE Tube, L-299

Title: PE Tube, L-299

Chapter: Surgical Pathology

Chapter Section: Polyethylene Tube, Stapedectomy,
Surgery for Otosclerosis

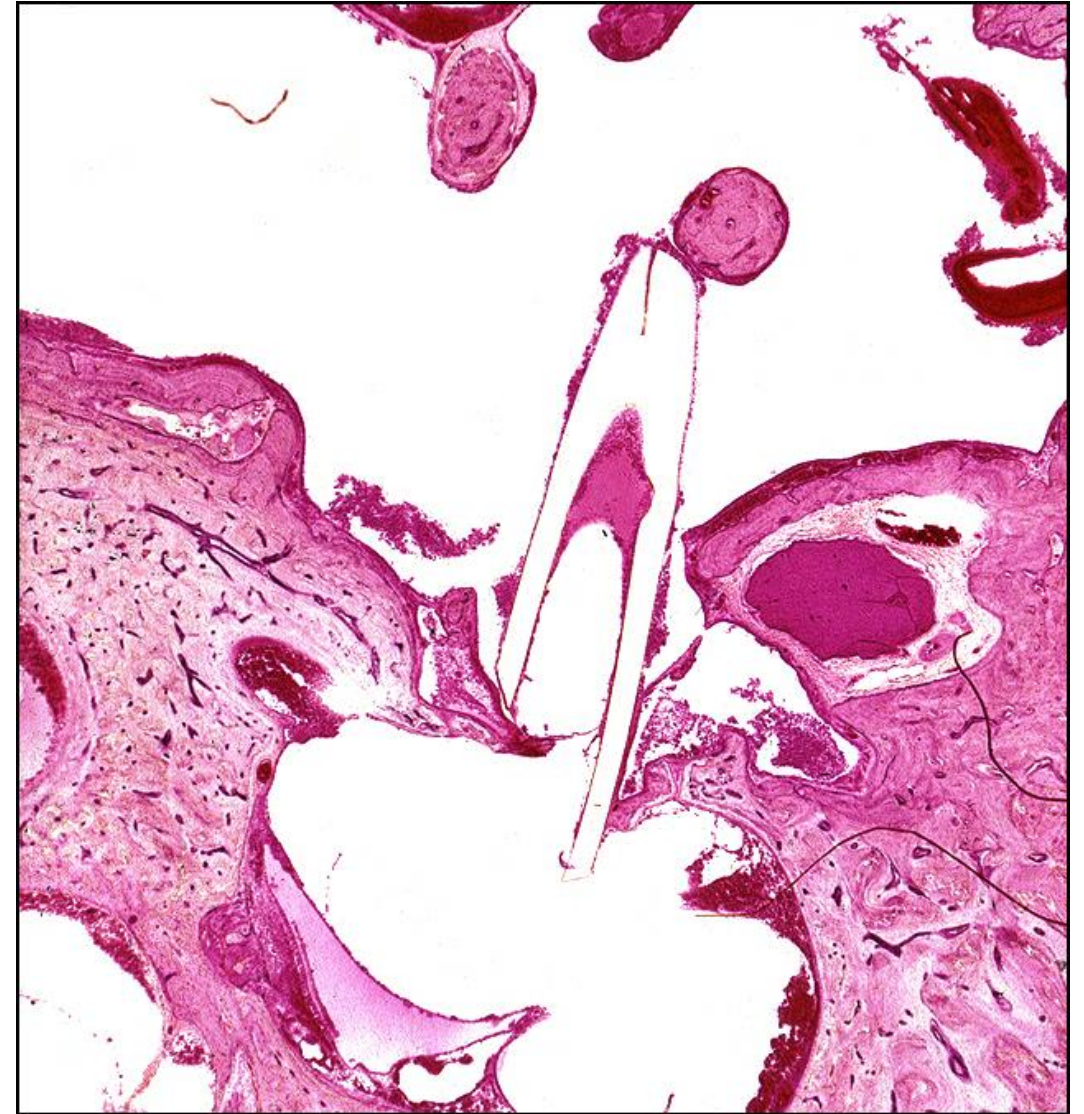TB Case Number: 236

Gender: Male

Age (yrs.): 39

Otologic Diagnosis:

1. Otosclerosis, clinical, small, left
2. Stapedectomy, partial, polyethylene tube prosthesis, 1959 (age 37), left
3. Fistula, perilymph, oval window, postoperative, left
4. Otitis media, suppurative, pneumococcal, left
5. Labyrinthitis, suppurative, pneumococcal, left
6. Meningitis, suppurative, pneumococcal



Stapedectomy, L-219

Title: Stapedectomy, L-219

Chapter: Surgical Pathology

Chapter Section: Polyethylene Tube, Stapedectomy, Surgery for Otosclerosis

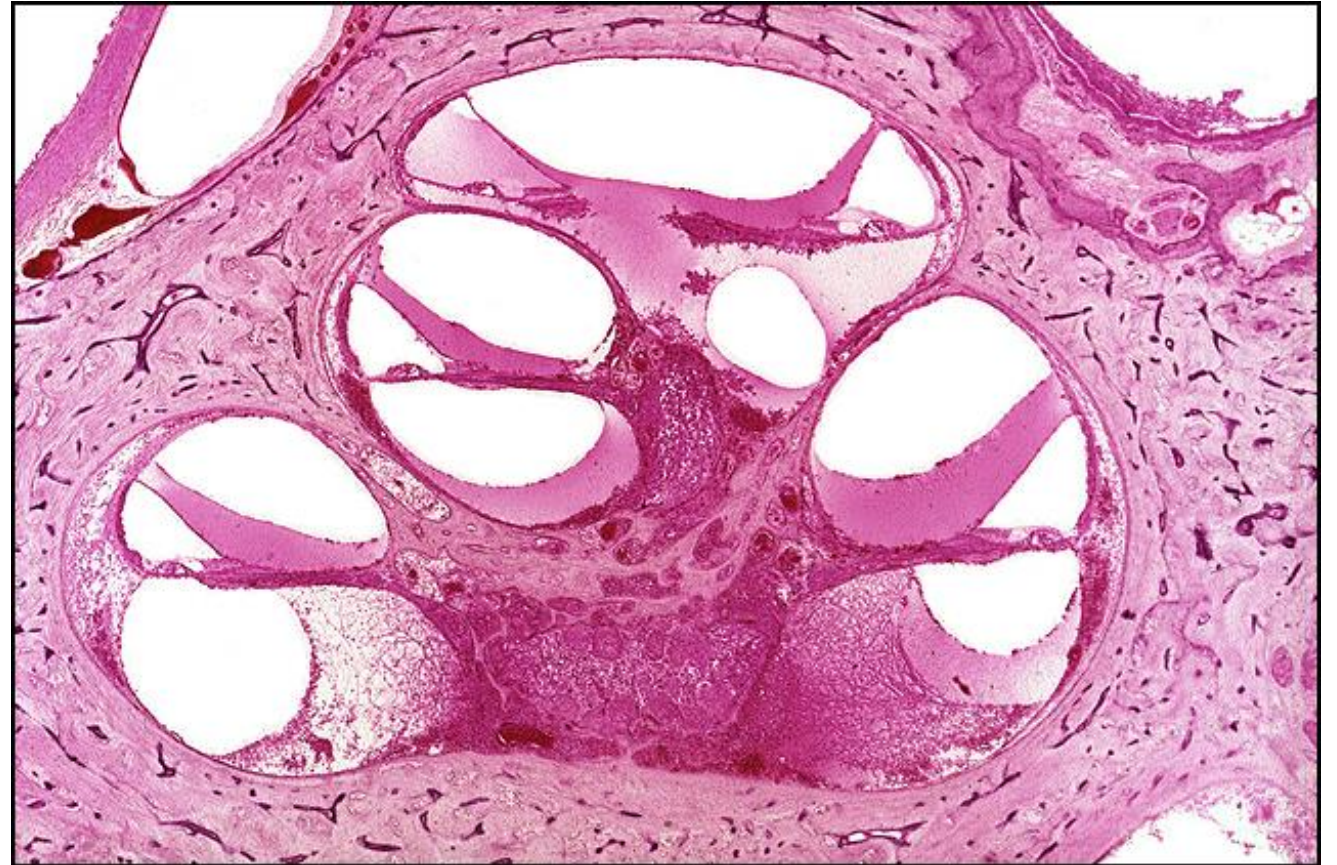TB Case Number: 236

Gender: Male

Age (yrs.): 39

Otologic Diagnosis:

1. Otosclerosis, clinical, small, left
2. Stapedectomy, partial, polyethylene tube prosthesis, 1959 (age 37), left
3. Fistula, perilymph, oval window, postoperative, left
4. Otitis media, suppurative, pneumococcal, left
5. Labyrinthitis, suppurative, pneumococcal, left
6. Meningitis, suppurative, pneumococcal



Stapedectomy, PE Tube, L-239

Title: Stapedectomy, PE Tube, L-239

Chapter: Surgical Pathology

Chapter Section: Polyethylene Tube, Stapedectomy, Surgery for Otosclerosis

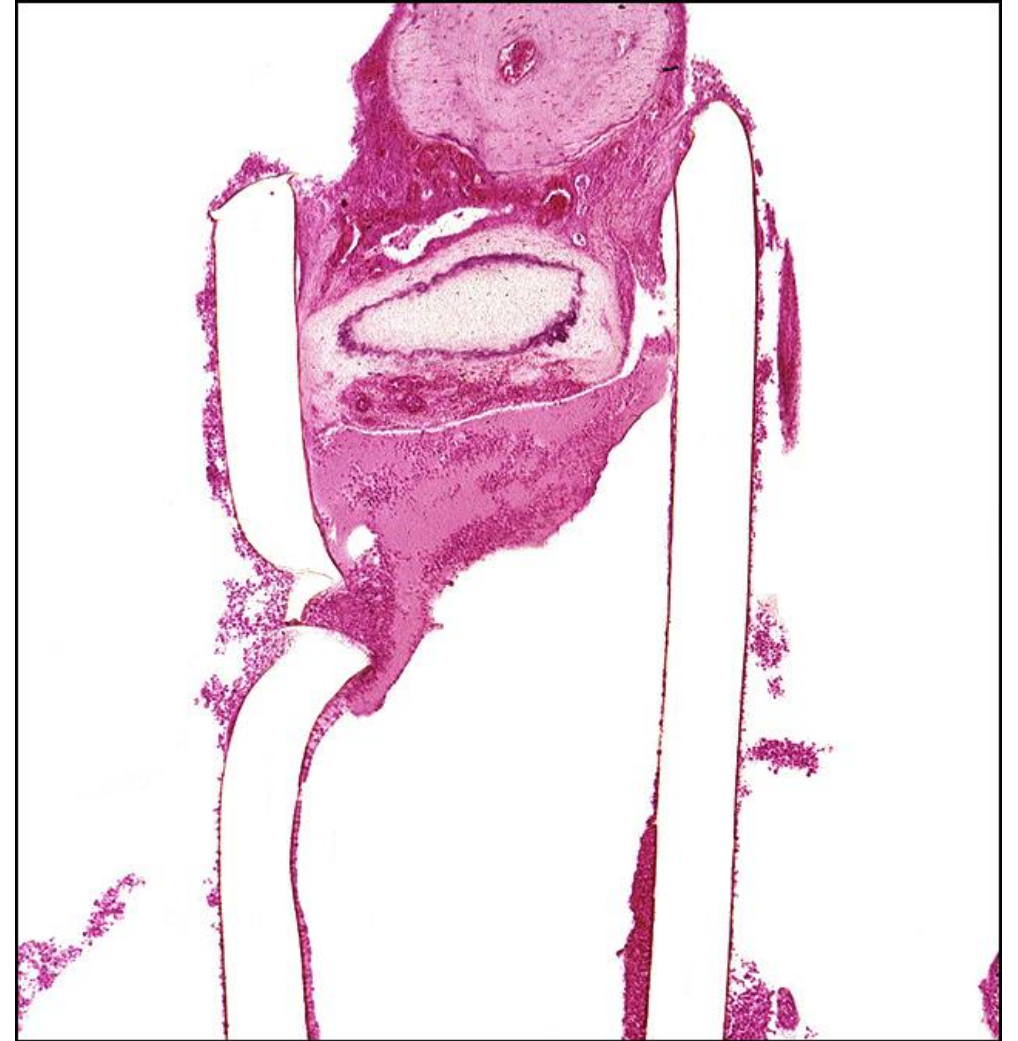TB Case Number: 236

Gender: Male

Age (yrs.): 39

Otologic Diagnosis:

1. Otosclerosis, clinical, small, left
2. Stapedectomy, partial, polyethylene tube prosthesis, 1959 (age 37), left
3. Fistula, perilymph, oval window, postoperative, left
4. Otitis media, suppurative, pneumococcal, left
5. Labyrinthitis, suppurative, pneumococcal, left
6. Meningitis, suppurative, pneumococcal



Stapedectomy, PE Tube, L-349

Title: Stapedectomy, PE Tube, L-349

Chapter: Surgical Pathology

Chapter Section: Polyethylene Tube, Stapedectomy, Surgery for Otosclerosis

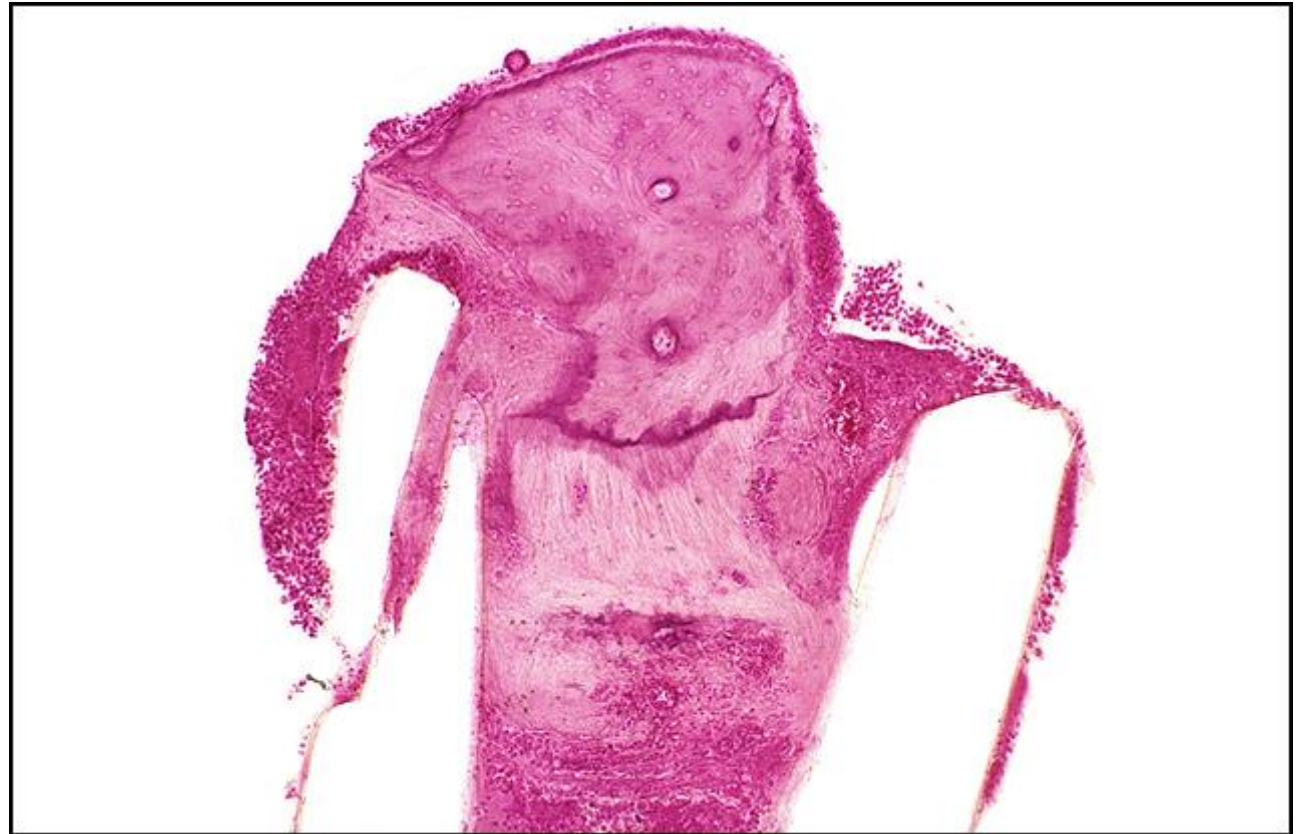TB Case Number: 236

Gender: Male

Age (yrs.): 39

Otologic Diagnosis:

1. Otosclerosis, clinical, small, left
2. Stapedectomy, partial, polyethylene tube prosthesis, 1959 (age 37), left
3. Fistula, perilymph, oval window, postoperative, left
4. Otitis media, suppurative, pneumococcal, left
5. Labyrinthitis, suppurative, pneumococcal, left
6. Meningitis, suppurative, pneumococcal



Stapedectomy, PE Tube, L-321

Title: Stapedectomy, PE Tube, L-321

Chapter: Surgical Pathology

Chapter Section: Polyethylene Tube, Stapedectomy, Surgery for Otosclerosis

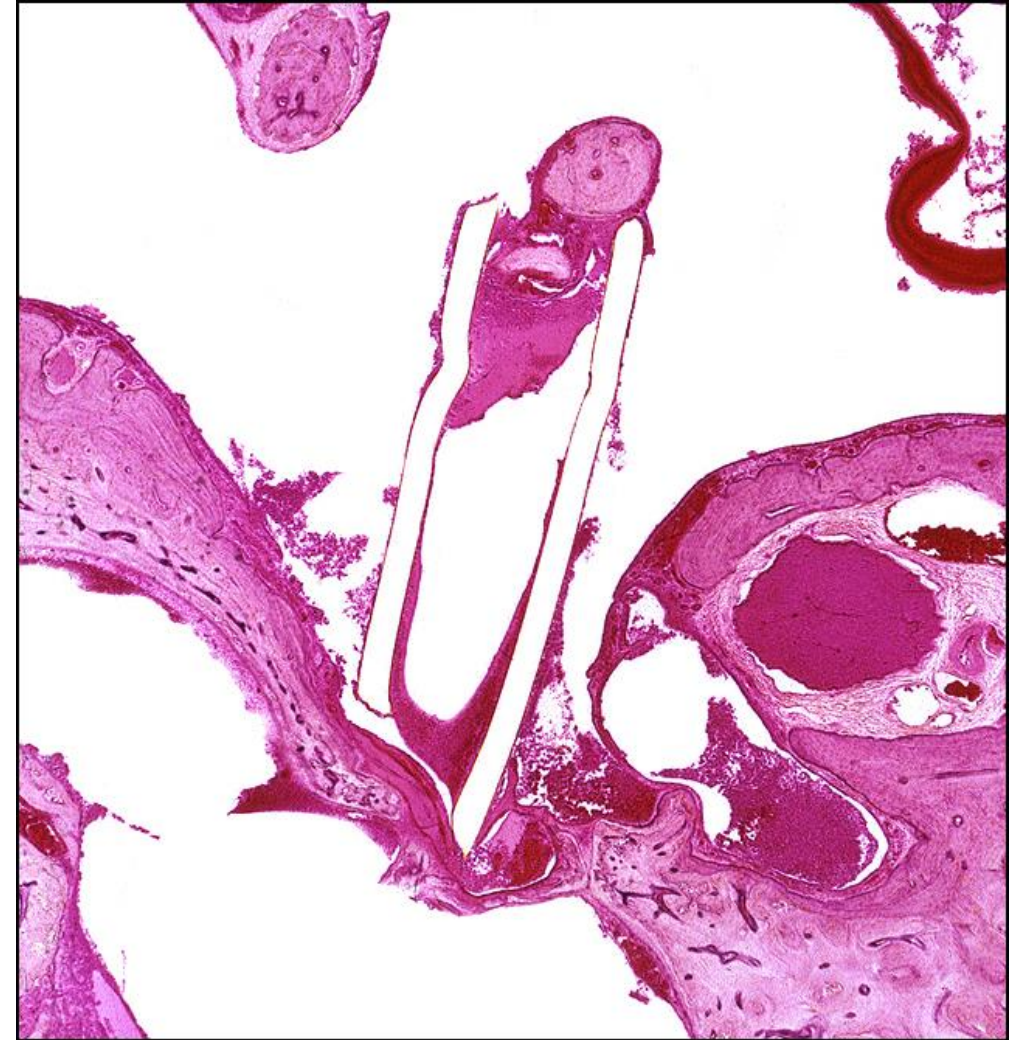
TB Case Number: 236

Gender: Male

Age (yrs.): 39

Otologic Diagnosis:

1. Otosclerosis, clinical, small, left
2. Stapedectomy, partial, polyethylene tube prosthesis, 1959 (age 37), left
3. Fistula, perilymph, oval window, postoperative, left
4. Otitis media, suppurative, pneumococcal, left
5. Labyrinthitis, suppurative, pneumococcal, left
6. Meningitis, suppurative, pneumococcal



Stapedectomy, PE Tube, L-299

Title: Stapedectomy, PE Tube, L-299

Chapter: Surgical Pathology

Chapter Section: Polyethylene Tube, Stapedectomy, Surgery for Otosclerosis

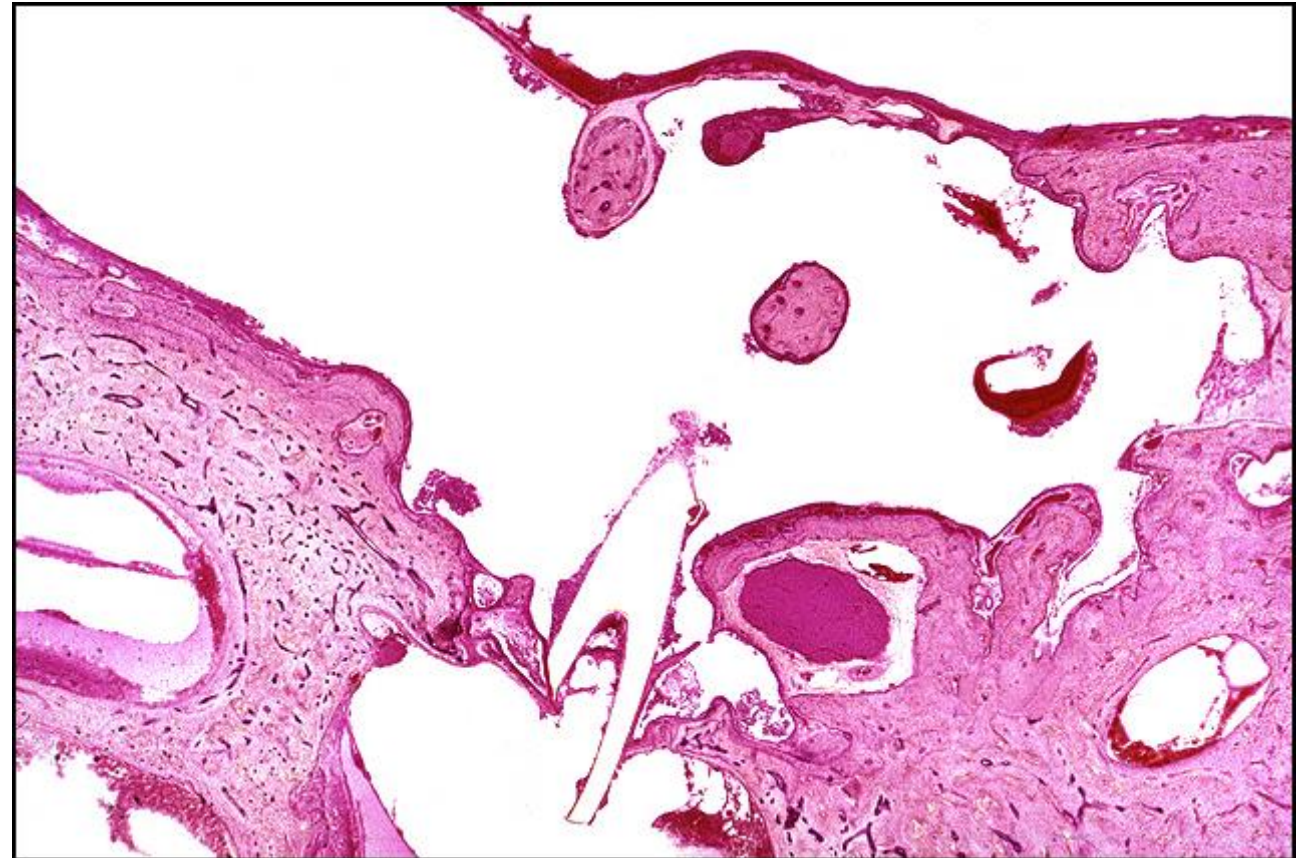
TB Case Number: 236

Gender: Male

Age (yrs.): 39

Otologic Diagnosis:

1. Otosclerosis, clinical, small, left
2. Stapedectomy, partial, polyethylene tube prosthesis, 1959 (age 37), left
3. Fistula, perilymph, oval window, postoperative, left
4. Otitis media, suppurative, pneumococcal, left
5. Labyrinthitis, suppurative, pneumococcal, left
6. Meningitis, suppurative, pneumococcal



PE Tube, L-321

Title: PE Tube, L-321

Chapter: Surgical Pathology

Chapter Section: Polyethylene Tube, Stapedectomy, Surgery for Otosclerosis

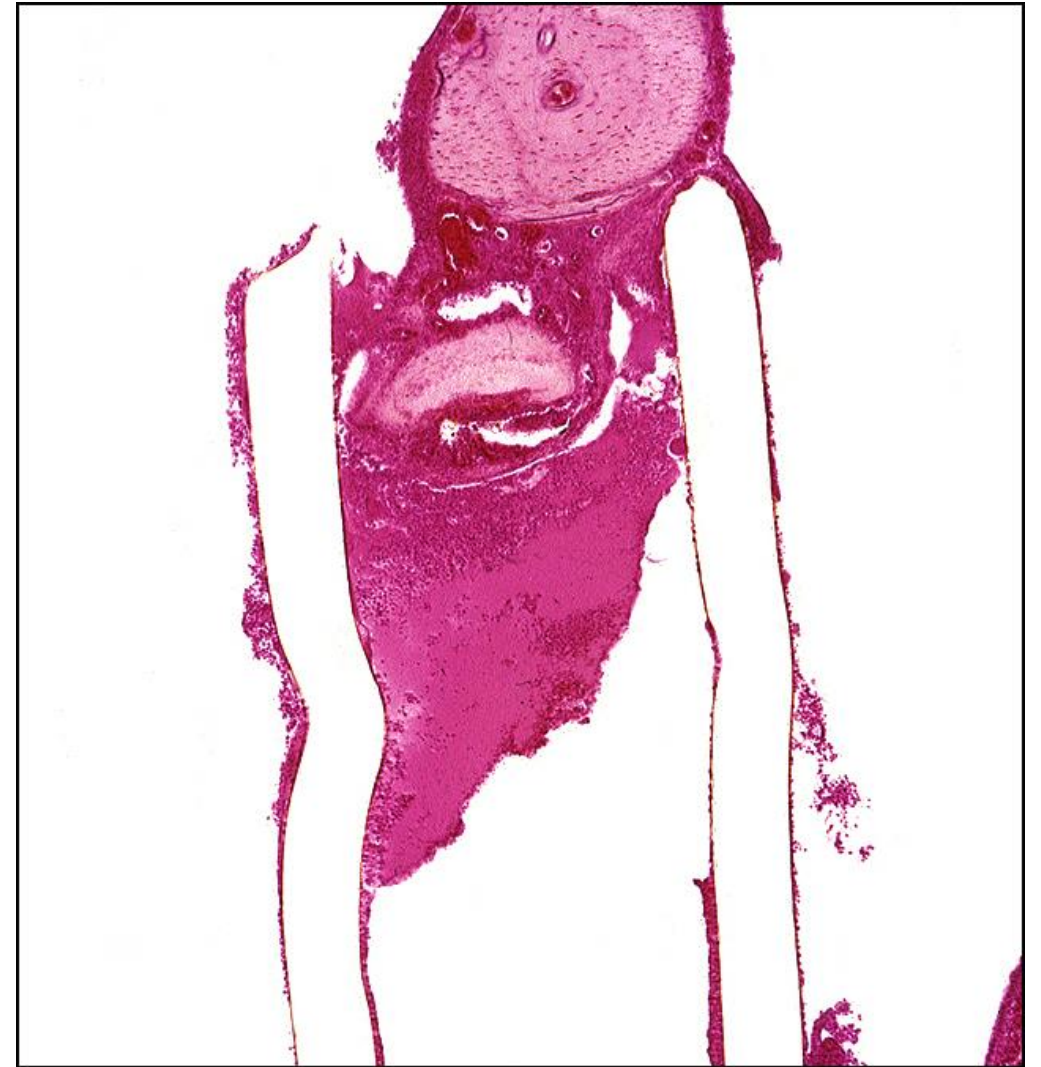
TB Case Number: 236

Gender: Male

Age (yrs.): 39

Otologic Diagnosis:

1. Otosclerosis, clinical, small, left
2. Stapedectomy, partial, polyethylene tube prosthesis, 1959 (age 37), left
3. Fistula, perilymph, oval window, postoperative, left
4. Otitis media, suppurative, pneumococcal, left
5. Labyrinthitis, suppurative, pneumococcal, left
6. Meningitis, suppurative, pneumococcal



PE Tube, L-289

Title: PE Tube, L-289

Chapter: Surgical Pathology

Chapter Section: Polyethylene Tube, Stapedectomy, Surgery for Otosclerosis

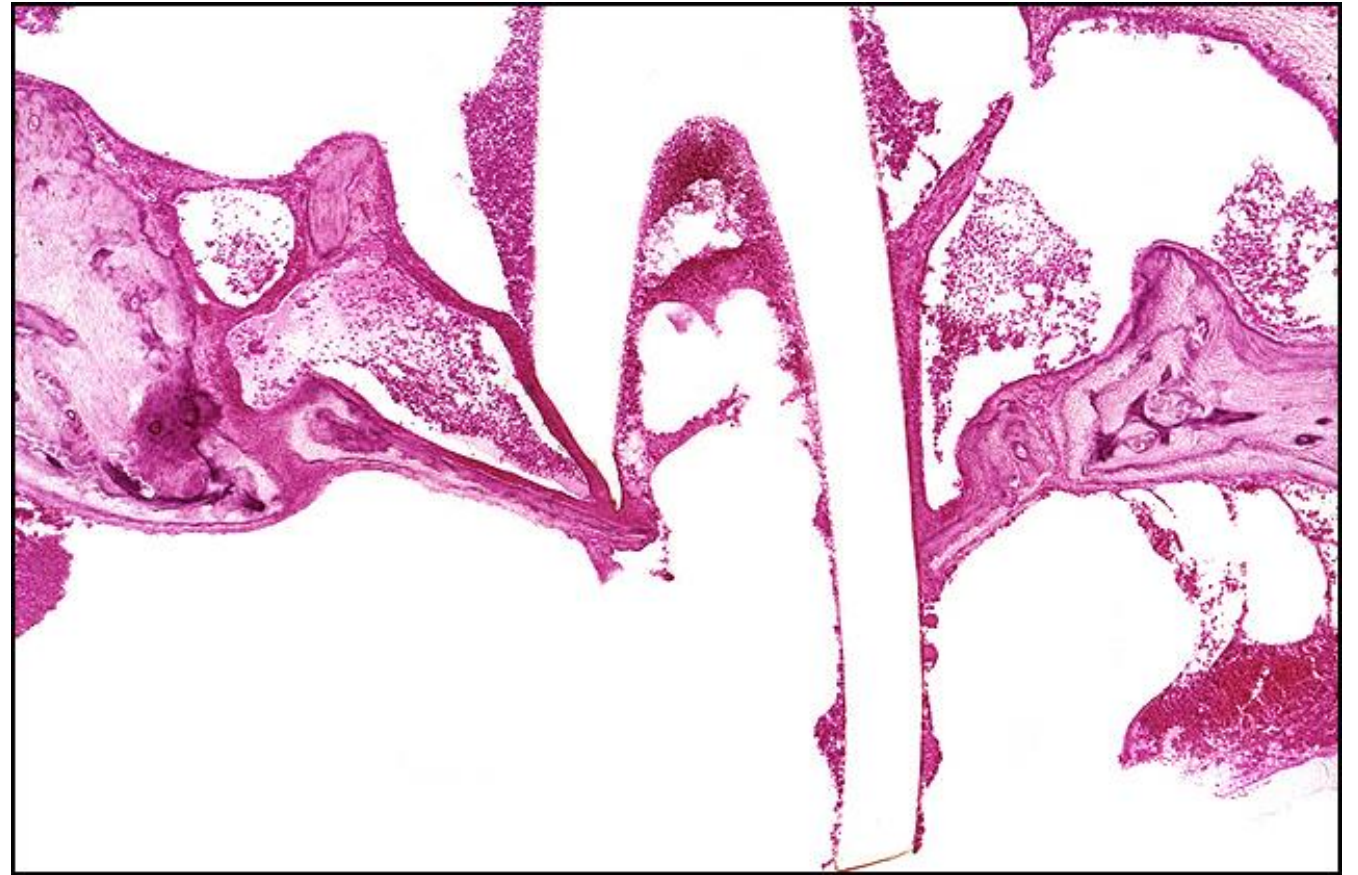
TB Case Number: 236

Gender: Male

Age (yrs.): 39

Otologic Diagnosis:

1. Otosclerosis, clinical, small, left
2. Stapedectomy, partial, polyethylene tube prosthesis, 1959 (age 37), left
3. Fistula, perilymph, oval window, postoperative, left
4. Otitis media, suppurative, pneumococcal, left
5. Labyrinthitis, suppurative, pneumococcal, left
6. Meningitis, suppurative, pneumococcal



Stapedectomy, Tef-wire Piston

Title: Stapedectomy, Tef-wire Piston

Chapter: Surgical Pathology

Chapter Section: Stapedectomy, Surgery for Otosclerosis, Wire and Teflon

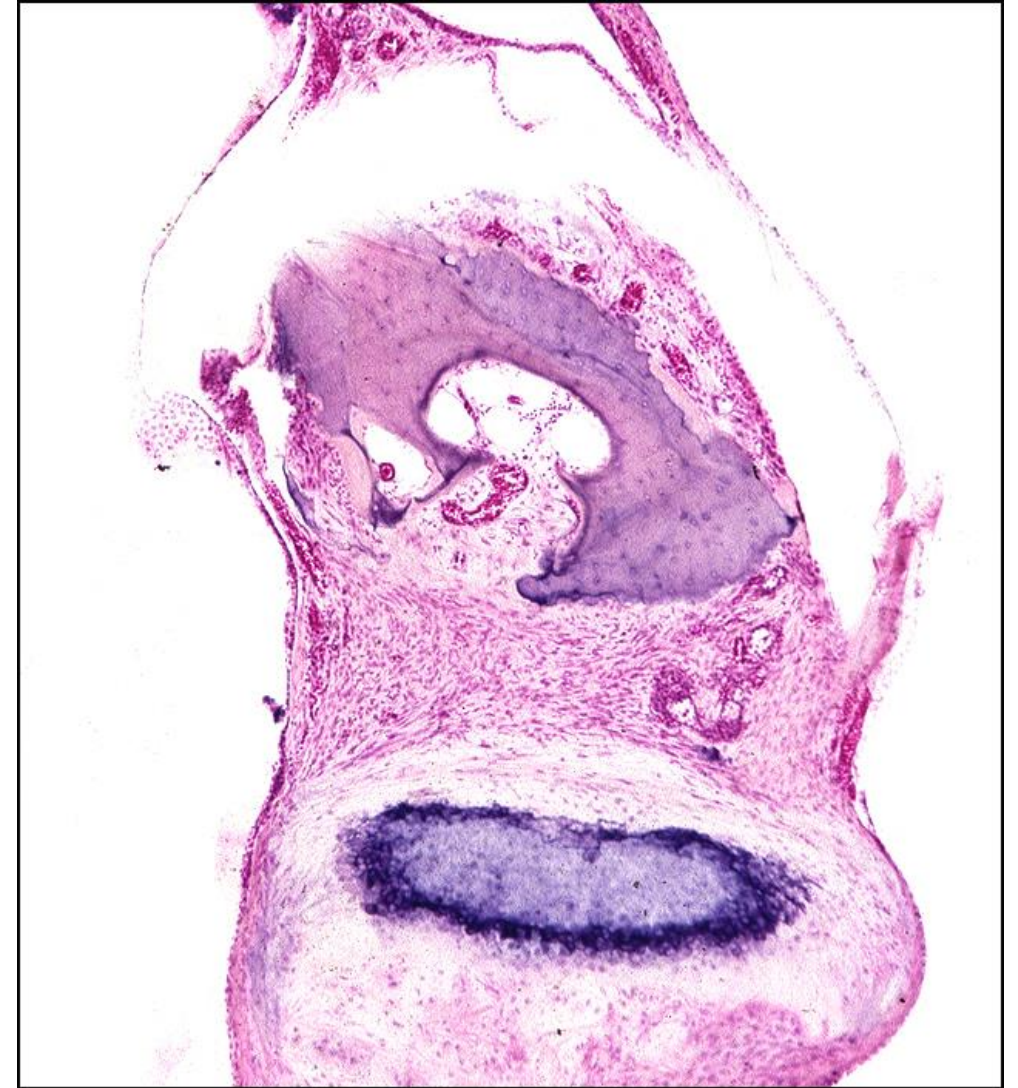
TB Case Number: 122

Gender: Male

Age (yrs.): 61

Otologic Diagnosis:

1. Otosclerosis, clinical, bilateral
2. Stapedotomy, Teflon-wire piston, successful, left
3. Tympanic membrane, surgical trauma, left
4. Incus, erosion, moderate, Tef-wire piston, left
5. Exostoses, external auditory canal, small, bilateral
6. Dimeric membrane, surgical trauma, left
7. Endolymphatic hydrops, apical, physiological
8. Artifacts, preparation, membranous labyrinth, right



Stapedectomy, Tef-wire Piston, L-322

Title: Stapedectomy, Tef-wire Piston, L-322

Chapter: Surgical Pathology

Chapter Section: Stapedectomy, Surgery for Otosclerosis, Wire and Teflon

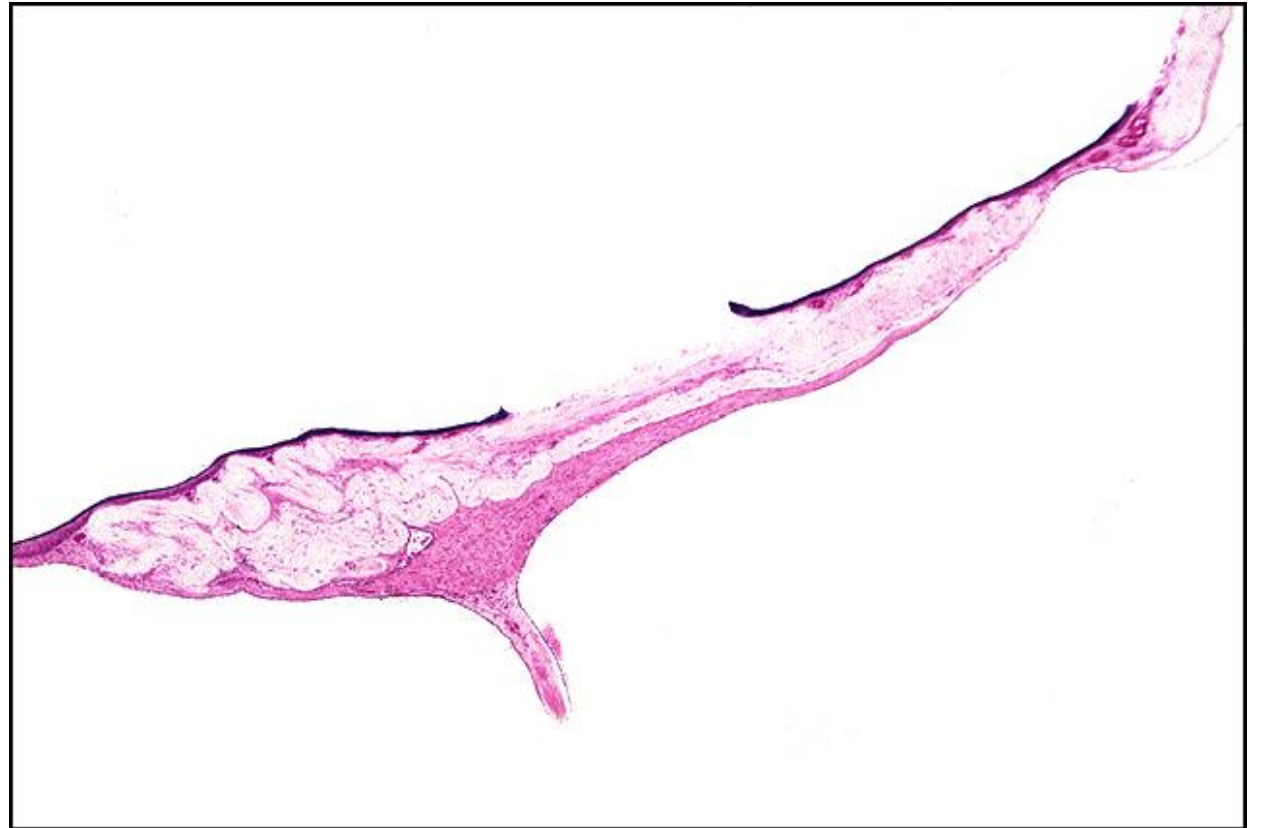TB Case Number: 122

Gender: Male

Age (yrs.): 61

Otologic Diagnosis:

1. Otosclerosis, clinical, bilateral
2. Stapedotomy, Teflon-wire piston, successful, left
3. Tympanic membrane, surgical trauma, left
4. Incus, erosion, moderate, Tef-wire piston, left
5. Exostoses, external auditory canal, small, bilateral
6. Dimeric membrane, surgical trauma, left
7. Endolymphatic hydrops, apical, physiological
8. Artifacts, preparation, membranous labyrinth, right



Otosclerosis, Stapedectomy, Gel-wire Piston, R-172

Title: Otosclerosis, Stapedectomy, Gel-wire Piston, R-172

Chapter: Surgical Pathology

Chapter Section: Gelfoam and Wire, Stapedectomy, Surgery for Otosclerosis

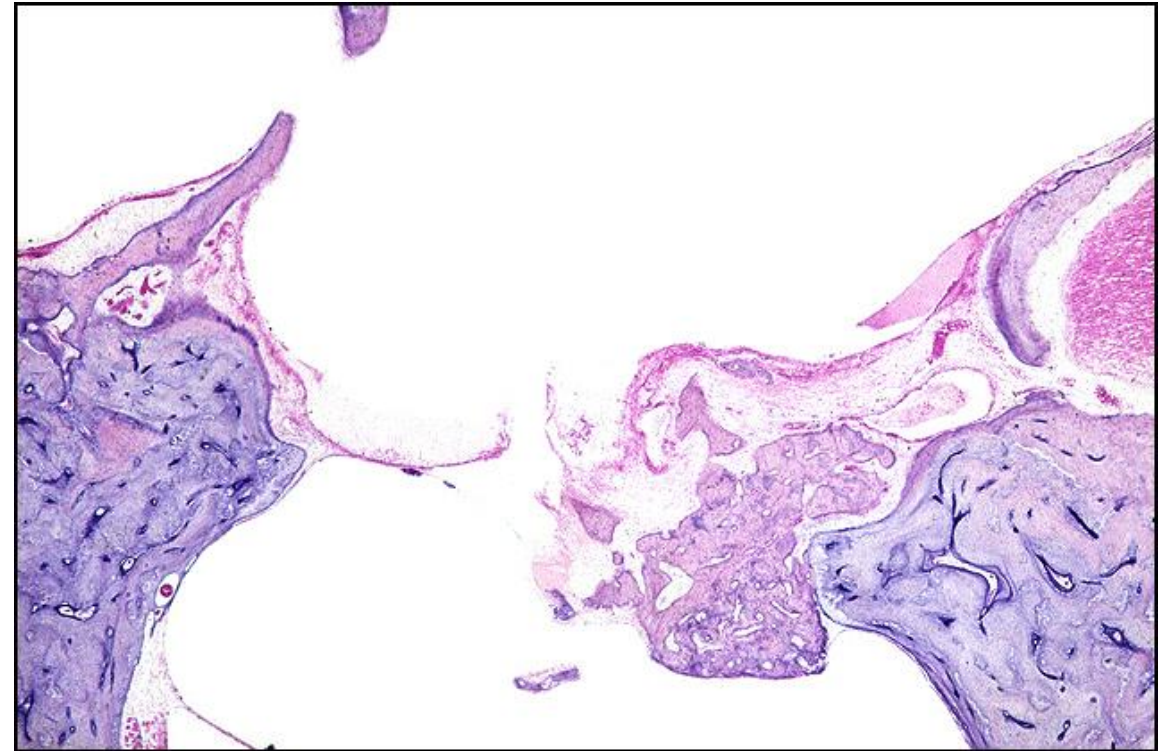
TB Case Number: 245

Gender: Male

Age (yrs.): 70

Otologic Diagnosis:

1. Otosclerosis, clinical, moderate, bilateral
2. Stapedectomy, gel-wire prosthesis (16 years), right
3. Stapes, total surgical removal, right
4. Osteoneogenesis, oval window, postoperative, right
5. Tympanic membrane, surgical trauma, stapedectomy, right
6. Stapes fixation, otosclerosis, left
7. Organ of Corti, normal, bilateral
8. Exostosis, external auditory canal, bilateral
9. Artifact, preparation, tears, membranous labyrinth, bilateral
10. Artifact, postmortem, moderate on right, mild on left



Stapedectomy, Gel-wire Piston, R-156

Title: Stapedectomy, Gel-wire Piston, R-156

Chapter: Surgical Pathology

Chapter Section: Gelfoam and Wire, Stapedectomy, Surgery for Otosclerosis

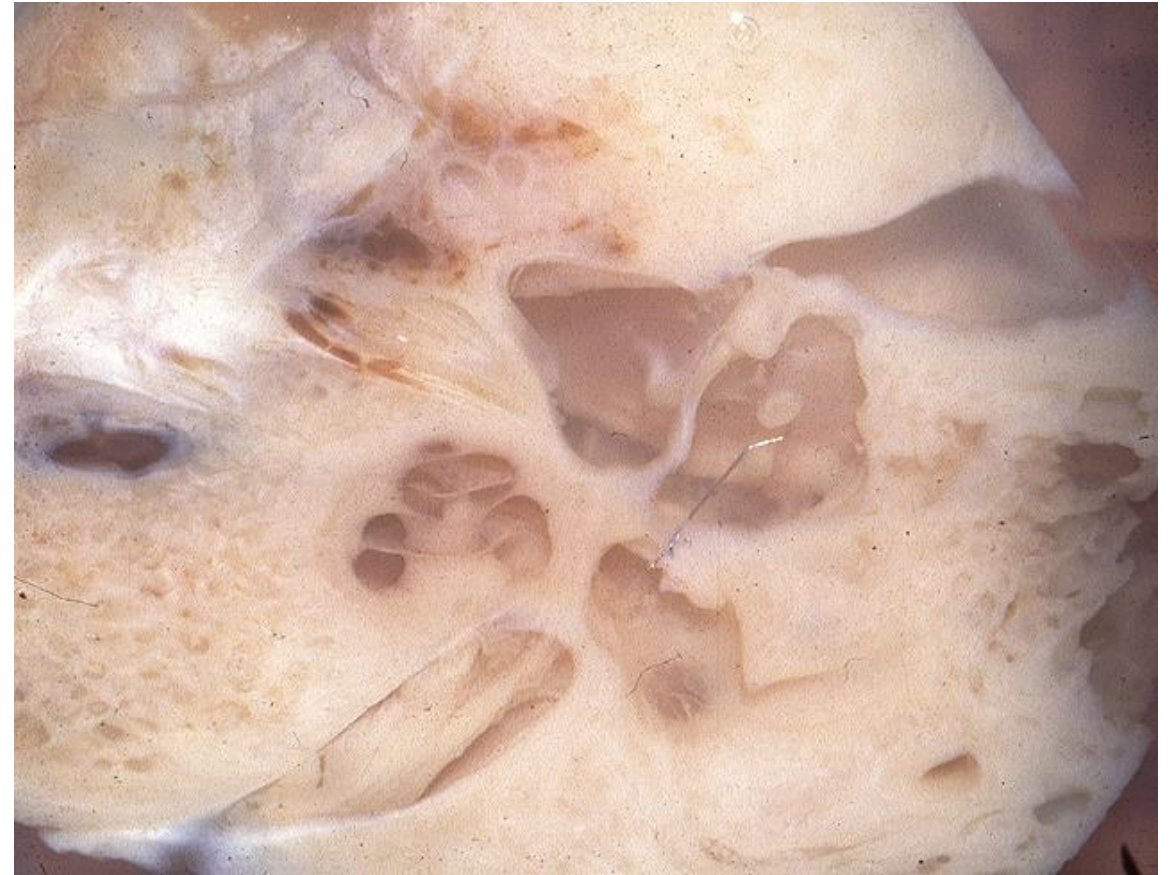TB Case Number: 245

Gender: Male

Age (yrs.): 70

Otologic Diagnosis:

1. Otosclerosis, clinical, moderate, bilateral
2. Stapedectomy, gel-wire prosthesis (16 years), right
3. Stapes, total surgical removal, right
4. Osteoneogenesis, oval window, postoperative, right
5. Tympanic membrane, surgical trauma, stapedectomy, right
6. Stapes fixation, otosclerosis, left
7. Organ of Corti, normal, bilateral
8. Exostosis, external auditory canal, bilateral
9. Artifact, preparation, tears, membranous labyrinth, bilateral
10. Artifact, postmortem, moderate on right, mild on left



Stapes, Tef-wire, L-196

Title: Stapes, Tef-wire, L-196

Chapter: Surgical Pathology

Chapter Section: Stapedectomy, Surgery for Otosclerosis, Wire and Teflon

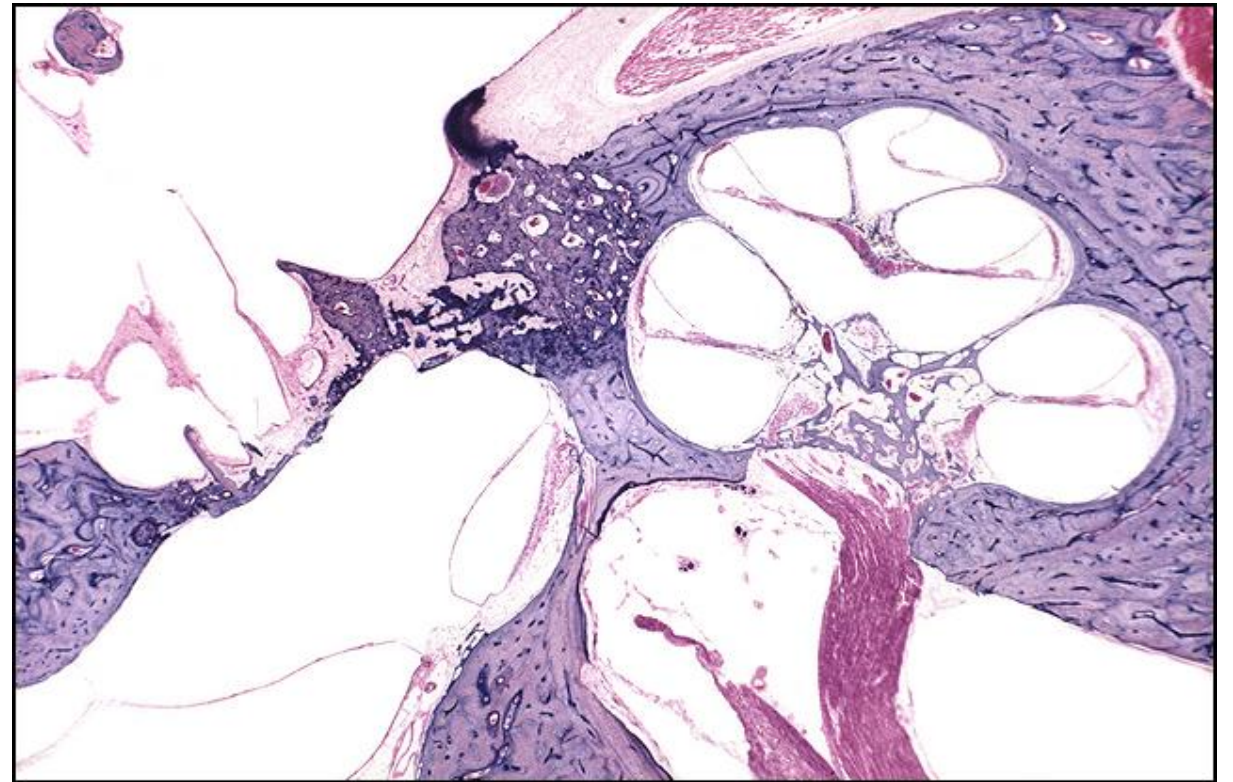
TB Case Number: 116

Gender: Female

Age (yrs.): 69

Otologic Diagnosis:

1. Otosclerosis, with stapes fixation, bilateral
2. Otosclerosis, round window, mild, bilateral
3. Stapedotomy, partial, with implantation of Teflon-wire piston, left
4. Tympanic membrane, surgical trauma, stapedotomy, left
5. Chorda tympani nerve, surgical trauma, stapedotomy, left
6. Presbycusis, cochlear conductive, otosclerosis
7. Cochlear duct, normal
8. Vestibular sense organs, normal



Stapes, Tef-wire, L-196

Title: Stapes, Tef-wire, L-196

Chapter: Surgical Pathology

Chapter Section: Stapedectomy, Surgery for Otosclerosis,
Wire and Teflon

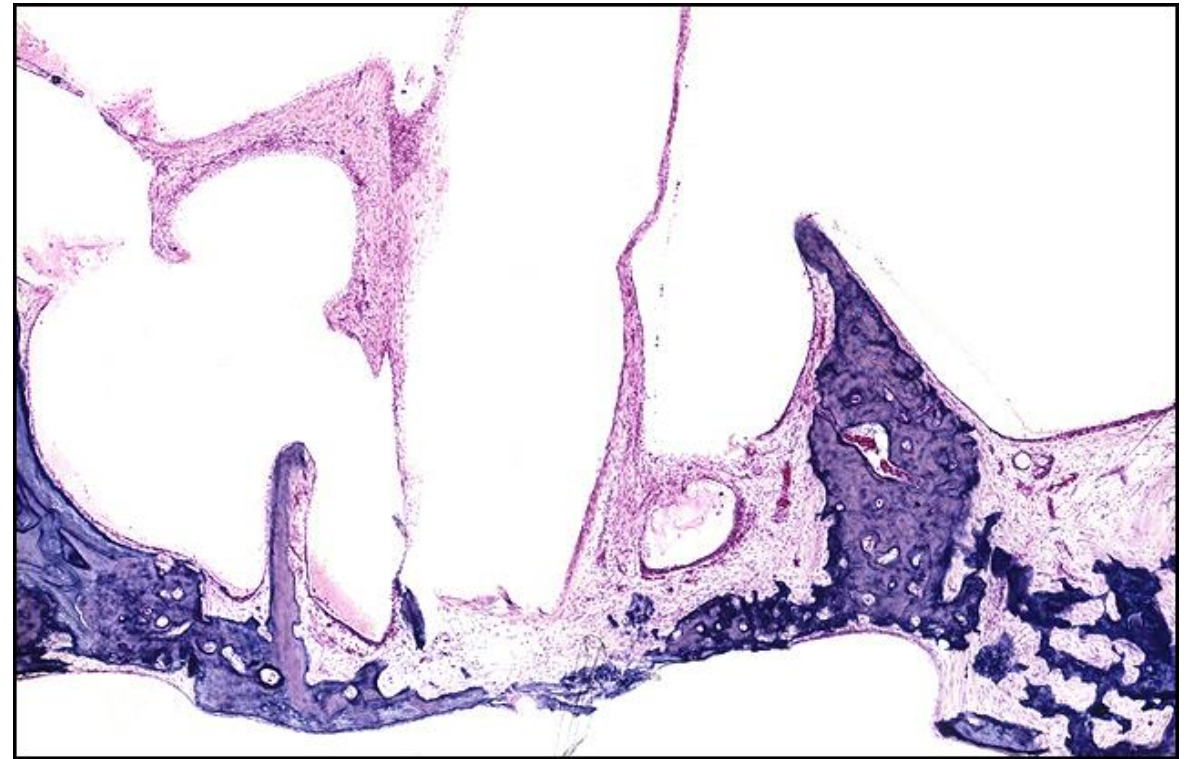
TB Case Number: 116

Gender: Female

Age (yrs.): 69

Otologic Diagnosis:

1. Otosclerosis, with stapes fixation, bilateral
2. Otosclerosis, round window, mild, bilateral
3. Stapedotomy, partial, with implantation of Teflon-wire piston, left
4. Tympanic membrane, surgical trauma, stapedotomy, left
5. Chorda tympani nerve, surgical trauma, stapedotomy, left
6. Presbycusis, cochlear conductive, otosclerosis
7. Cochlear duct, normal
8. Vestibular sense organs, normal



Stapes, Tef-wire, L-196

Title: Stapes, Tef-wire, L-196

Chapter: Surgical Pathology

Chapter Section: Stapedectomy, Surgery for Otosclerosis, Wire and Teflon

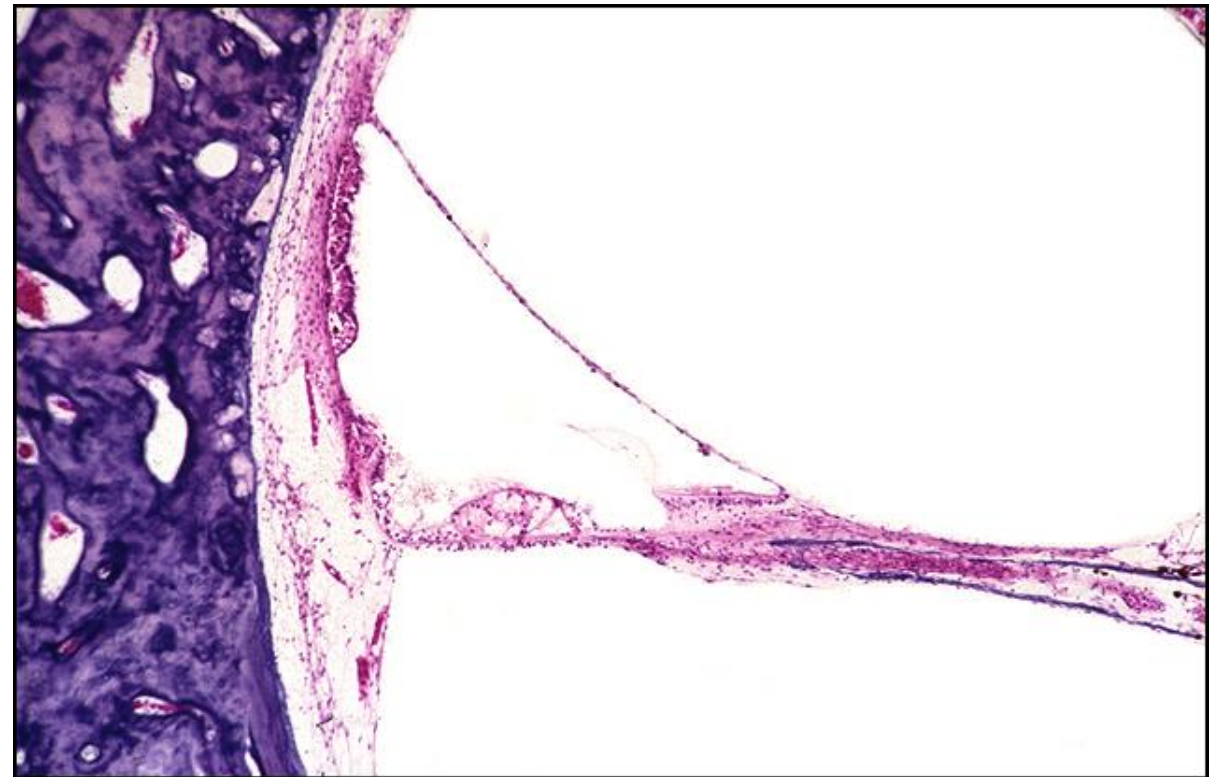
TB Case Number: 116

Gender: Female

Age (yrs.): 69

Otologic Diagnosis:

1. Otosclerosis, with stapes fixation, bilateral
2. Otosclerosis, round window, mild, bilateral
3. Stapedotomy, partial, with implantation of Teflon-wire piston, left
4. Tympanic membrane, surgical trauma, stapedotomy, left
5. Chorda tympani nerve, surgical trauma, stapedotomy, left
6. Presbycusis, cochlear conductive, otosclerosis
7. Cochlear duct, normal
8. Vestibular sense organs, normal



Stapes, Tef-wire piston, L-186

Title: Stapes, Tef-wire Piston, L-186

Chapter: Surgical Pathology

Chapter Section: Stapedectomy, Surgery for Otosclerosis, Wire and Teflon

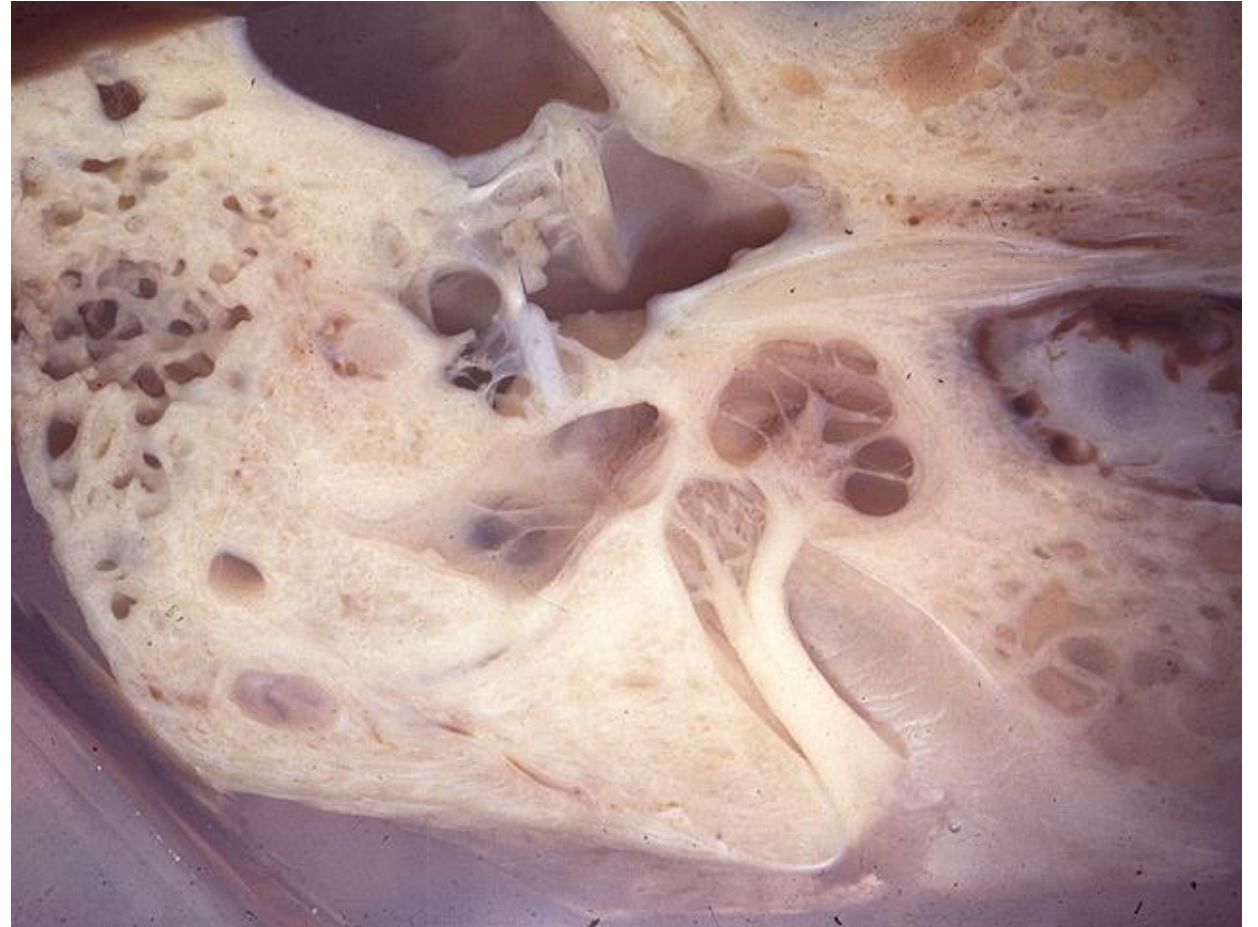TB Case Number: 116

Gender: Female

Age (yrs.): 69

Otologic Diagnosis:

1. Otosclerosis, with stapes fixation, bilateral
2. Otosclerosis, round window, mild, bilateral
3. Stapedotomy, partial, with implantation of Teflon-wire piston, left
4. Tympanic membrane, surgical trauma, stapedotomy, left
5. Chorda tympani nerve, surgical trauma, stapedotomy, left
6. Presbycusis, cochlear conductive, otosclerosis
7. Cochlear duct, normal
8. Vestibular sense organs, normal



Stapedectomy, Tef-wire Piston, L-240

Title: Stapedectomy, Tef-wire Piston, L-240

Chapter: Surgical Pathology

Chapter Section: Stapedectomy, Surgery for Otosclerosis, Wire and Teflon

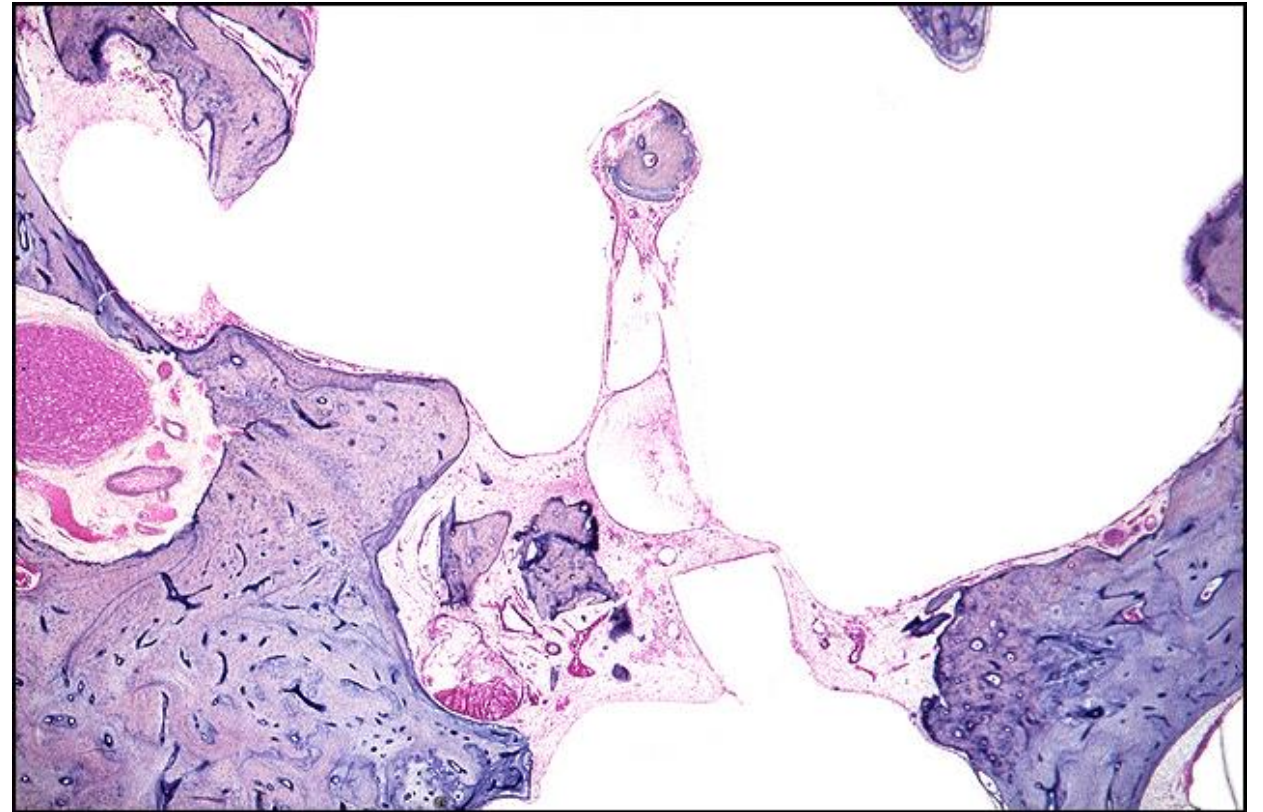
TB Case Number: 366

Gender: Female

Age (yrs.): 74

Otologic Diagnosis:

1. Otosclerosis, bilateral
2. Stapedectomy, Teflon-wire implant, 16 years postoperative, left
3. Chorda tympani nerve, postoperative degeneration, left
4. Occult schwannoma, small, left
5. Arachnoid cyst, small, left



Stapedectomy, PE Tube, R-241

Title: Stapedectomy, PE Tube, R-241

Chapter: Surgical Pathology

Chapter Section: Polyethylene Tube, Stapedectomy, Surgery for Otosclerosis

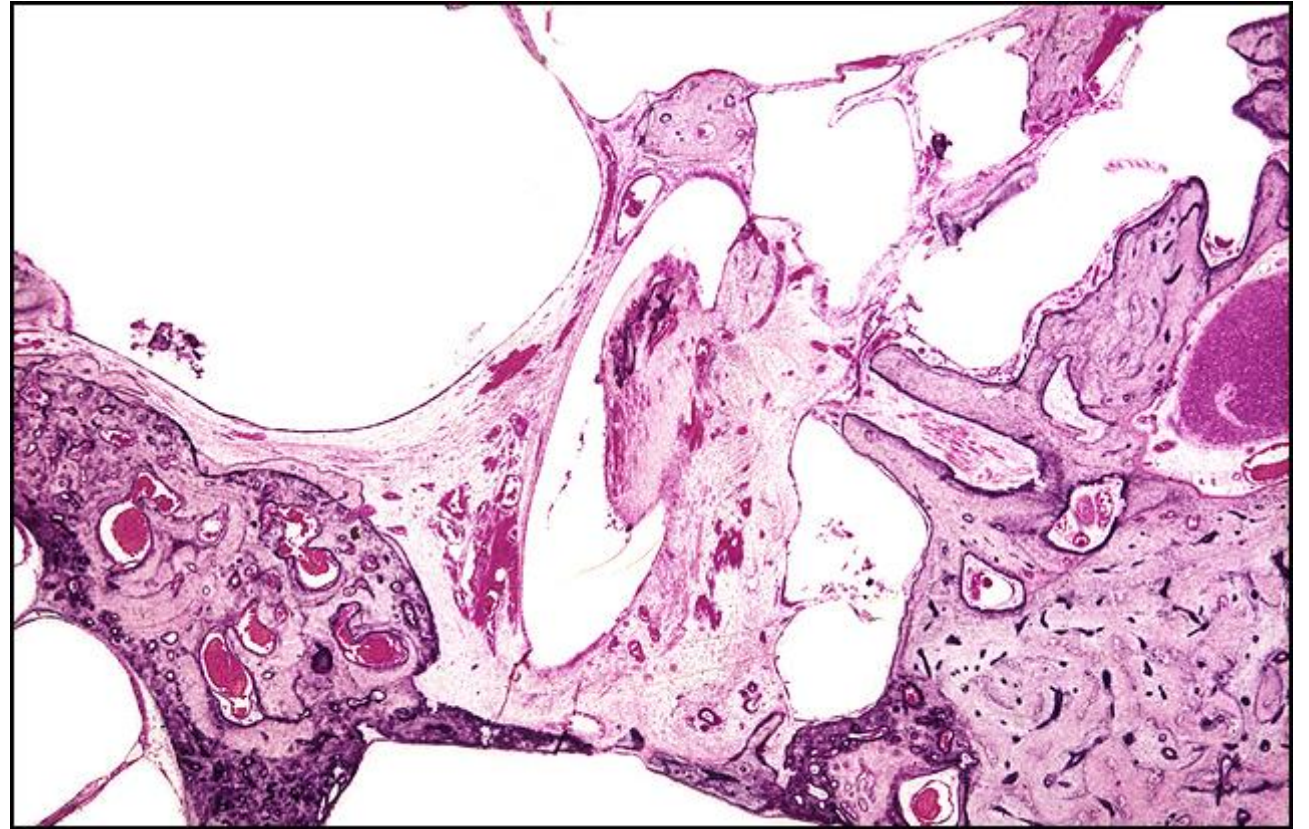
TB Case Number: 375

Gender: Male

Age (yrs.): 80

Otologic Diagnosis:

1. Otosclerosis, bilateral
2. Stapedectomies, bilateral
3. Rupture of cochlear ducts, bilateral
4. Osseous obliteration, perilymphatic space, posterior semicircular canal



Stapedectomy, PE Tube, R-231

Title: Stapedectomy, PE Tube, R-231

Chapter: Surgical Pathology

Chapter Section: Polyethylene Tube, Stapedectomy, Surgery for Otosclerosis

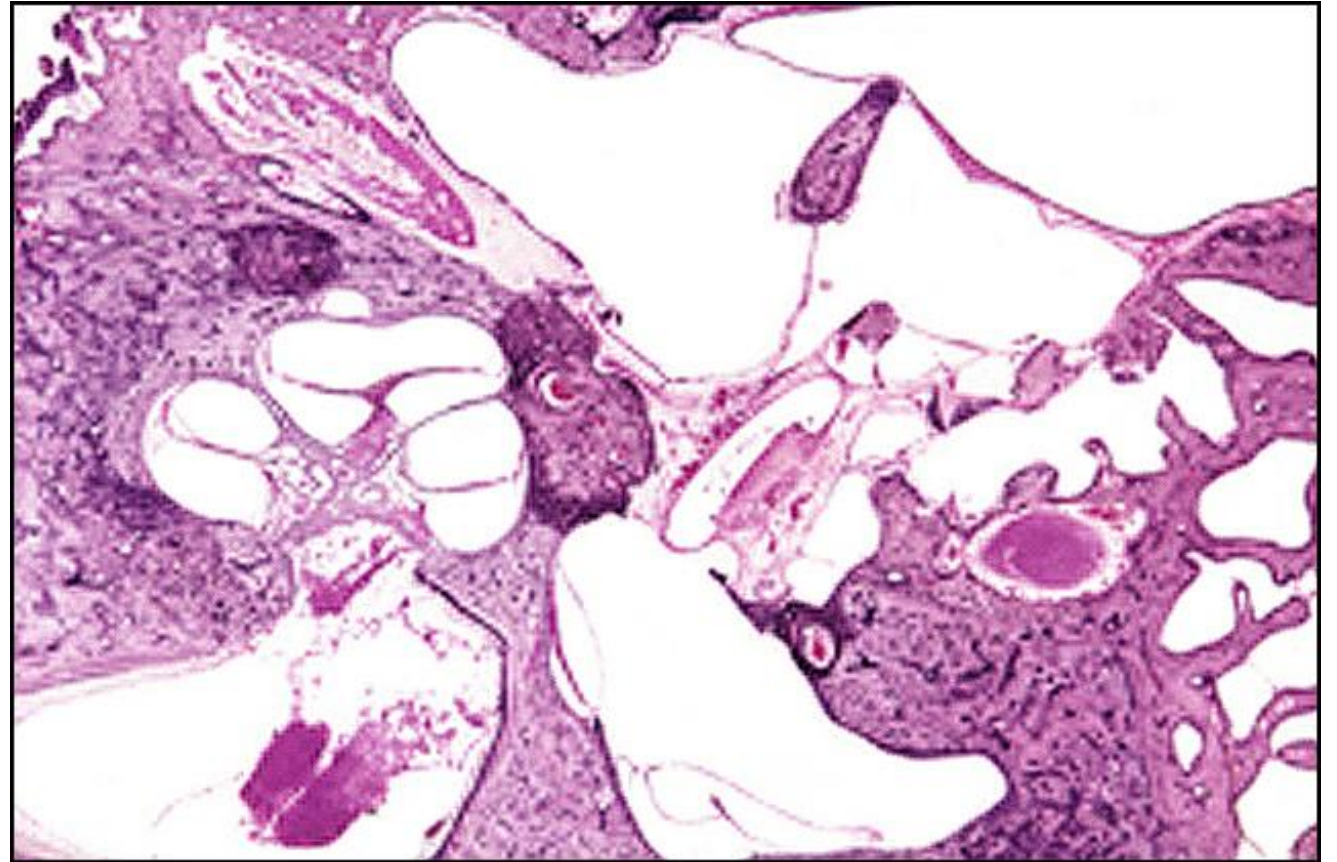
TB Case Number: 375

Gender: Male

Age (yrs.): 80

Otologic Diagnosis:

1. Otosclerosis, bilateral
2. Stapedectomies, bilateral
3. Rupture of cochlear ducts, bilateral
4. Osseous obliteration, perilymphatic space, posterior semicircular canal



Stapedectomy, PE Tube, R-231

Title: Stapedectomy, PE Tube, R-231

Chapter: Surgical Pathology

Chapter Section: Polyethylene Tube, Stapedectomy, Surgery for Otosclerosis

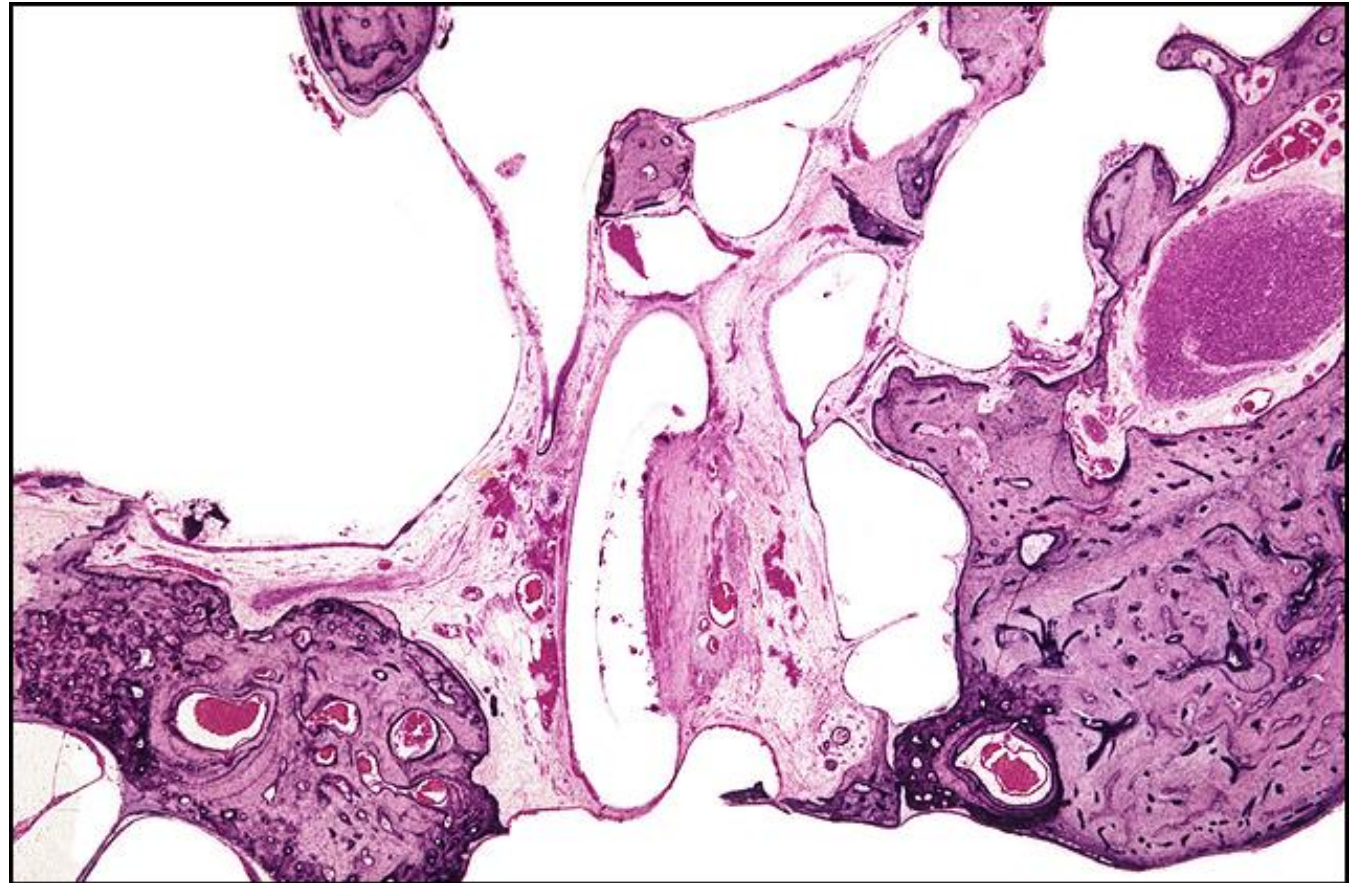TB Case Number: 375

Gender: Male

Age (yrs.): 80

Otologic Diagnosis:

1. Otosclerosis, bilateral
2. Stapedectomies, bilateral
3. Rupture of cochlear ducts, bilateral
4. Osseous obliteration, perilymphatic space, posterior semicircular canal



Stapedectomy, PE Tube, R-262

Title: Stapedectomy, PE Tube, R-262

Chapter: Surgical Pathology

Chapter Section: Polyethylene Tube,
Stapedectomy, Surgery for Otosclerosis

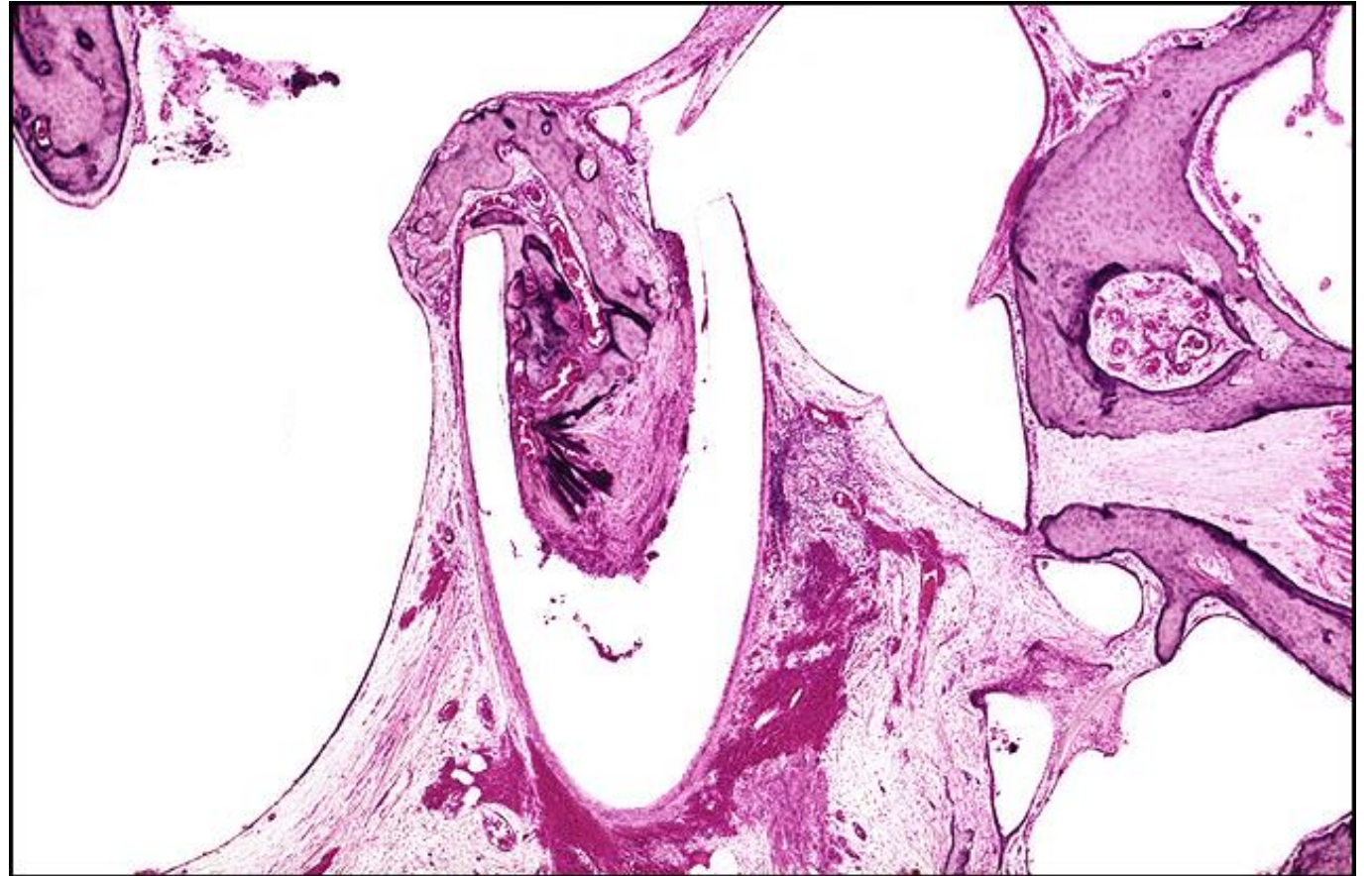
TB Case Number: 375

Gender: Male

Age (yrs.): 80

Otologic Diagnosis:

1. Otosclerosis, bilateral
2. Stapedectomies, bilateral
3. Rupture of cochlear ducts, bilateral
4. Osseous obliteration, perilymphatic space, posterior semicircular canal



Stapedectomy, Vein Wire Piston, L-241

Title: Stapedectomy, Vein Wire Piston, L-241

Chapter: Surgical Pathology

Chapter Section: Polyethylene Tube, Stapedectomy, Surgery for Otosclerosis

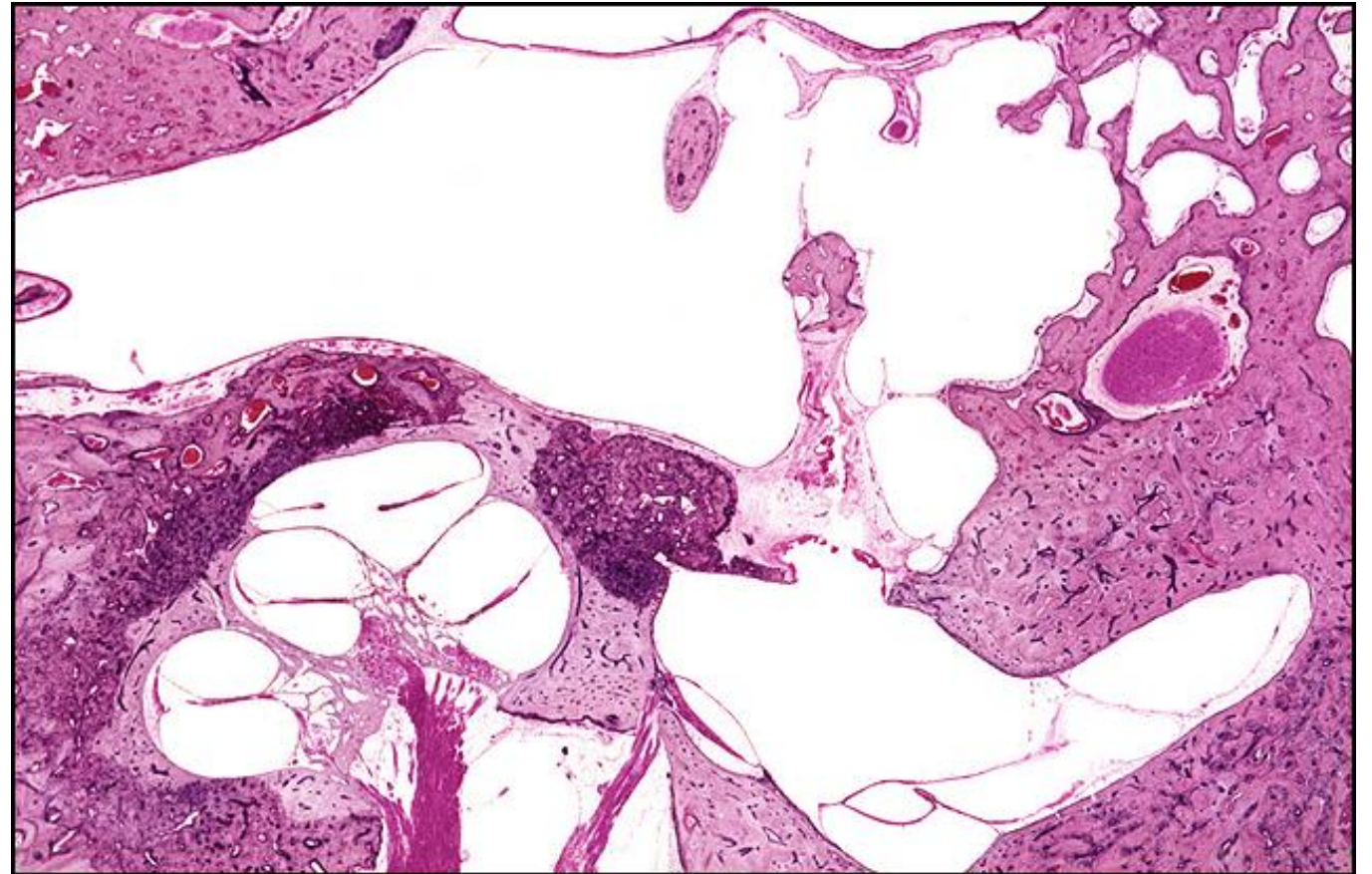
TB Case Number: 375

Gender: Male

Age (yrs.): 80

Otologic Diagnosis:

1. Otosclerosis, bilateral
2. Stapedectomies, bilateral
3. Rupture of cochlear ducts, bilateral
4. Osseous obliteration, perilymphatic space, posterior semicircular canal



Stapedectomy, Vein Wire Piston, L-181

Title: Stapedectomy, Vein Wire Piston, L-181

Chapter: Surgical Pathology

Chapter Section: Polyethylene Tube,
Stapedectomy, Surgery for Otosclerosis

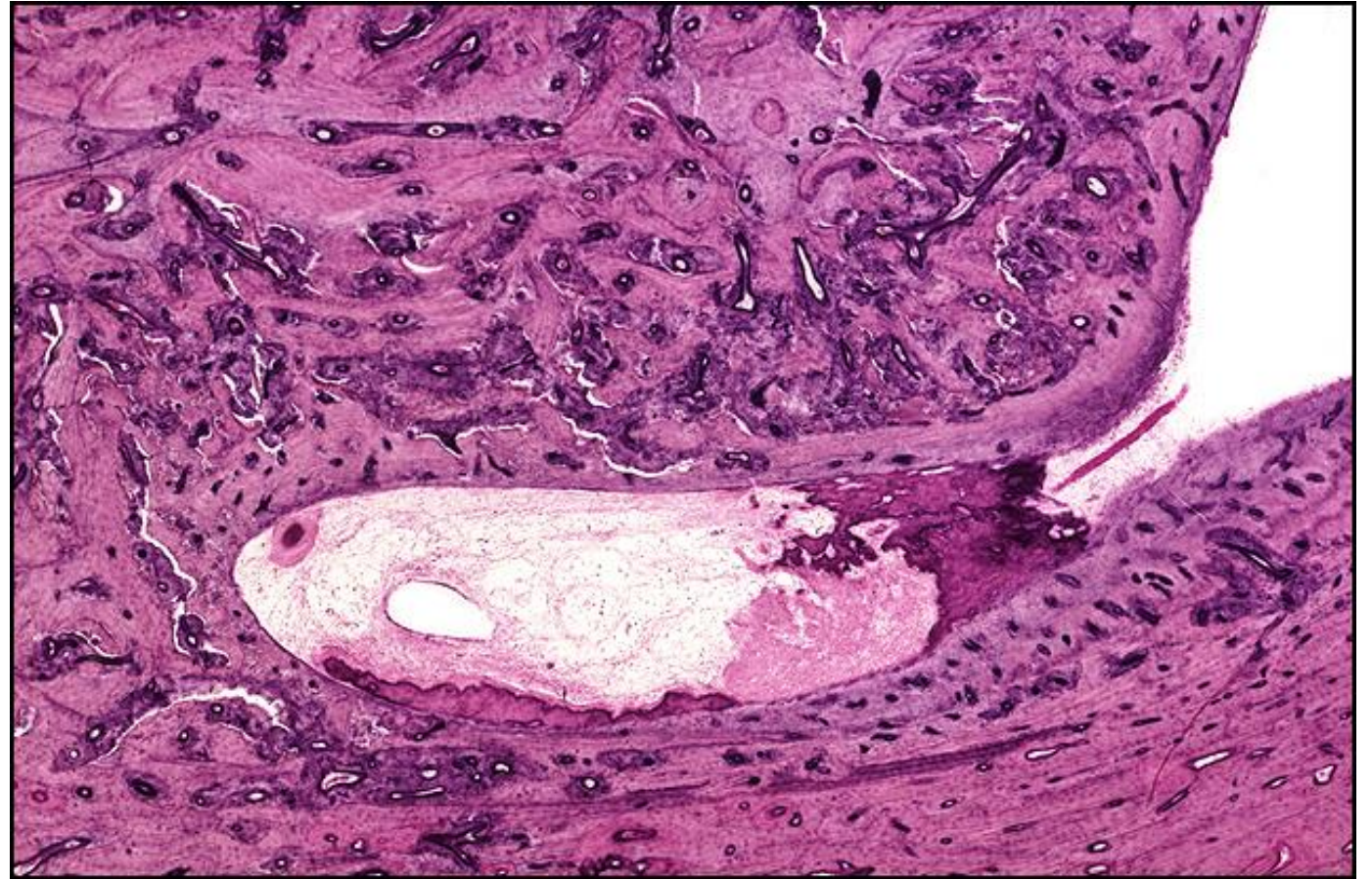
TB Case Number: 375

Gender: Male

Age (yrs.): 80

Otologic Diagnosis:

1. Otosclerosis, bilateral
2. Stapedectomies, bilateral
3. Rupture of cochlear ducts, bilateral
4. Osseous obliteration, perilymphatic space, posterior semicircular canal



Stapedectomy in Fenestrated Ear, R-190

Title: Stapedectomy in Fenestrated Ear, R-190

Chapter: Surgical Pathology

Chapter Section: Stapedectomy and Stapes Mobilization, Surgery for Otosclerosis

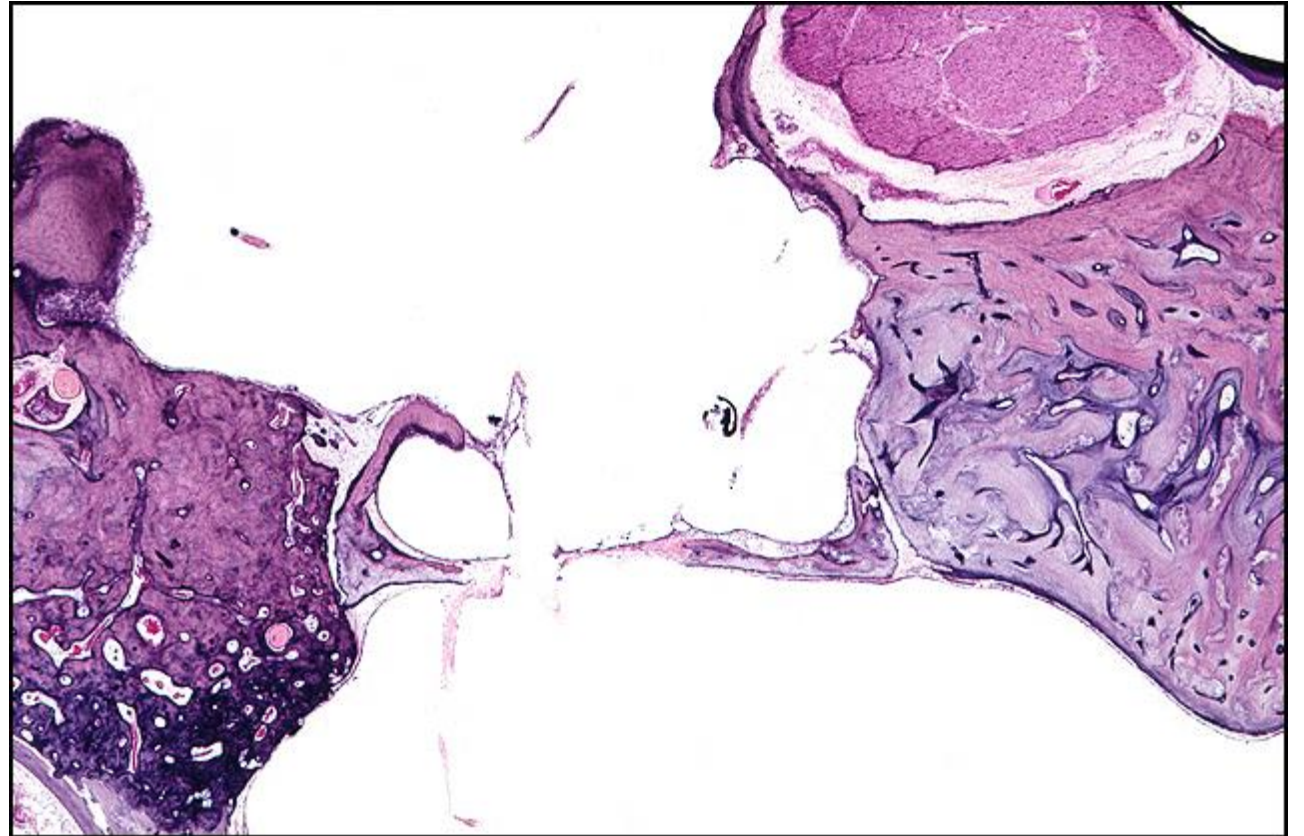
TB Case Number: 892

Gender: Female

Age (yrs.): 87

Otologic Diagnosis:

1. Otosclerosis, clinical, mild, bilateral
2. Fenestration, nov ovalis, lateral canal, unsuccessful, age 37, right
3. Fenestration, bony obliteration, right
4. Stapedotomy, Tef-wire piston, age 64, fenestrated ear, right
5. Stapes mobilization, successful, age 51, left
6. Cholesteatoma, fenestration cavity, right



Stapedectomy, Fat Wire Piston, R-200

Title: Stapedectomy, Fat Wire Piston, R-200

Chapter: Surgical Pathology

Chapter Section: Fat and Wire, Stapedectomy, Surgery for Otosclerosis

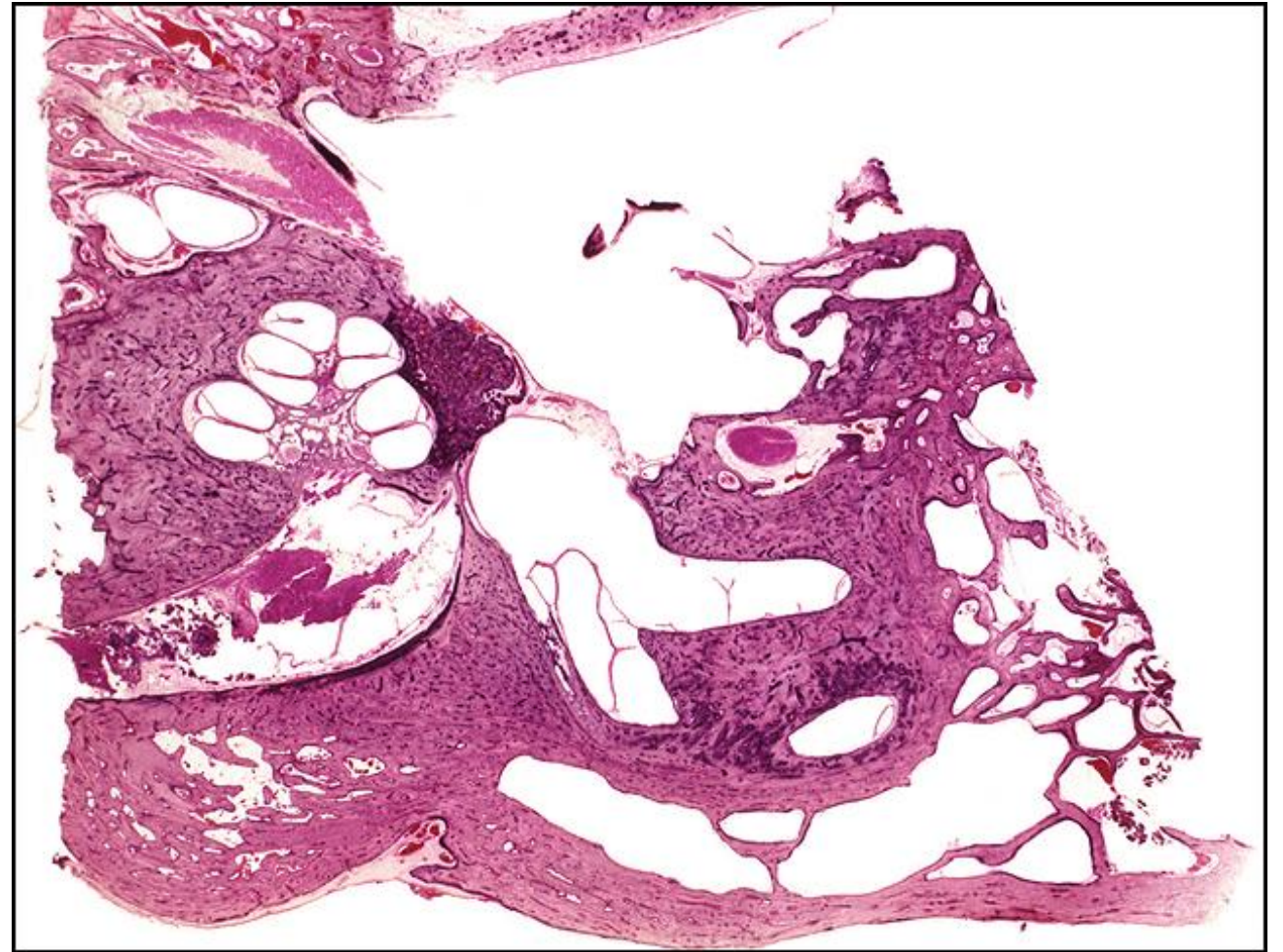
TB Case Number: 401

Gender: Female

Age (yrs.): 61

Otologic Diagnosis:

1. Otosclerosis, bilateral
2. Stapedectomy with fat-wire prosthesis, right
3. Degeneration of chorda tympani nerve
4. Anomaly facial nerve, right



Stapedectomy, Fat Wire Piston, R-212

Title: Stapedectomy, Fat Wire Piston, R-212

Chapter: Surgical Pathology

Chapter Section: Fat and Wire, Stapedectomy, Surgery for Otosclerosis

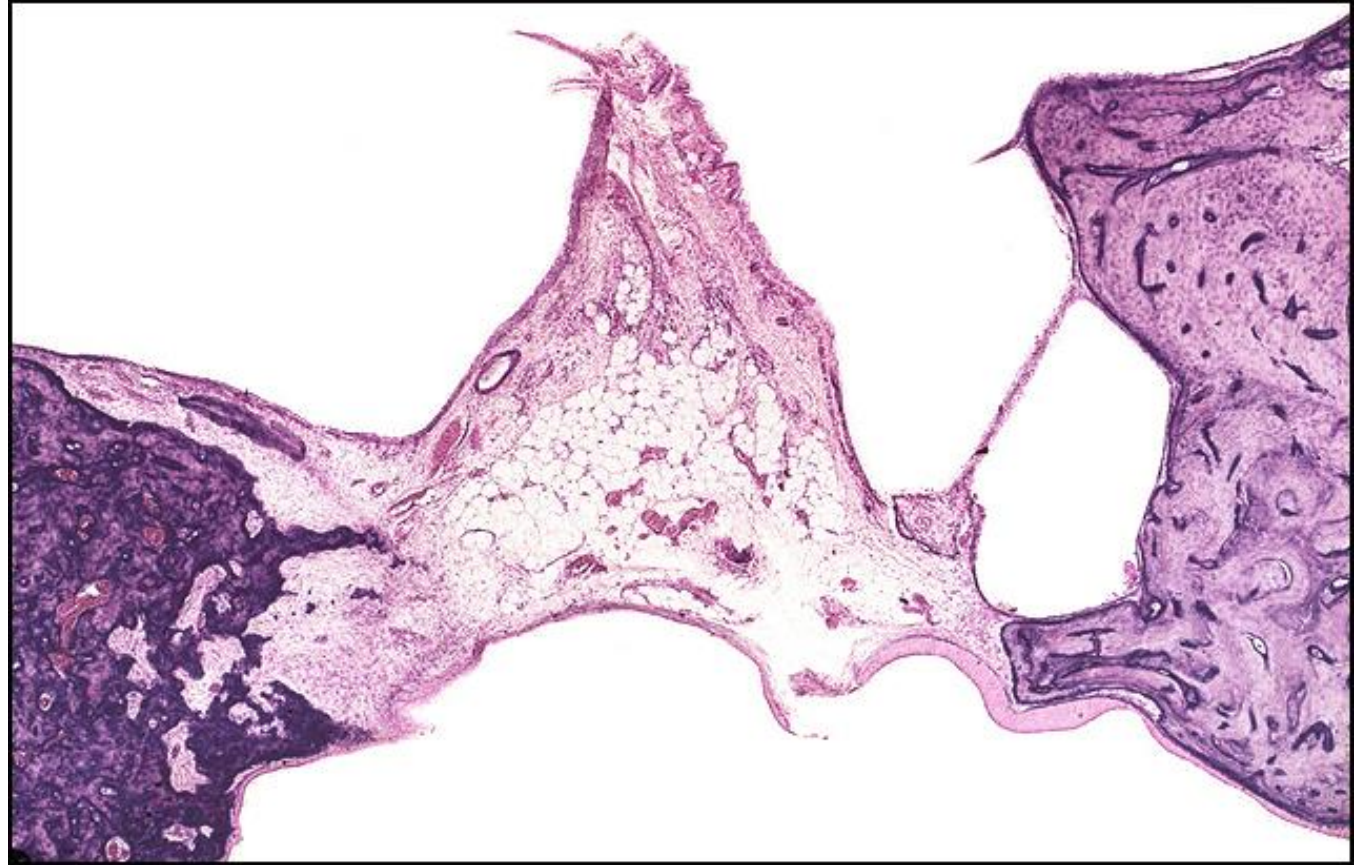
TB Case Number: 401

Gender: Female

Age (yrs.): 61

Otologic Diagnosis:

1. Otosclerosis, bilateral
2. Stapedectomy with fat-wire prosthesis, right
3. Degeneration of chorda tympani nerve
4. Anomaly facial nerve, right



Stapedectomy, Fat Wire Piston, R-171

Title: Stapedectomy, Fat Wire Piston, R-171

Chapter: Surgical Pathology

Chapter Section: Fat and Wire, Stapedectomy, Surgery for Otosclerosis

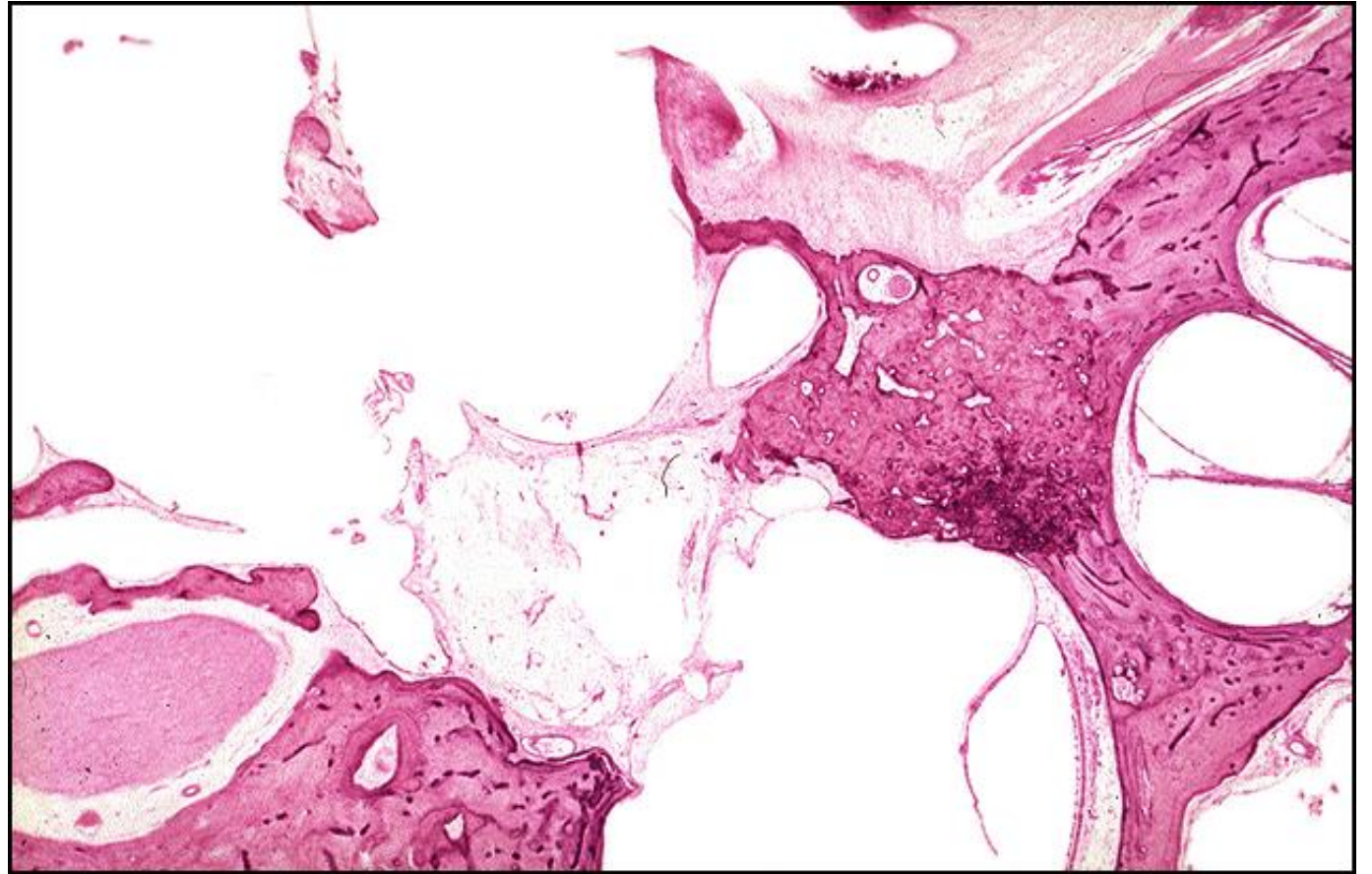
TB Case Number: 404

Gender: Female

Age (yrs.): 56

Otologic Diagnosis:

1. Otosclerosis with stapes fixation, bilateral
2. Stapedectomy with adipose tissue implant to oval window, right
3. Iatrogenic infracture, fallopian canal, causing temporary postoperative facial palsy, right



Stapedectomy, Fat Wire Piston, R-171

Title: Stapedectomy, Fat Wire Piston, R-171

Chapter: Surgical Pathology

Chapter Section: Fat and Wire, Stapedectomy, Surgery for Otosclerosis

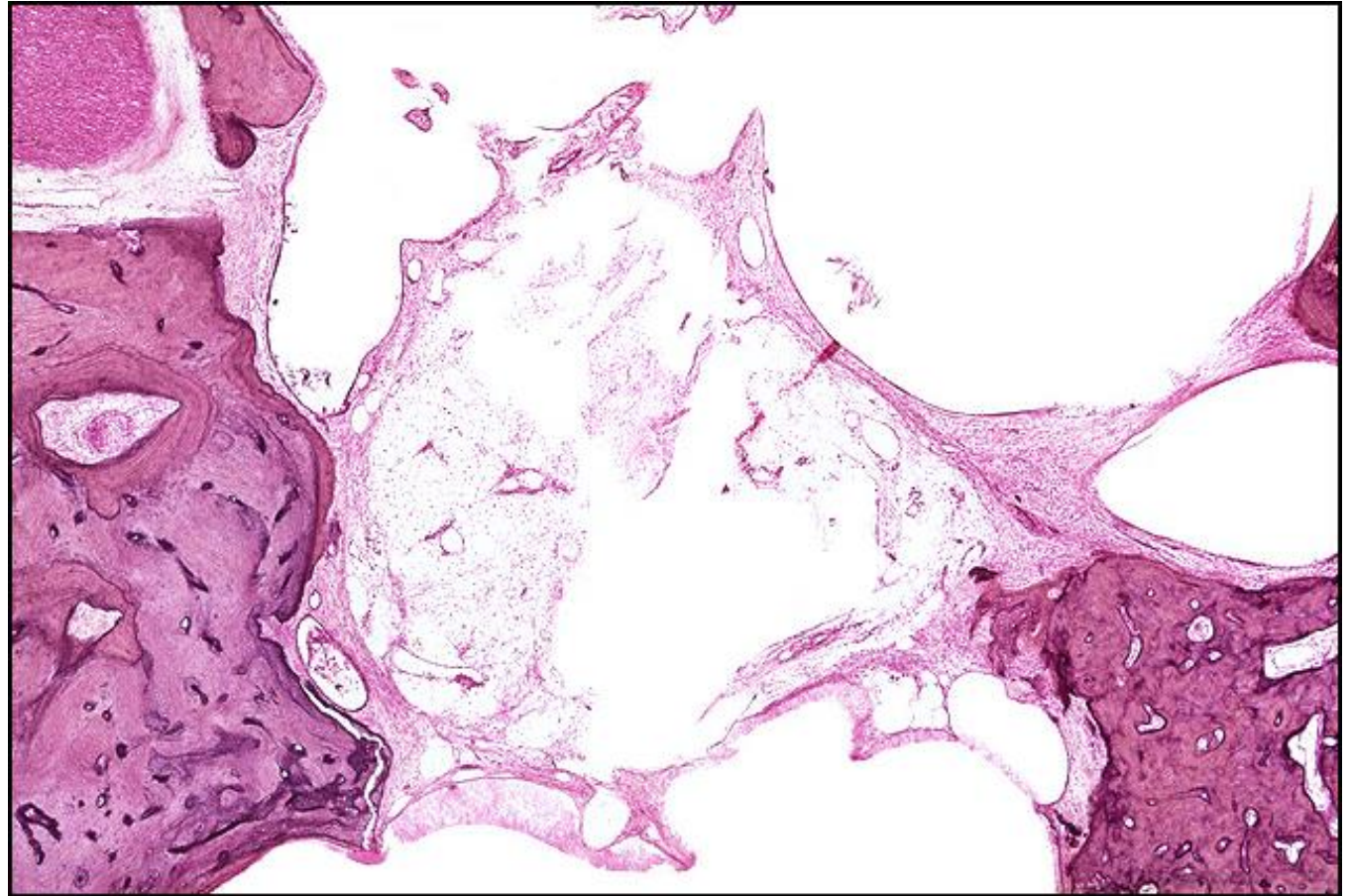
TB Case Number: 404

Gender: Female

Age (yrs.): 56

Otologic Diagnosis:

1. Otosclerosis with stapes fixation, bilateral
2. Stapedectomy with adipose tissue implant to oval window, right
3. Iatrogenic infracture, fallopian canal, causing temporary postoperative facial palsy, right



Stapedectomy, Fat Wire Piston, R-206

Title: Stapedectomy, Fat Wire Piston, R-206

Chapter: Surgical Pathology

Chapter Section: Fat and Wire, Stapedectomy, Surgery for Otosclerosis

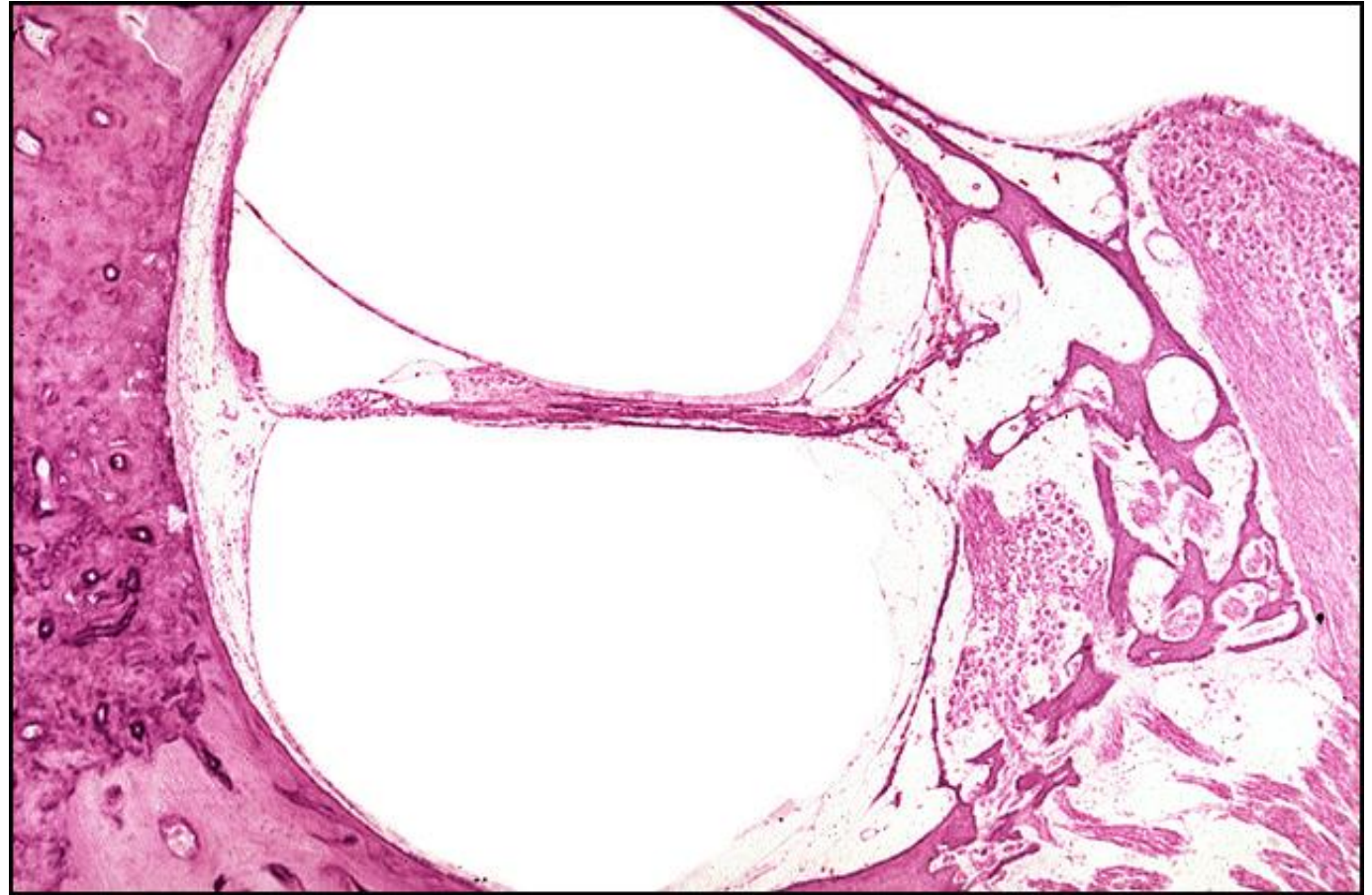
TB Case Number: 404

Gender: Female

Age (yrs.): 56

Otologic Diagnosis:

1. Otosclerosis with stapes fixation, bilateral
2. Stapedectomy with adipose tissue implant to oval window, right
3. Iatrogenic infracture, fallopian canal, causing temporary postoperative facial palsy, right



Stapedectomy, Fat Wire Piston, R-216

Title: Stapedectomy, Fat Wire Piston, R-216

Chapter: Surgical Pathology

Chapter Section: Fat and Wire, Stapedectomy, Surgery for Otosclerosis

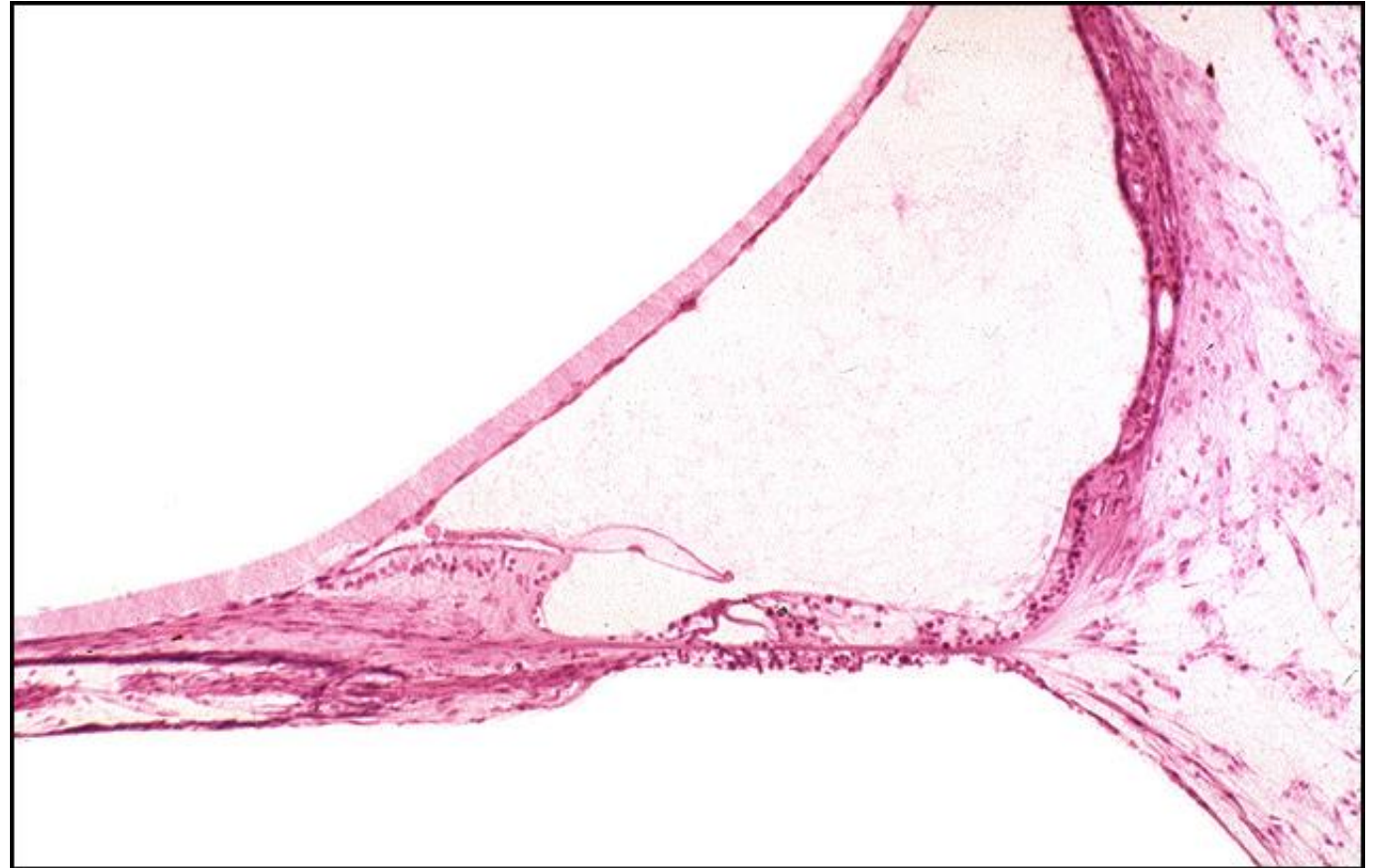
TB Case Number: 404

Gender: Female

Age (yrs.): 56

Otologic Diagnosis:

1. Otosclerosis with stapes fixation, bilateral
2. Stapedectomy with adipose tissue implant to oval window, right
3. Iatrogenic infracture, fallopian canal, causing temporary postoperative facial palsy, right



Stapedectomy, Fat Wire Piston, R-206

Title: Stapedectomy, Fat Wire Piston, R-206

Chapter: Surgical Pathology

Chapter Section: Fat and Wire, Stapedectomy, Surgery for Otosclerosis

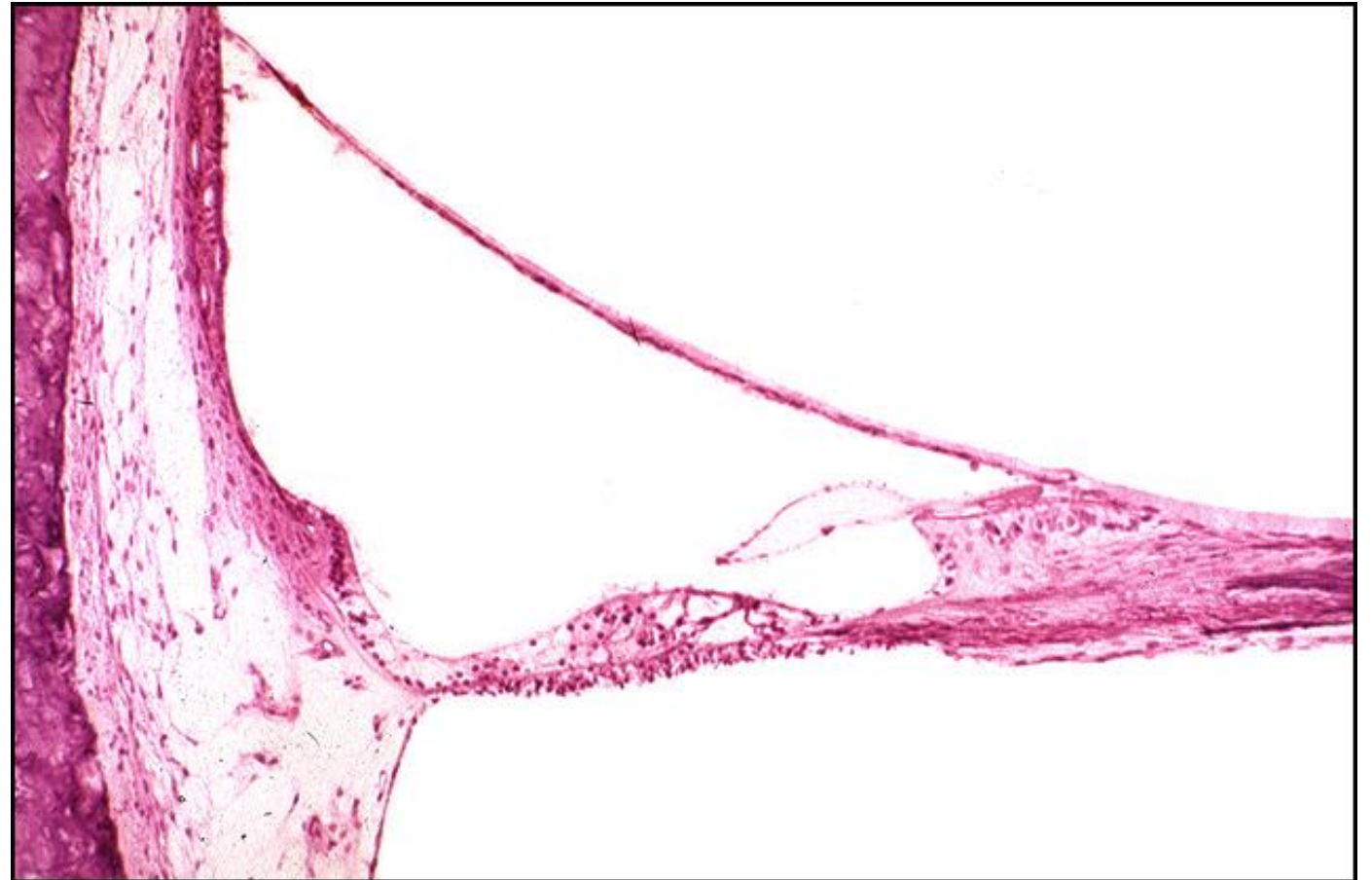TB Case Number: 404

Gender: Female

Age (yrs.): 56

Otologic Diagnosis:

1. Otosclerosis with stapes fixation, bilateral
2. Stapedectomy with adipose tissue implant to oval window, right
3. Iatrogenic fracture, fallopian canal, causing temporary postoperative facial palsy, right



Stapedectomy, Fat Wire Piston, R-206

Title: Stapedectomy, Fat Wire Piston, R-206

Chapter: Surgical Pathology

Chapter Section: Fat and Wire, Stapedectomy, Surgery for Otosclerosis

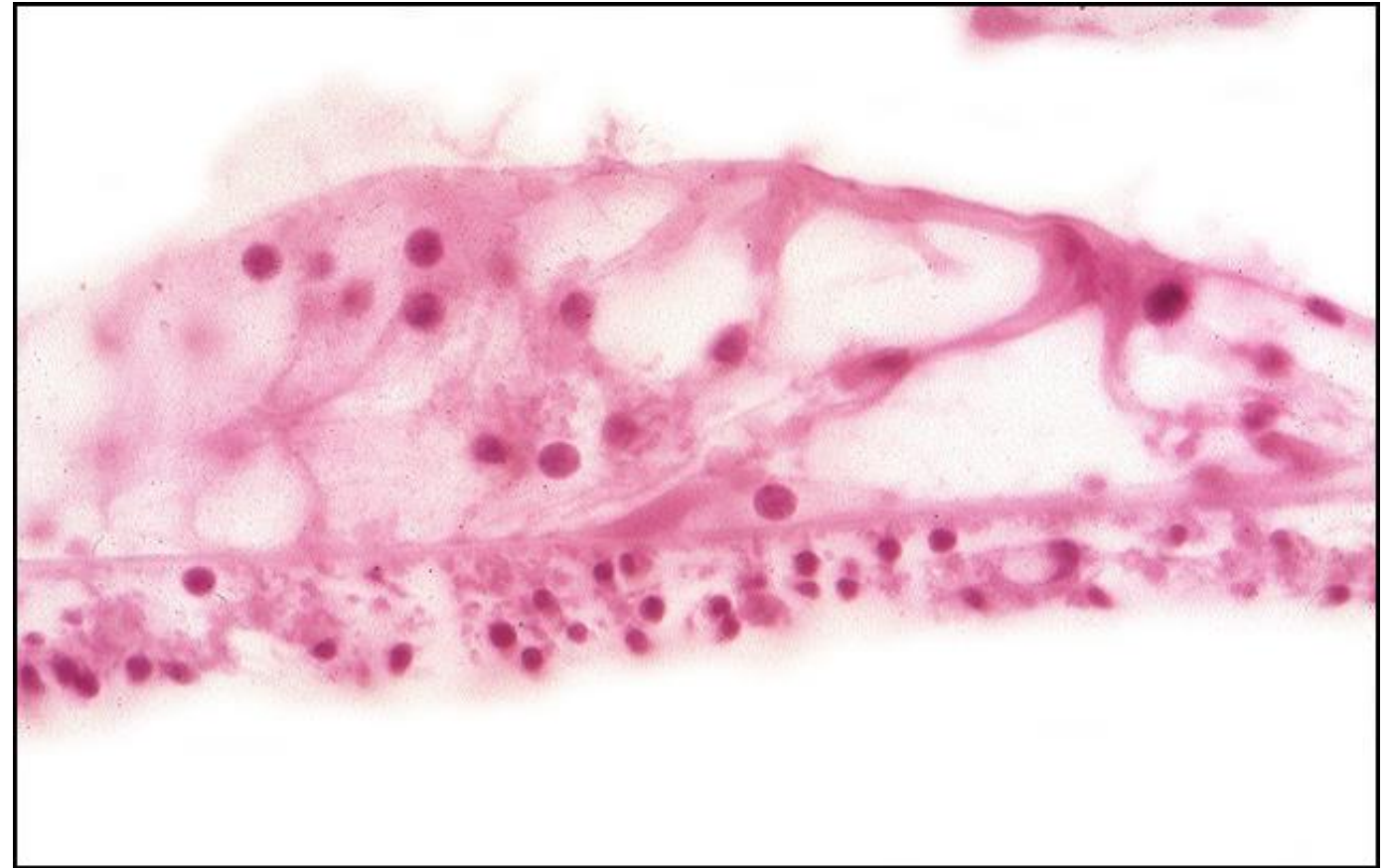TB Case Number: 404

Gender: Female

Age (yrs.): 56

Otologic Diagnosis:

1. Otosclerosis with stapes fixation, bilateral
2. Stapedectomy with adipose tissue implant to oval window, right
3. Iatrogenic infracture, fallopian canal, causing temporary postoperative facial palsy, right



Stapedectomy, Gel-wire Piston, R-177

Title: Stapedectomy, Gel-wire Piston, R-177

Chapter: Surgical Pathology

Chapter Section: Gelfoam and Wire,
Stapedectomy, Surgery for Otosclerosis

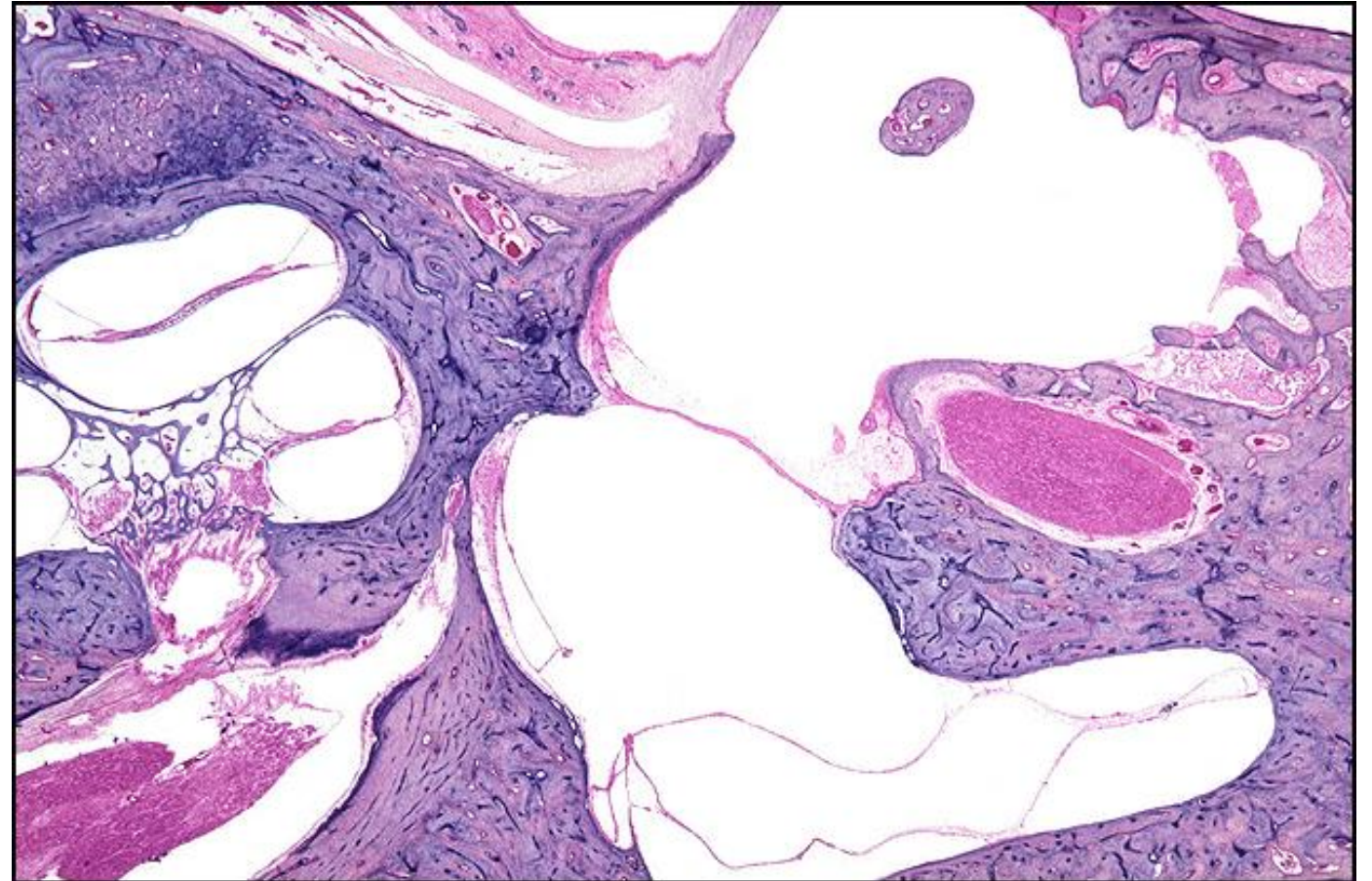TB Case Number: 466

Gender: Female

Age (yrs.): 81

Otologic Diagnosis:

1. Otosclerosis, bilateral
2. Stapedectomy, gel-wire prosthesis, bilateral
3. Spiral ligament, atrophy, severe, apical region, bilateral
4. Malleus, fixation, right
5. Sacculle, collapse, with some degeneration of sensory epithelium of macula, right
6. Semicircular duct, lateral, non-ampullated end, collapse, right



Stapedectomy, Gel-wire Piston, R-89

Title: Stapedectomy, Gel-wire Piston, R-89

Chapter: Surgical Pathology

Chapter Section: Gelfoam and Wire,
Stapedectomy, Surgery for Otosclerosis

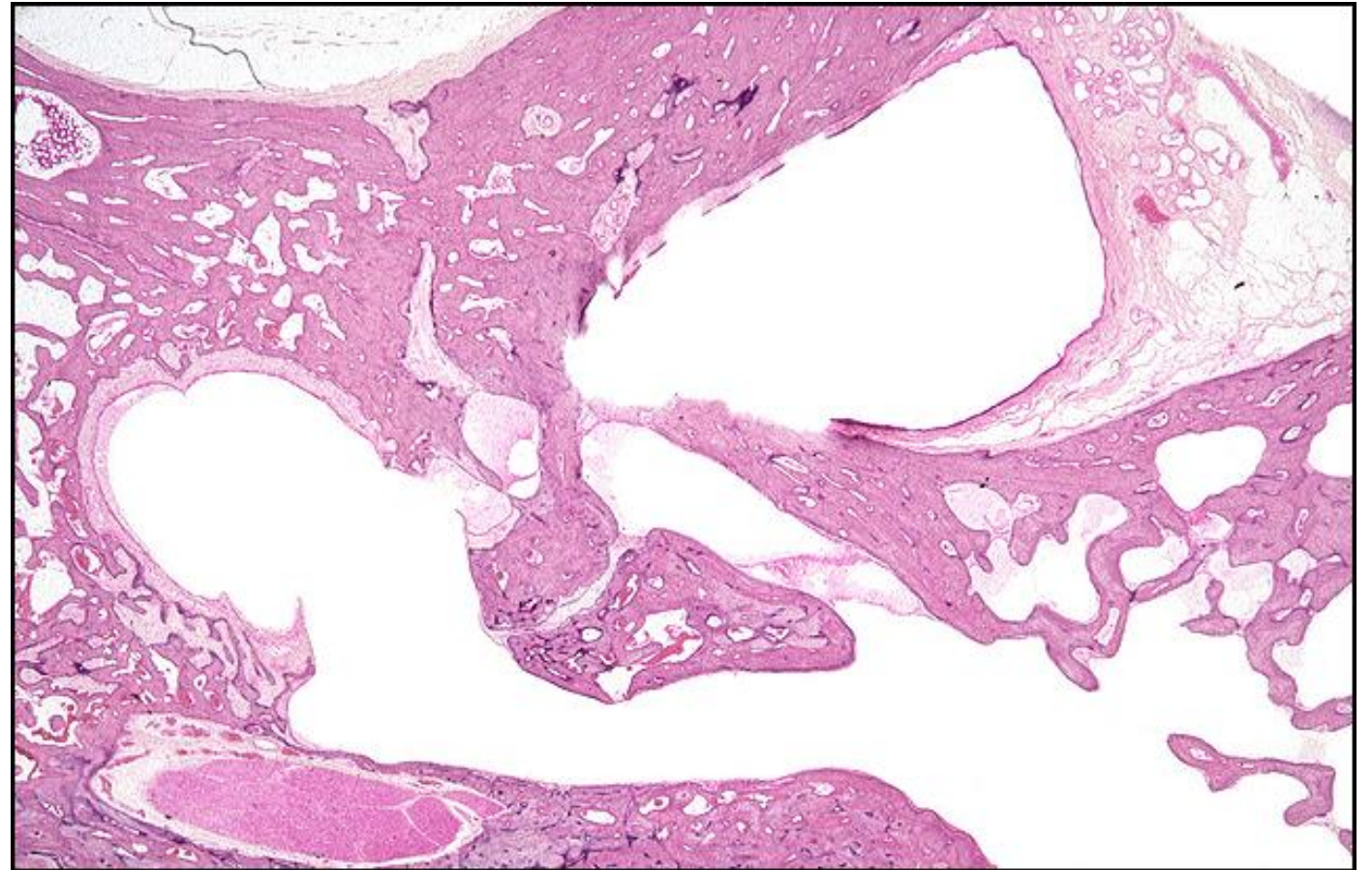
TB Case Number: 466

Gender: Female

Age (yrs.): 81

Otologic Diagnosis:

1. Otosclerosis, bilateral
2. Stapedectomy, gel-wire prosthesis, bilateral
3. Spiral ligament, atrophy, severe, apical region, bilateral
4. Malleus, fixation, right
5. Sacculle, collapse, with some degeneration of sensory epithelium of macula, right
6. Semicircular duct, lateral, non-ampullated end, collapse, right



Stapedectomy, Gel-wire Piston

Title: Stapedectomy, Gel-wire Piston

Chapter: Surgical Pathology

Chapter Section: Gelfoam and Wire, Stapedectomy, Surgery for Otosclerosis

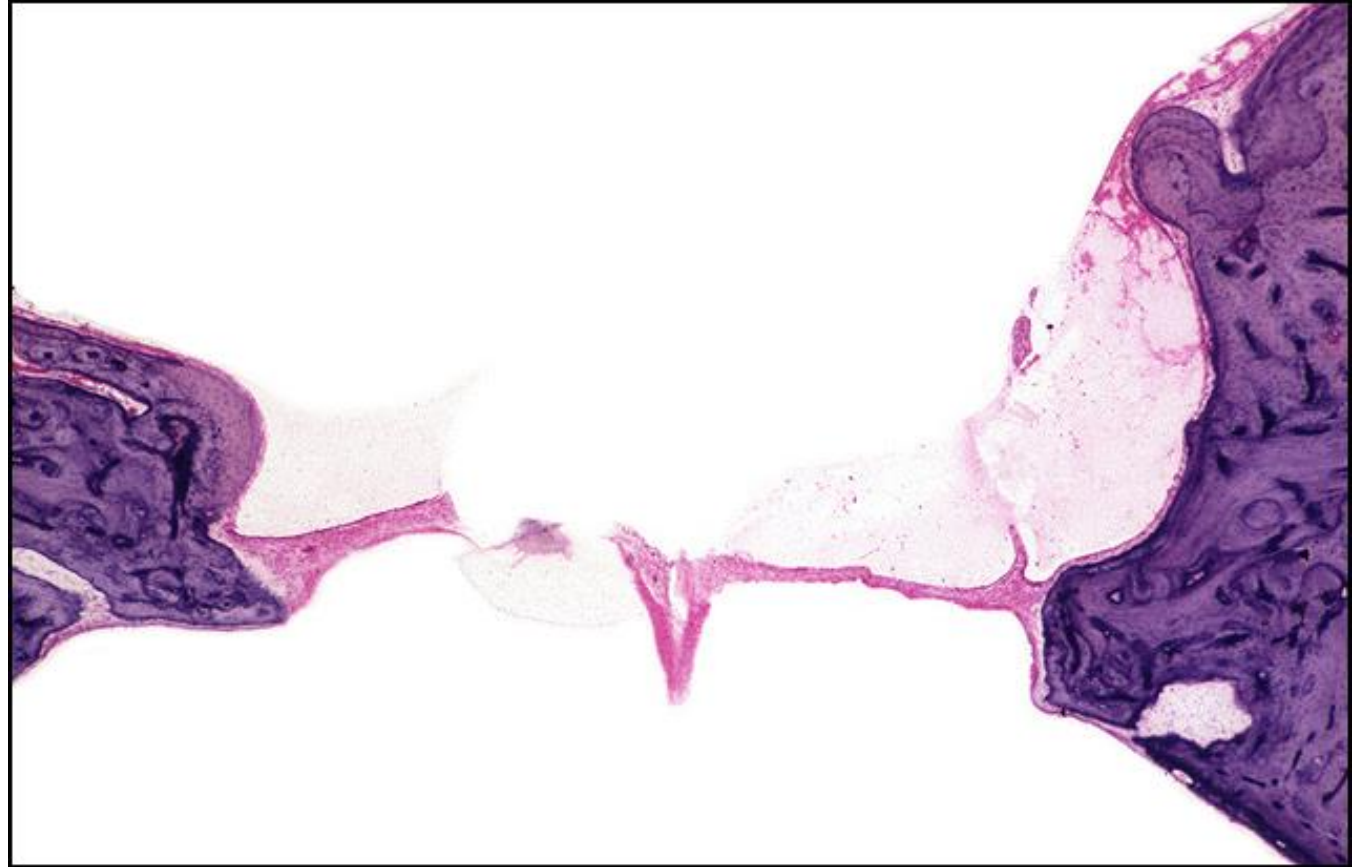
TB Case Number: 466

Gender: Female

Age (yrs.): 81

Otologic Diagnosis:

1. Otosclerosis, bilateral
2. Stapedectomy, gel-wire prosthesis, bilateral
3. Spiral ligament, atrophy, severe, apical region, bilateral
4. Malleus, fixation, right
5. Sacculle, collapse, with some degeneration of sensory epithelium of macula, right
6. Semicircular duct, lateral, non-ampullated end, collapse, right



Stapedectomy, Gel-wire Piston, L-181

Title: Stapedectomy, Gel-wire Piston, L-181

Chapter: Surgical Pathology

Chapter Section: Gelfoam and Wire, Stapedectomy, Surgery for Otosclerosis

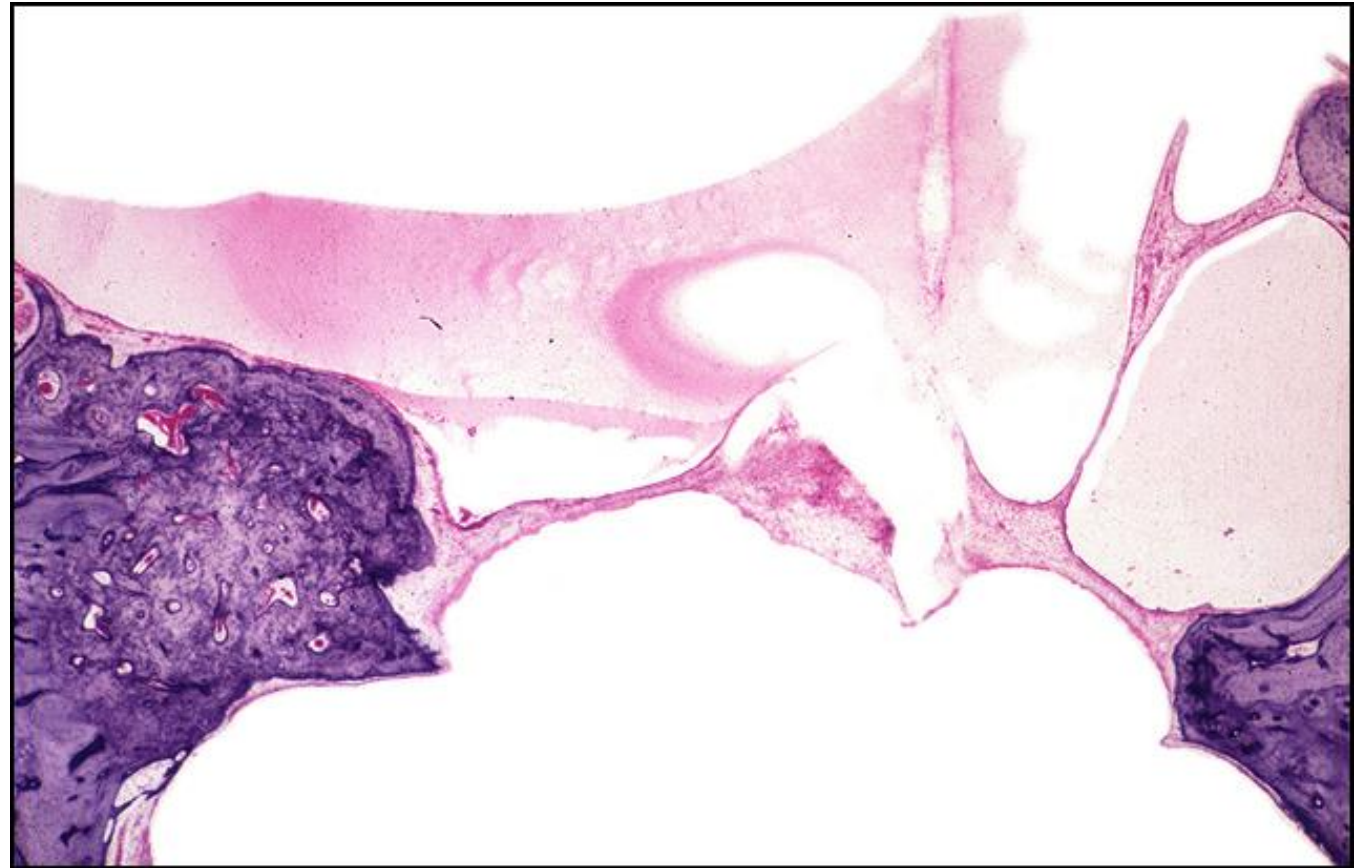TB Case Number: 466

Gender: Female

Age (yrs.): 81

Otologic Diagnosis:

1. Otosclerosis, bilateral
2. Stapedectomy, gel-wire prosthesis, bilateral
3. Spiral ligament, atrophy, severe, apical region, bilateral
4. Malleus, fixation, right
5. Sacculle, collapse, with some degeneration of sensory epithelium of macula, right
6. Semicircular duct, lateral, non-ampullated end, collapse, right



Stapedectomy, Gel-wire Piston, R-181

Title: Stapedectomy, Gel-wire Piston, R-181

Chapter: Surgical Pathology

Chapter Section: Gelfoam and Wire, Stapedectomy, Surgery for Otosclerosis

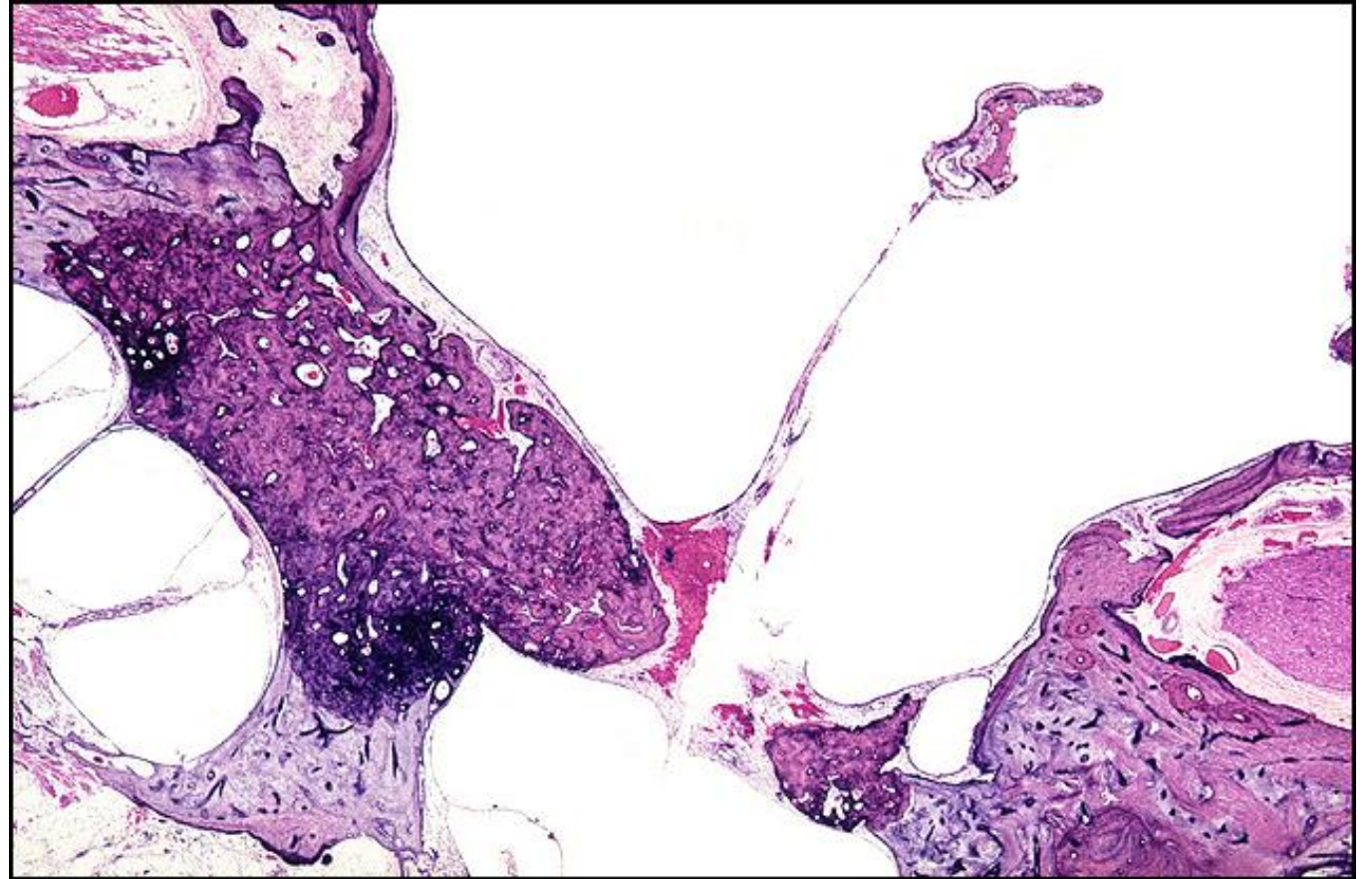
TB Case Number: 444

Gender: Male

Age (yrs.): 71

Otologic Diagnosis:

1. Otosclerosis, severe, with stapes fixation, right
2. Stapedectomy, partial
3. Gelfoam-wire prosthesis, removed, right
4. Membranous sheath, previously covering wire prosthesis in middle ear, right
5. Endolymphatic hydrops, focal, hook region of cochlea, right



Stapedectomy, Gel-wire Piston, R-181

Title: Stapedectomy, Gel-wire Piston, R-181

Chapter: Surgical Pathology

Chapter Section: Gelfoam and Wire, Stapedectomy, Surgery for Otosclerosis

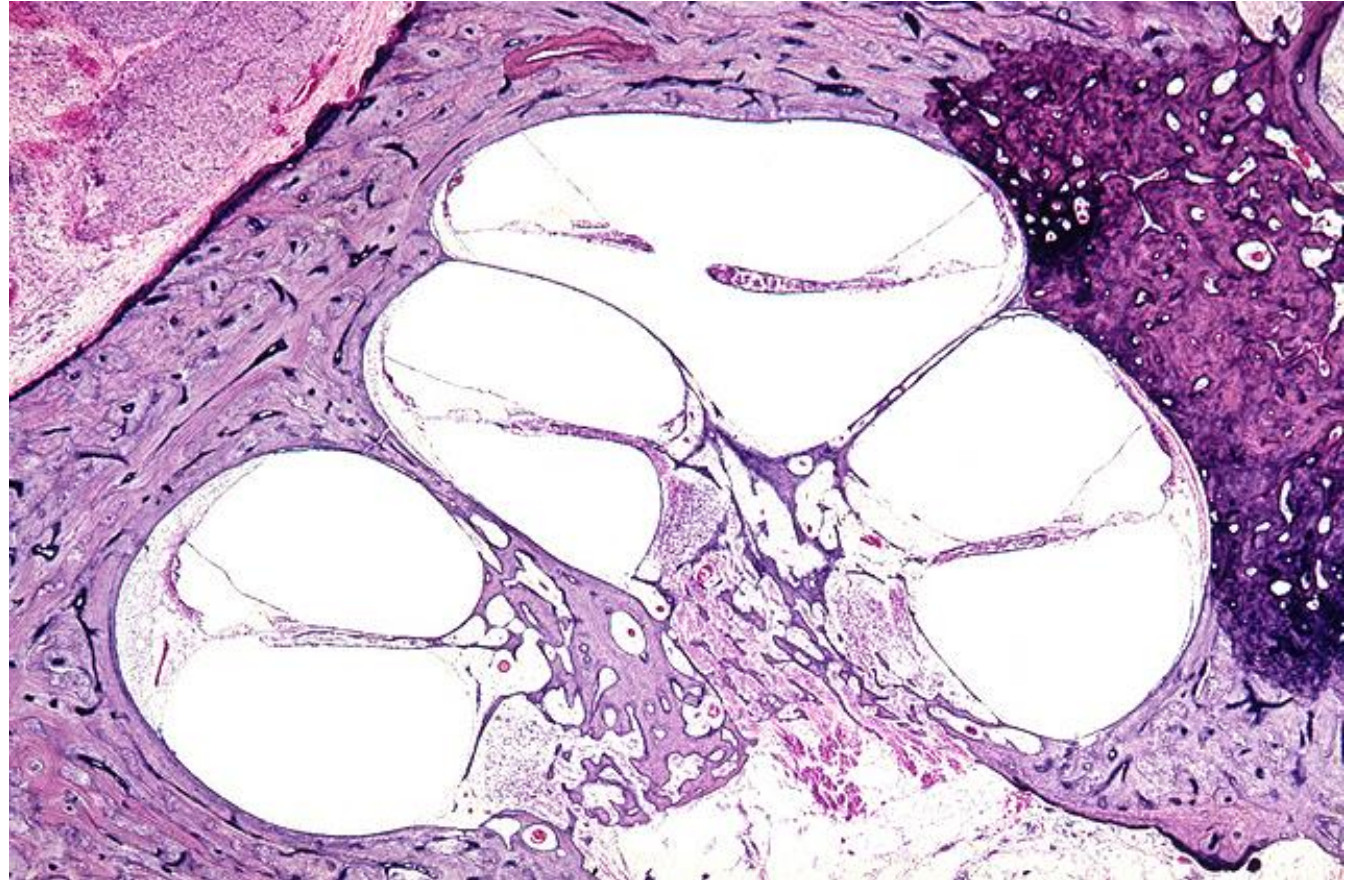
TB Case Number: 444

Gender: Male

Age (yrs.): 71

Otologic Diagnosis:

1. Otosclerosis, severe, with stapes fixation, right
2. Stapedectomy, partial
3. Gelfoam-wire prosthesis, removed, right
4. Membranous sheath, previously covering wire prosthesis in middle ear, right
5. Endolymphatic hydrops, focal, hook region of cochlea, right



Stapedectomy, Gel-wire Piston, R-221

Title: Stapedectomy, Gel-wire Piston, R-221

Chapter: Surgical Pathology

Chapter Section: Gelfoam and Wire, Stapedectomy, Surgery for Otosclerosis

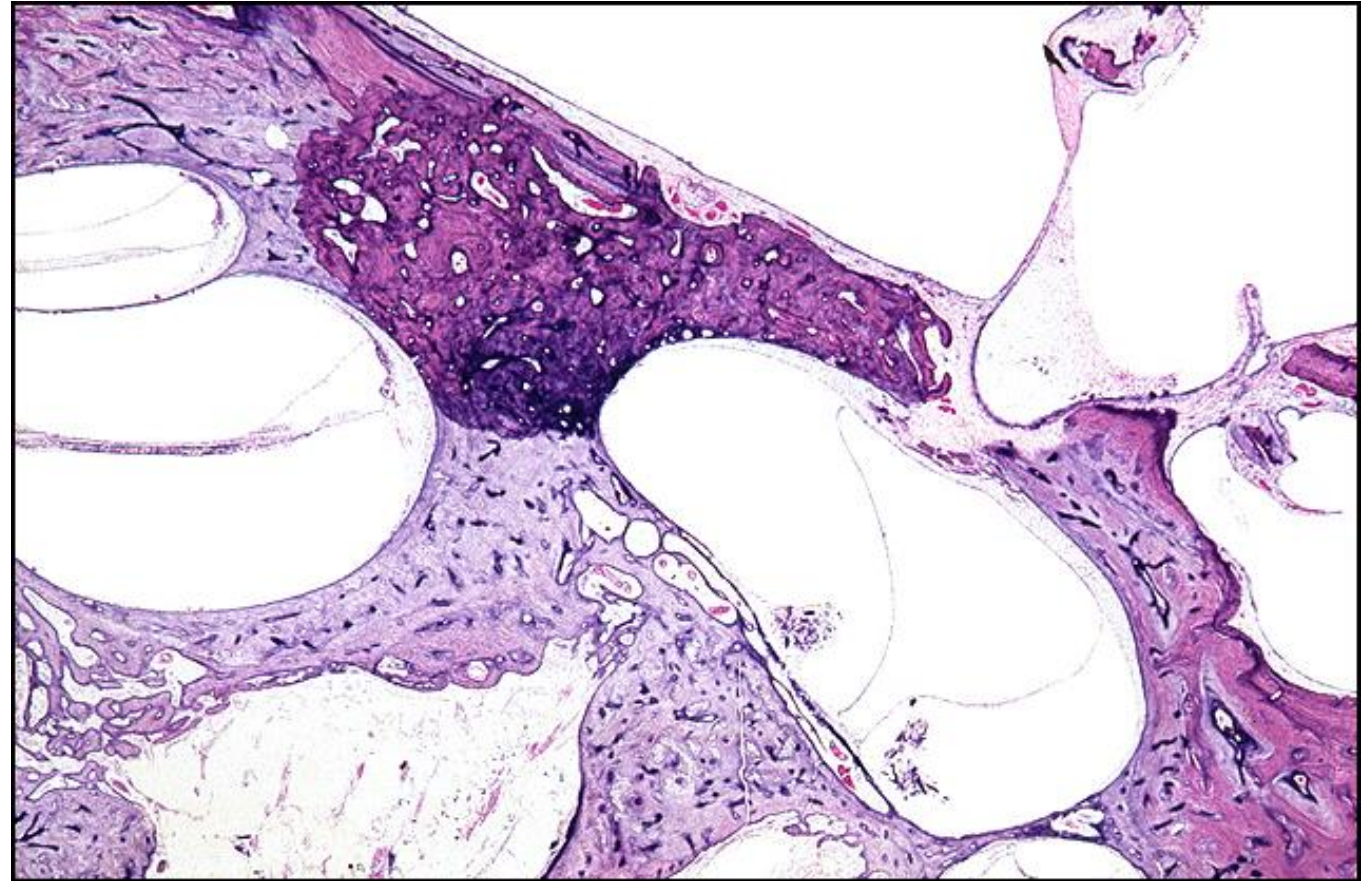
TB Case Number: 444

Gender: Male

Age (yrs.): 71

Otologic Diagnosis:

1. Otosclerosis, severe, with stapes fixation, right
2. Stapedectomy, partial
3. Gelfoam-wire prosthesis, removed, right
4. Membranous sheath, previously covering wire prosthesis in middle ear, right
5. Endolymphatic hydrops, focal, hook region of cochlea, right



Stapedectomy, Tef-wire Piston, R-205

Title: Stapedectomy, Tef-wire Piston, R-205

Chapter: Surgical Pathology

Chapter Section: Stapedectomy, Surgery for
Otosclerosis, Wire and Teflon

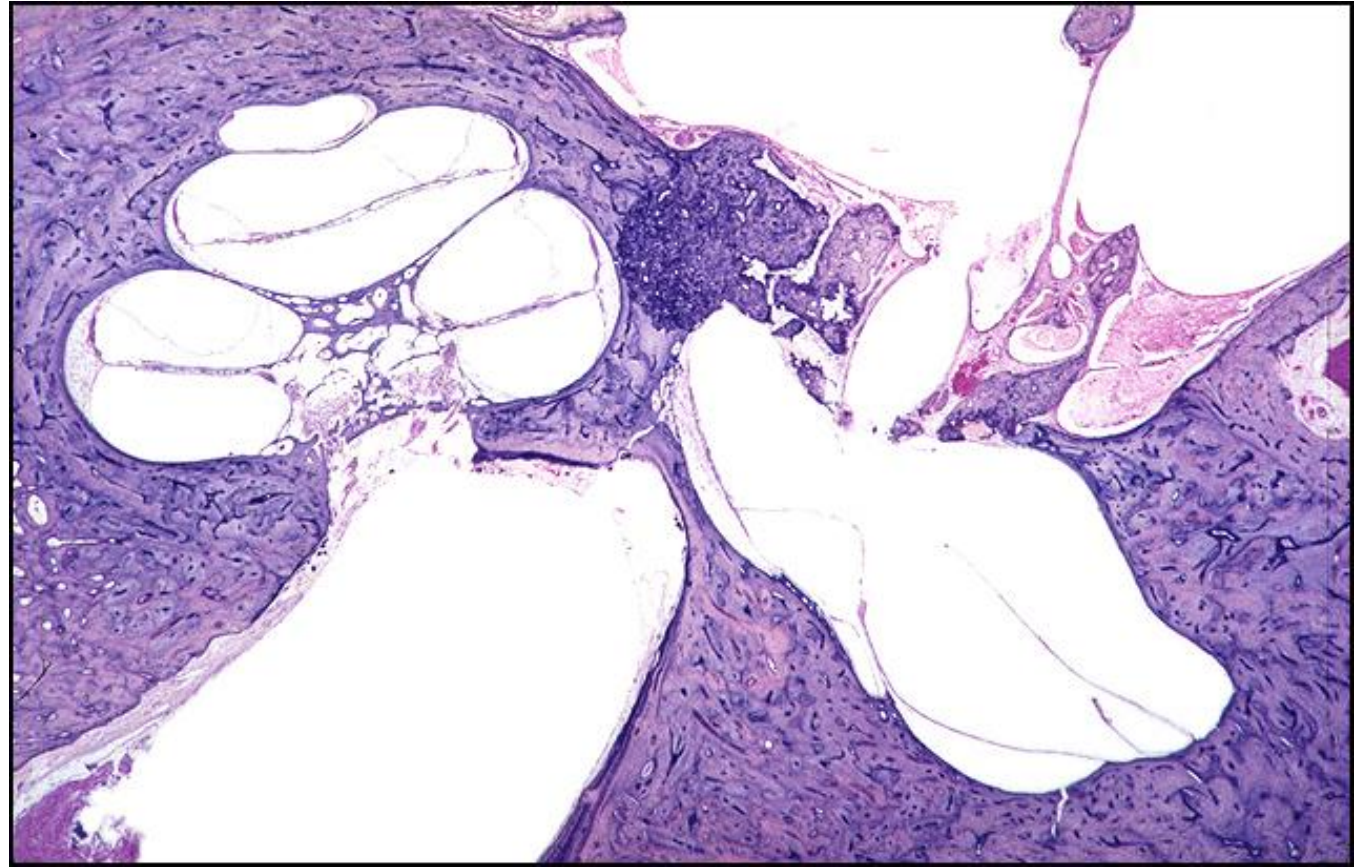
TB Case Number: 544

Gender: Female

Age (yrs.): 55

Otologic Diagnosis:

1. Otosclerosis, with stapes fixation and round window occlusion, bilateral
2. Stapedectomy, tef-wire piston implant, right
3. Cochlear duct, surgical laceration, right
4. Saccule, surgical laceration, right
5. Endolymphatic hydrops, secondary to surgical trauma, right
6. Cochlea, sensory structures, degeneration, secondary to surgical trauma, right
7. Saccule, degeneration, secondary to surgical trauma



Stapedectomy, Tef-wire Piston, R-205

Title: Stapedectomy, Tef-wire Piston, R-205

Chapter: Surgical Pathology

Chapter Section: Stapedectomy, Surgery for
Otosclerosis, Wire and Teflon

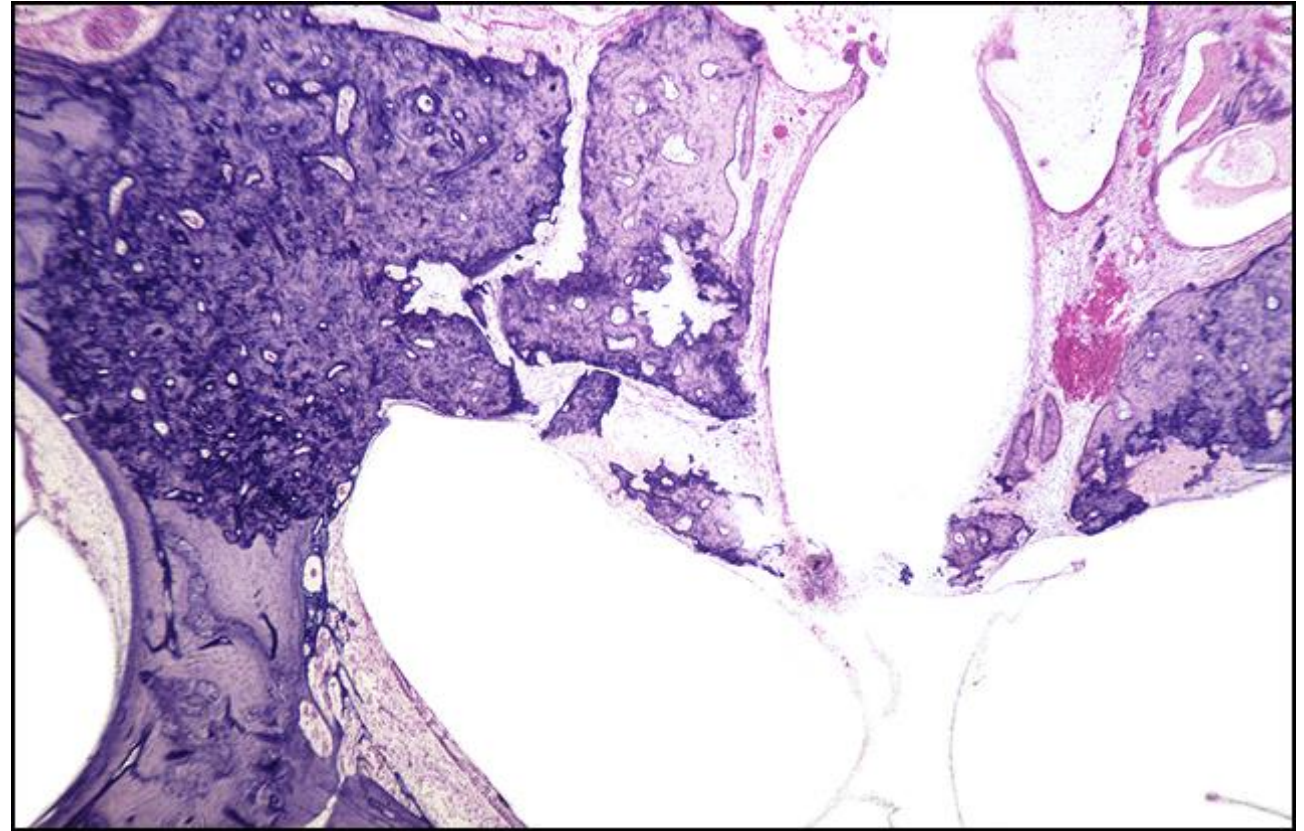
TB Case Number: 544

Gender: Female

Age (yrs.): 55

Otologic Diagnosis:

1. Otosclerosis, with stapes fixation and round window occlusion, bilateral
2. Stapedectomy, tef-wire piston implant, right
3. Cochlear duct, surgical laceration, right
4. Sacculle, surgical laceration, right
5. Endolymphatic hydrops, secondary to surgical trauma, right
6. Cochlea, sensory structures, degeneration, secondary to surgical trauma, right
7. Sacculle, degeneration, secondary to surgical trauma



Stapedectomy, Tef-wire Piston, R-200

Title: Stapedectomy, Tef-wire Piston, R-200

Chapter: Surgical Pathology

Chapter Section: Stapedectomy, Surgery for
Otosclerosis, Wire and Teflon

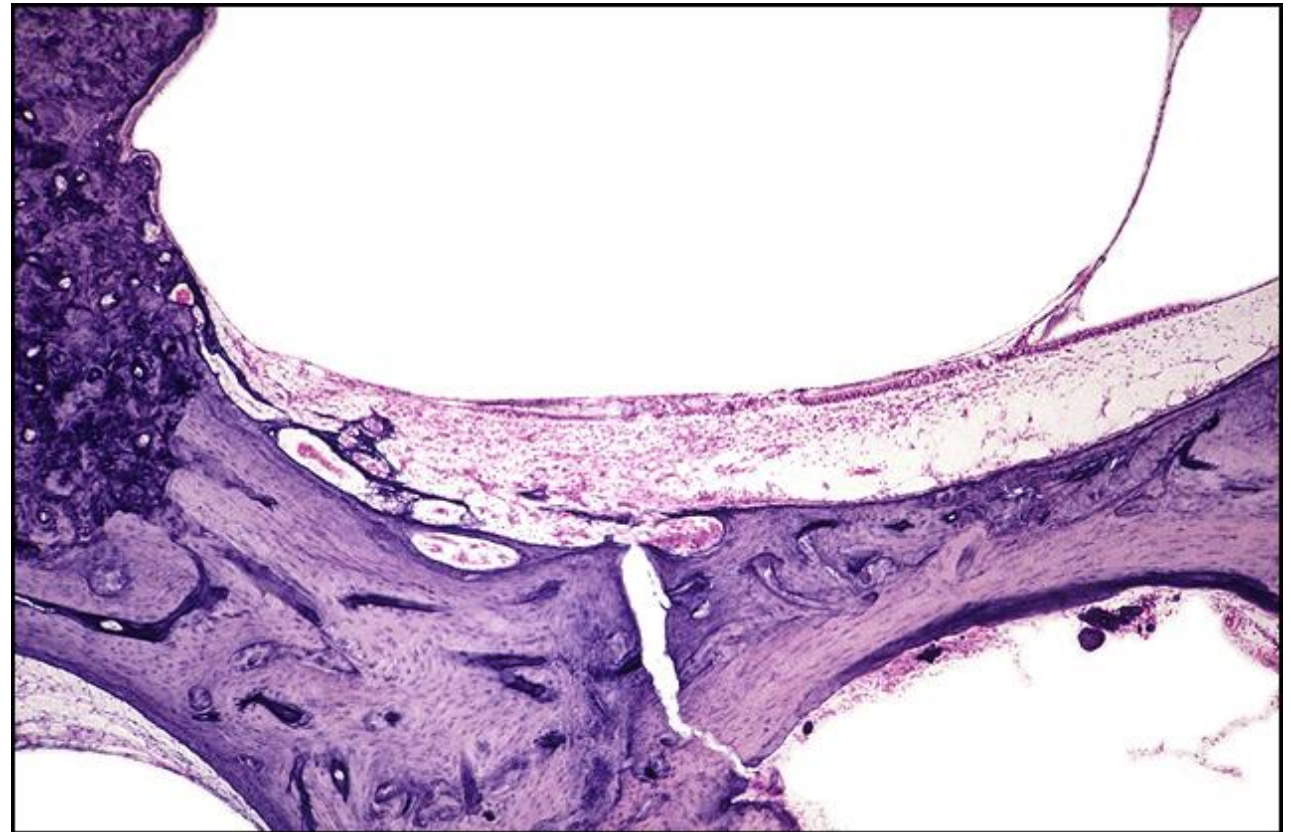
TB Case Number: 544

Gender: Female

Age (yrs.): 55

Otologic Diagnosis:

1. Otosclerosis, with stapes fixation and round window occlusion, bilateral
2. Stapedectomy, tef-wire piston implant, right
3. Cochlear duct, surgical laceration, right
4. Saccule, surgical laceration, right
5. Endolymphatic hydrops, secondary to surgical trauma, right
6. Cochlea, sensory structures, degeneration, secondary to surgical trauma, right
7. Saccule, degeneration, secondary to surgical trauma



Stapedectomy, Tef-wire Piston, R-231

Title: Stapedectomy, Tef-wire Piston, R-231

Chapter: Surgical Pathology

Chapter Section: Stapedectomy, Surgery for Otosclerosis, Wire and Teflon

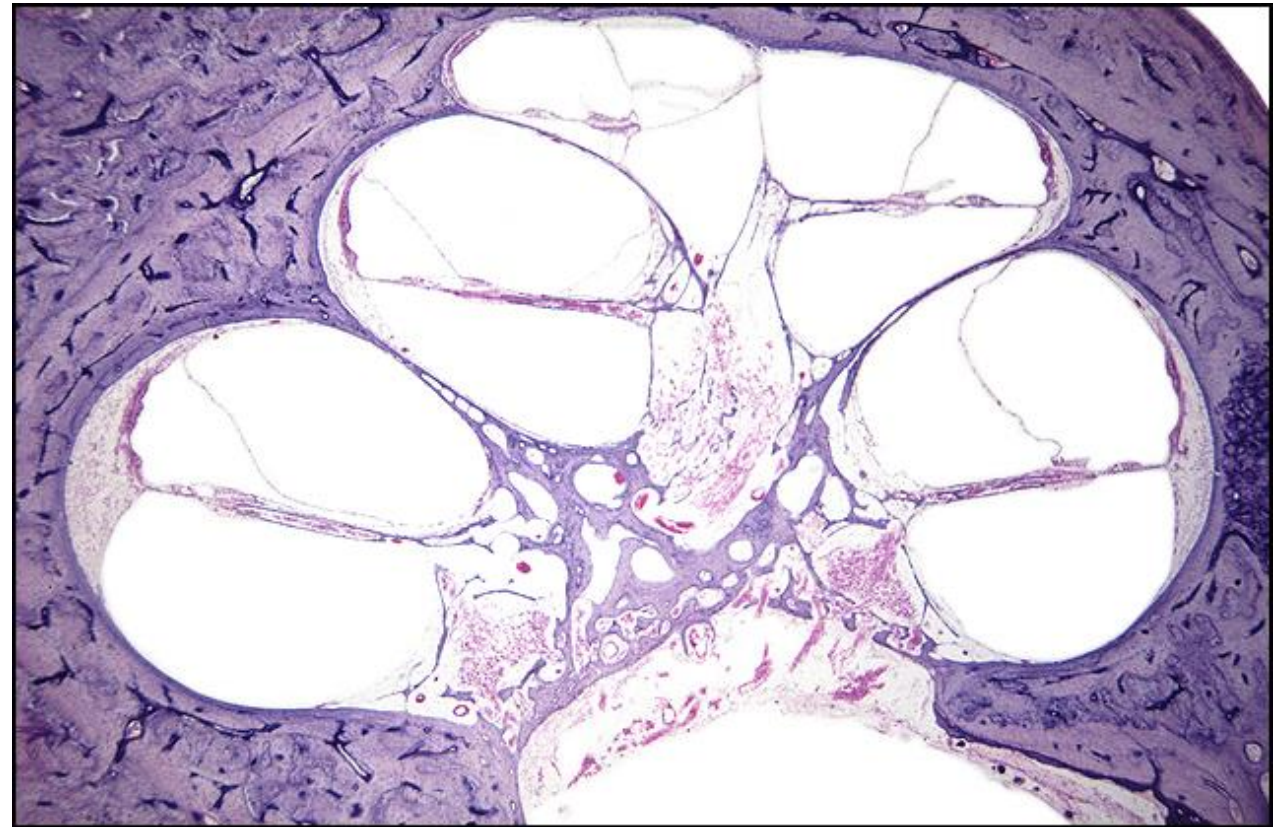
TB Case Number: 544

Gender: Female

Age (yrs.): 55

Otologic Diagnosis:

1. Otosclerosis, with stapes fixation and round window occlusion, bilateral
2. Stapedectomy, tef-wire piston implant, right
3. Cochlear duct, surgical laceration, right
4. Sacculle, surgical laceration, right
5. Endolymphatic hydrops, secondary to surgical trauma, right
6. Cochlea, sensory structures, degeneration, secondary to surgical trauma, right
7. Sacculle, degeneration, secondary to surgical trauma



Stapedectomy, Tef-wire Piston, R-231

Title: Stapedectomy, Tef-wire Piston, R-231

Chapter: Surgical Pathology

Chapter Section: Stapedectomy, Surgery for
Otosclerosis, Wire and Teflon

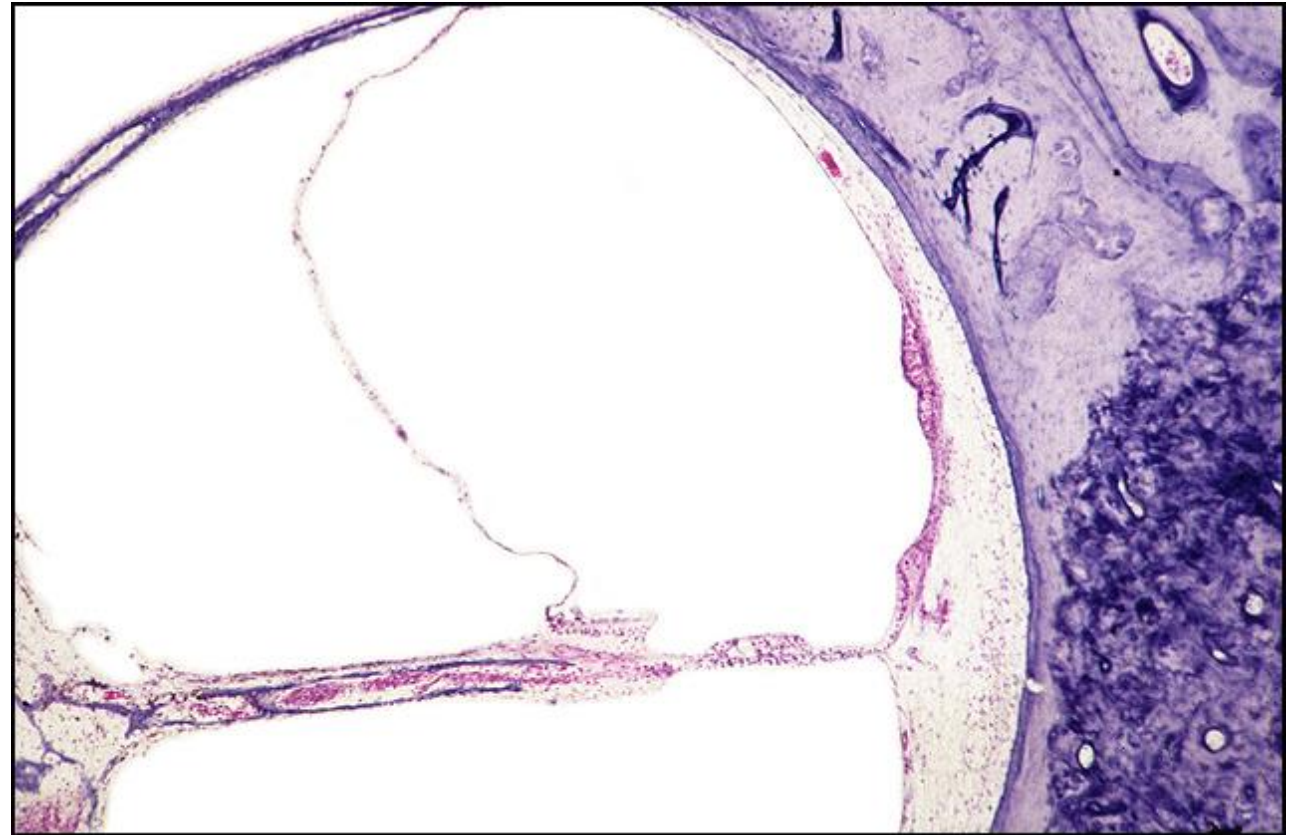
TB Case Number: 544

Gender: Female

Age (yrs.): 55

Otologic Diagnosis:

1. Otosclerosis, with stapes fixation and round window occlusion, bilateral
2. Stapedectomy, tef-wire piston implant, right
3. Cochlear duct, surgical laceration, right
4. Saccule, surgical laceration, right
5. Endolymphatic hydrops, secondary to surgical trauma, right
6. Cochlea, sensory structures, degeneration, secondary to surgical trauma, right
7. Saccule, degeneration, secondary to surgical trauma



Stapedectomy, Tef-wire Piston, R-231

Title: Stapedectomy, Tef-wire Piston, R-231

Chapter: Surgical Pathology

Chapter Section: Stapedectomy, Surgery for Otosclerosis, Wire and Teflon

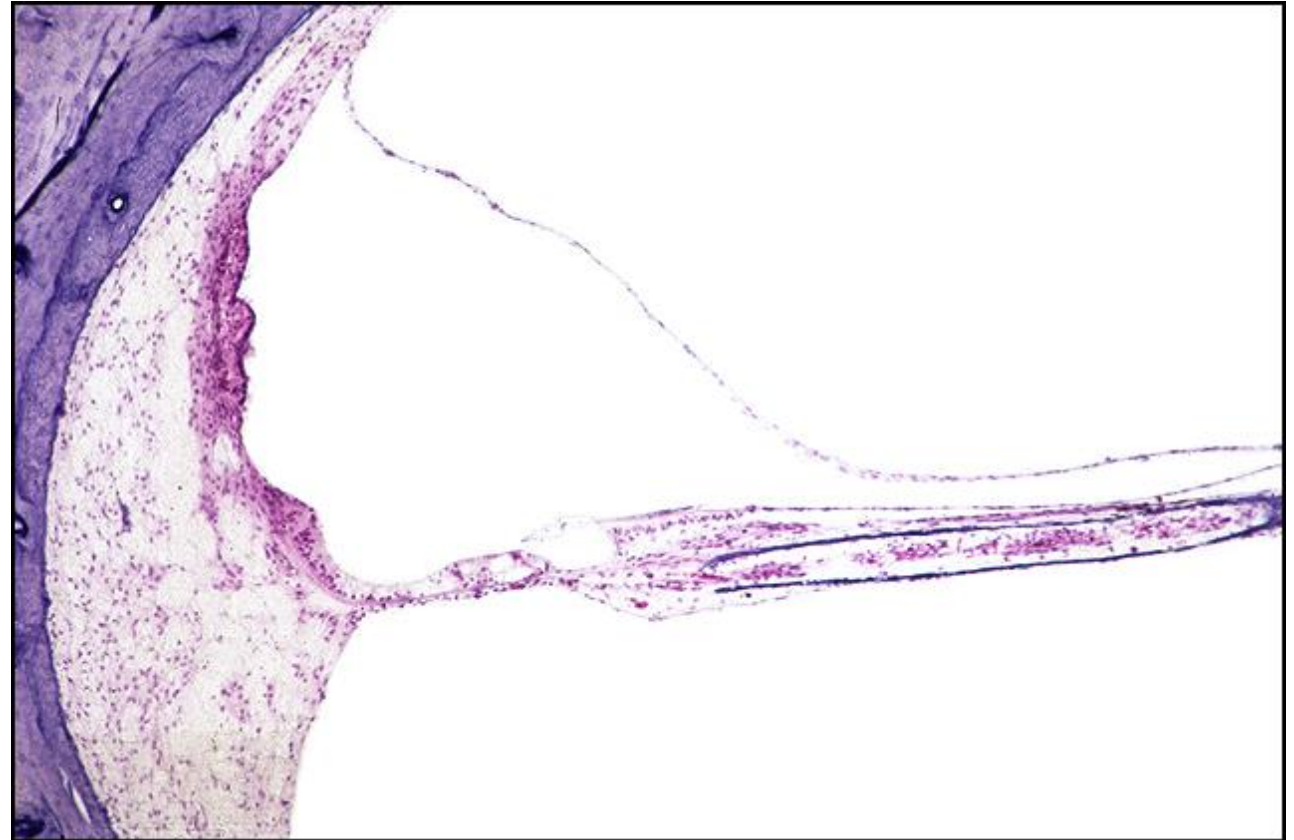TB Case Number: 544

Gender: Female

Age (yrs.): 55

Otologic Diagnosis:

1. Otosclerosis, with stapes fixation and round window occlusion, bilateral
2. Stapedectomy, tef-wire piston implant, right
3. Cochlear duct, surgical laceration, right
4. Sacculle, surgical laceration, right
5. Endolymphatic hydrops, secondary to surgical trauma, right
6. Cochlea, sensory structures, degeneration, secondary to surgical trauma, right
7. Sacculle, degeneration, secondary to surgical trauma



Stapedectomy, Tef-wire Piston, R-261

Title: Stapedectomy, Tef-wire Piston, R-261

Chapter: Surgical Pathology

Chapter Section: Stapedectomy, Surgery for Otosclerosis

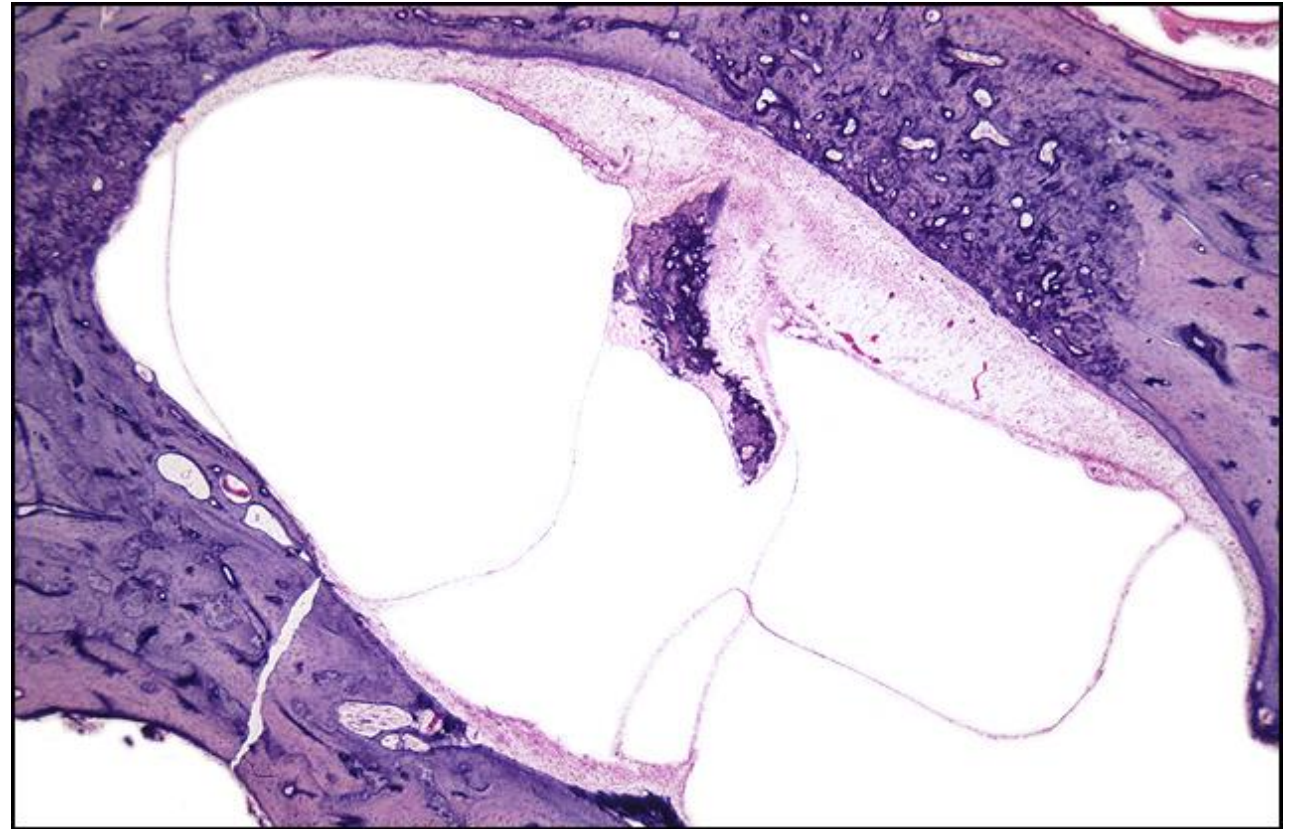
TB Case Number: 544

Gender: Female

Age (yrs.): 55

Otologic Diagnosis:

1. Otosclerosis, with stapes fixation and round window occlusion, bilateral
2. Stapedectomy, tef-wire piston implant, right
3. Cochlear duct, surgical laceration, right
4. Sacculle, surgical laceration, right
5. Endolymphatic hydrops, secondary to surgical trauma, right
6. Cochlea, sensory structures, degeneration, secondary to surgical trauma, right
7. Sacculle, degeneration, secondary to surgical trauma



Stapedectomy, Gel-wire Piston, L-185

Title: Stapedectomy, Gel-wire Piston, L-185

Chapter: Surgical Pathology

Chapter Section: Gelfoam and Wire, Stapedectomy, Surgery for Otosclerosis

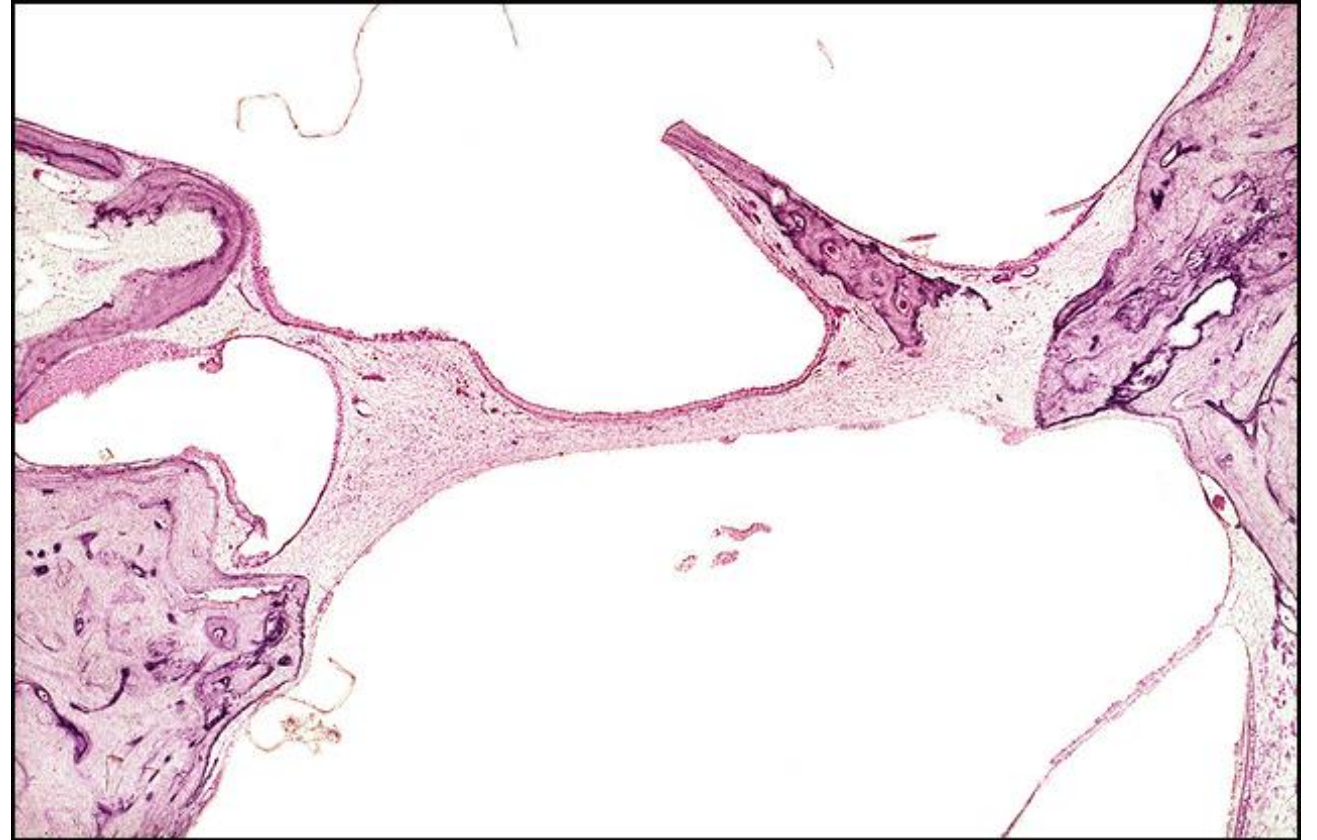
TB Case Number: 588

Gender: Male

Age (yrs.): 81

Otologic Diagnosis:

1. Otosclerosis, bilateral
2. Stapedectomy, with insertion of gel-wire prosthesis, left
3. Hearing loss, combined sensorineural and conductive, bilateral



Stapedectomy, Gel-wire Piston, R-233

Title: Stapedectomy, Gel-wire Piston, R-233

Chapter: Surgical Pathology

Chapter Section: Gelfoam and Wire, Stapedectomy, Surgery for Otosclerosis

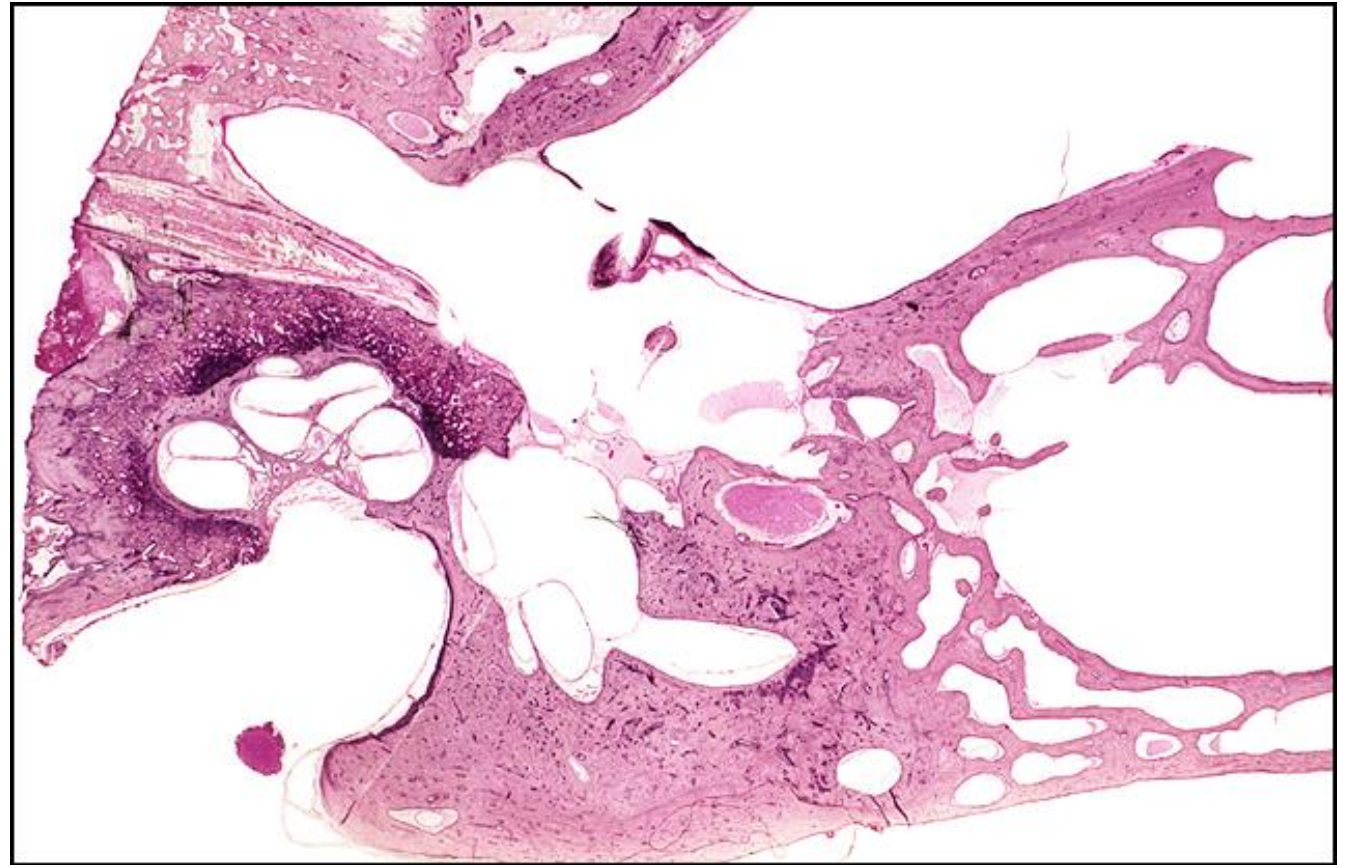
TB Case Number: 658

Gender: Male

Age (yrs.): 62

Otologic Diagnosis:

1. Otosclerosis, clinical, bilateral
2. Stapedectomy, insertion of gelfoam-wire prosthesis, right



Stapedectomy, Gel-wire Piston, R-250

Title: Stapedectomy, Gel-wire Piston, R-250

Chapter: Surgical Pathology

Chapter Section: Gelfoam and Wire, Stapedectomy, Surgery for Otosclerosis

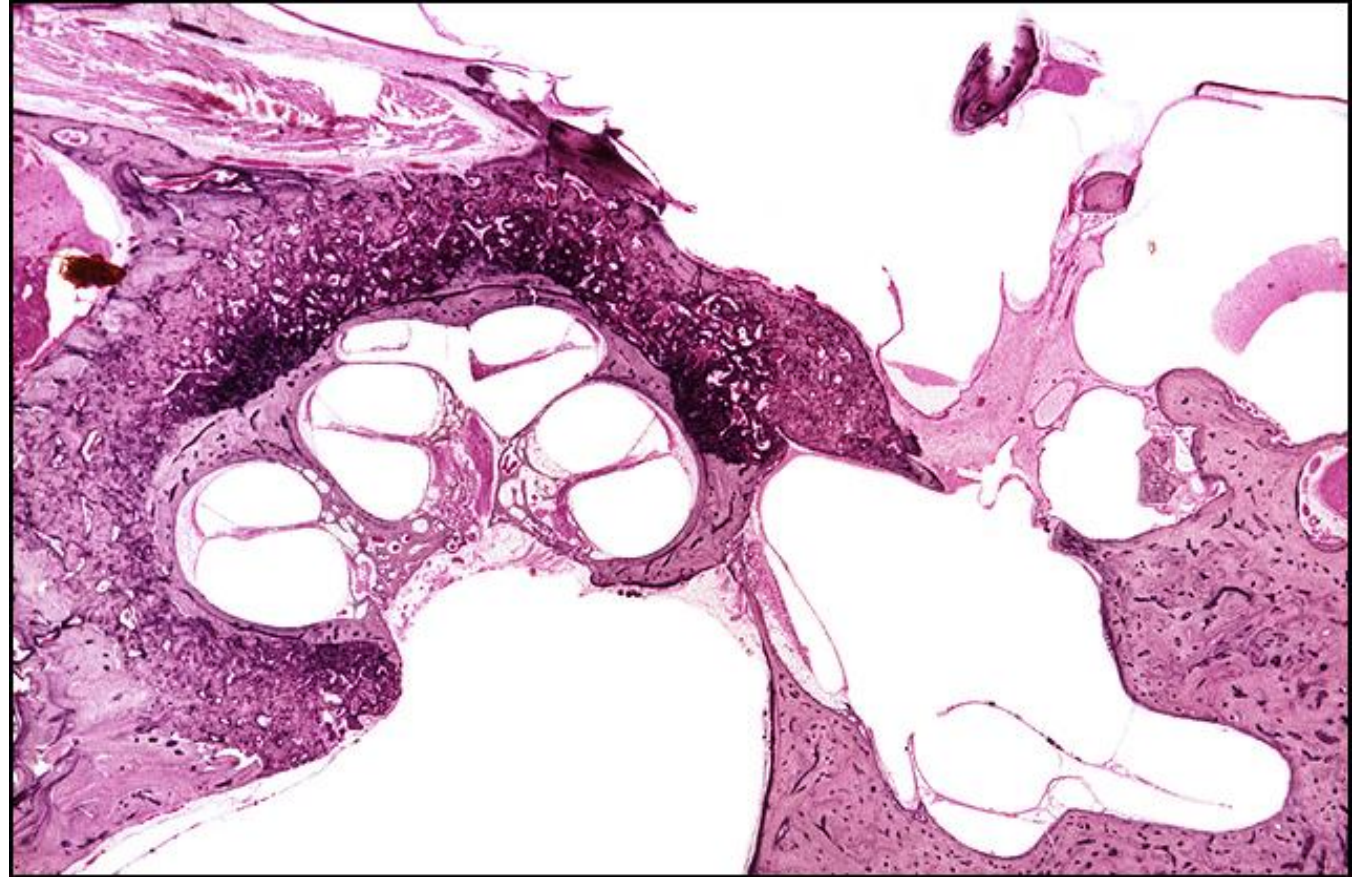
TB Case Number: 658

Gender: Male

Age (yrs.): 62

Otologic Diagnosis:

1. Otosclerosis, clinical, bilateral
2. Stapedectomy, insertion of gelfoam-wire prosthesis, right



Stapedectomy, Gel-wire Piston, R-234

Title: Stapedectomy, Gel-wire Piston, R-234

Chapter: Surgical Pathology

Chapter Section: Gelfoam and Wire, Stapedectomy, Surgery for Otosclerosis

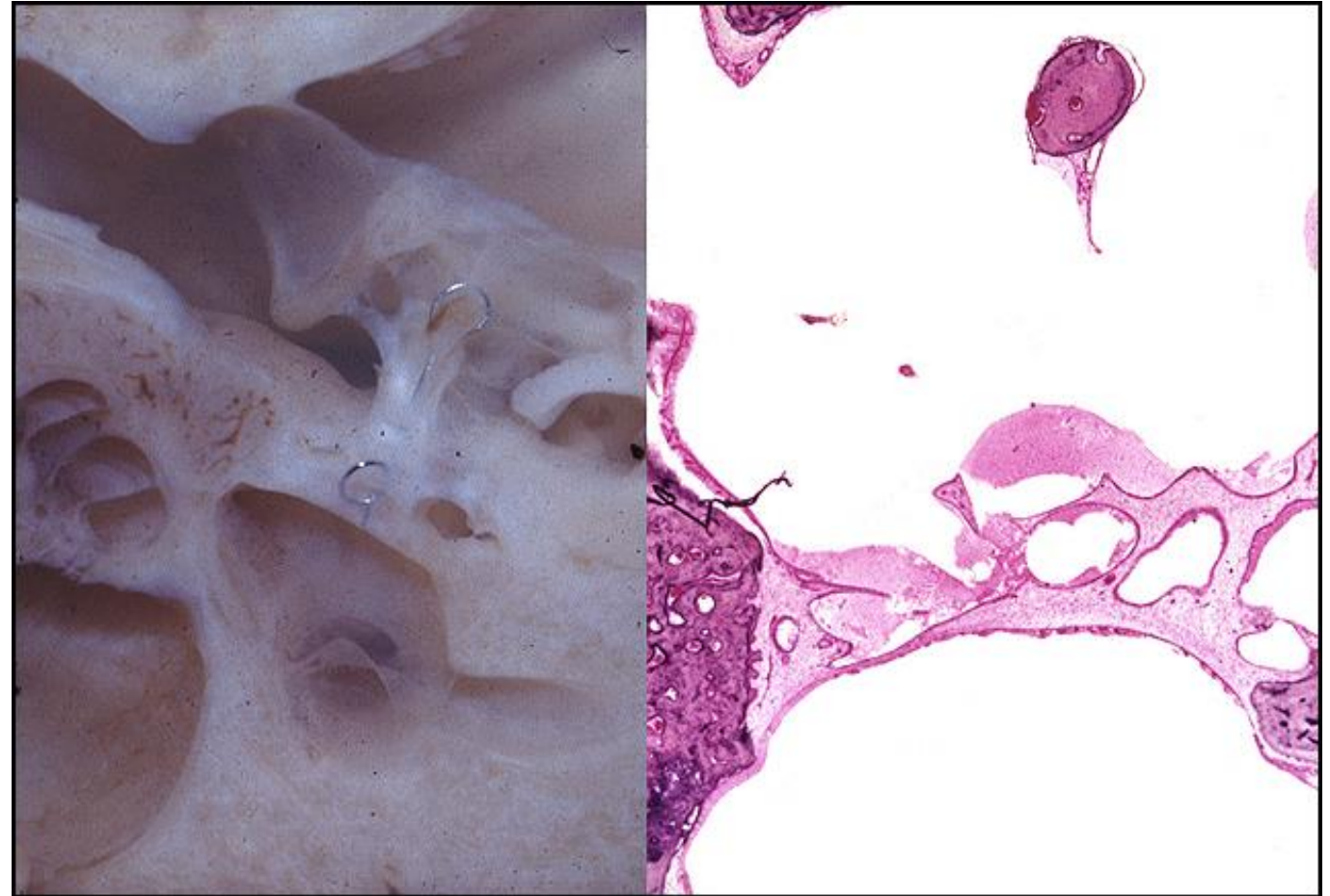
TB Case Number: 658

Gender: Male

Age (yrs.): 62

Otologic Diagnosis:

1. Otosclerosis, clinical, bilateral
2. Stapedectomy, insertion of gelfoam-wire prosthesis, right



Stapedectomy, Gel-wire Piston, R-105

Title: Stapedectomy, Gel-wire Piston, R-105

Chapter: Surgical Pathology

Chapter Section: Gelfoam and Wire,
Stapedectomy, Surgery for Otosclerosis

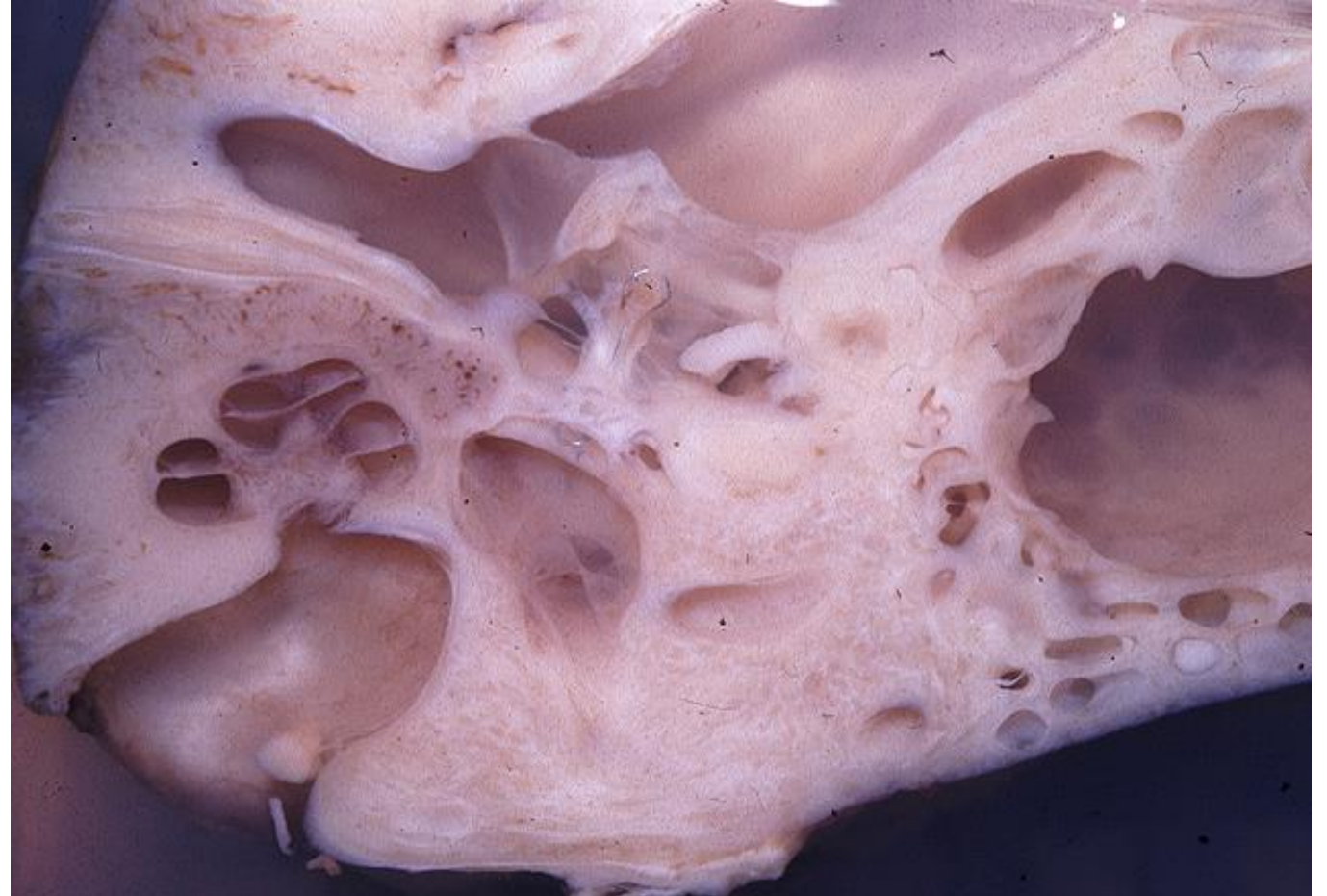TB Case Number: 658

Gender: Male

Age (yrs.): 62

Otologic Diagnosis:

1. Otosclerosis, clinical, bilateral
2. Stapedectomy, insertion of gelfoam-wire prosthesis, right



Stapedectomy, Gel-wire Piston, R-234

Title: Stapedectomy, Gel-wire Piston, R-234

Chapter: Surgical Pathology

Chapter Section: Gelfoam and Wire, Stapedectomy, Surgery for Otosclerosis

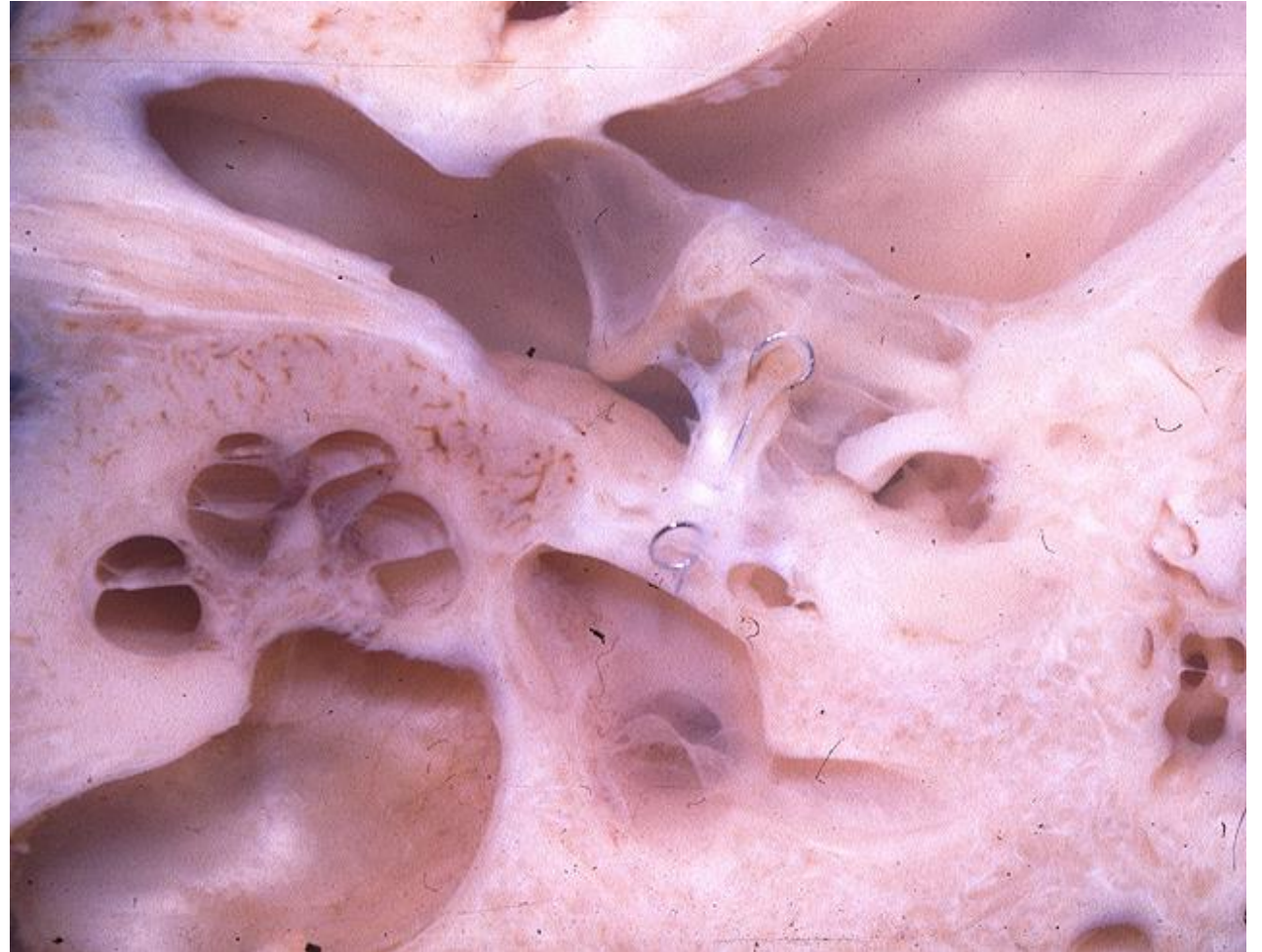TB Case Number: 658

Gender: Male

Age (yrs.): 62

Otologic Diagnosis:

1. Otosclerosis, clinical, bilateral
2. Stapedectomy, insertion of gelfoam-wire prosthesis, right



Mastoidectomy, L-241

Title: Mastoidectomy, L-241

Chapter: Surgical Pathology

Chapter Section: Tympanomastoid Surgery

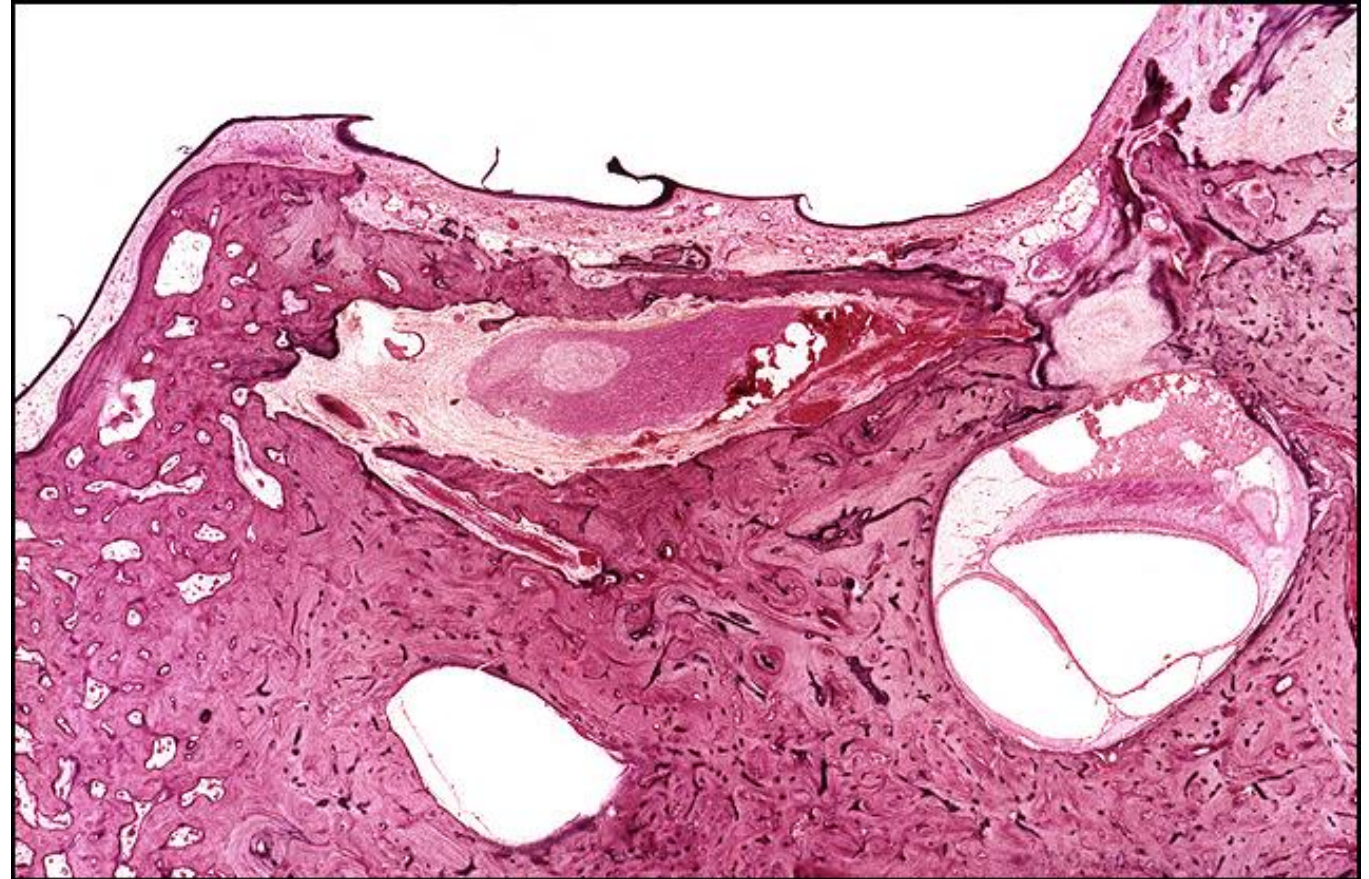
TB Case Number: 158

Gender: Female

Age (yrs.): 67

Otologic Diagnosis:

1. Subarachnoid hemorrhage
2. Otitis media, chronic, suppurative, bilateral
3. Mastoidectomy, modified radical, right
4. Mastoid bowl, granulations, right
5. Tympanic membrane, fibrosis, displacement, bilateral
6. Malleus, osseous fixation, chronic otitis media, right
7. Malleus and incus, resorptive osteitis, moderate
8. Mastoidectomy, radical, with skin graft, left



Mastoidectomy, R-148

Title: Mastoidectomy, R-148

Chapter: Surgical Pathology

Chapter Section: Tympanomastoid Surgery

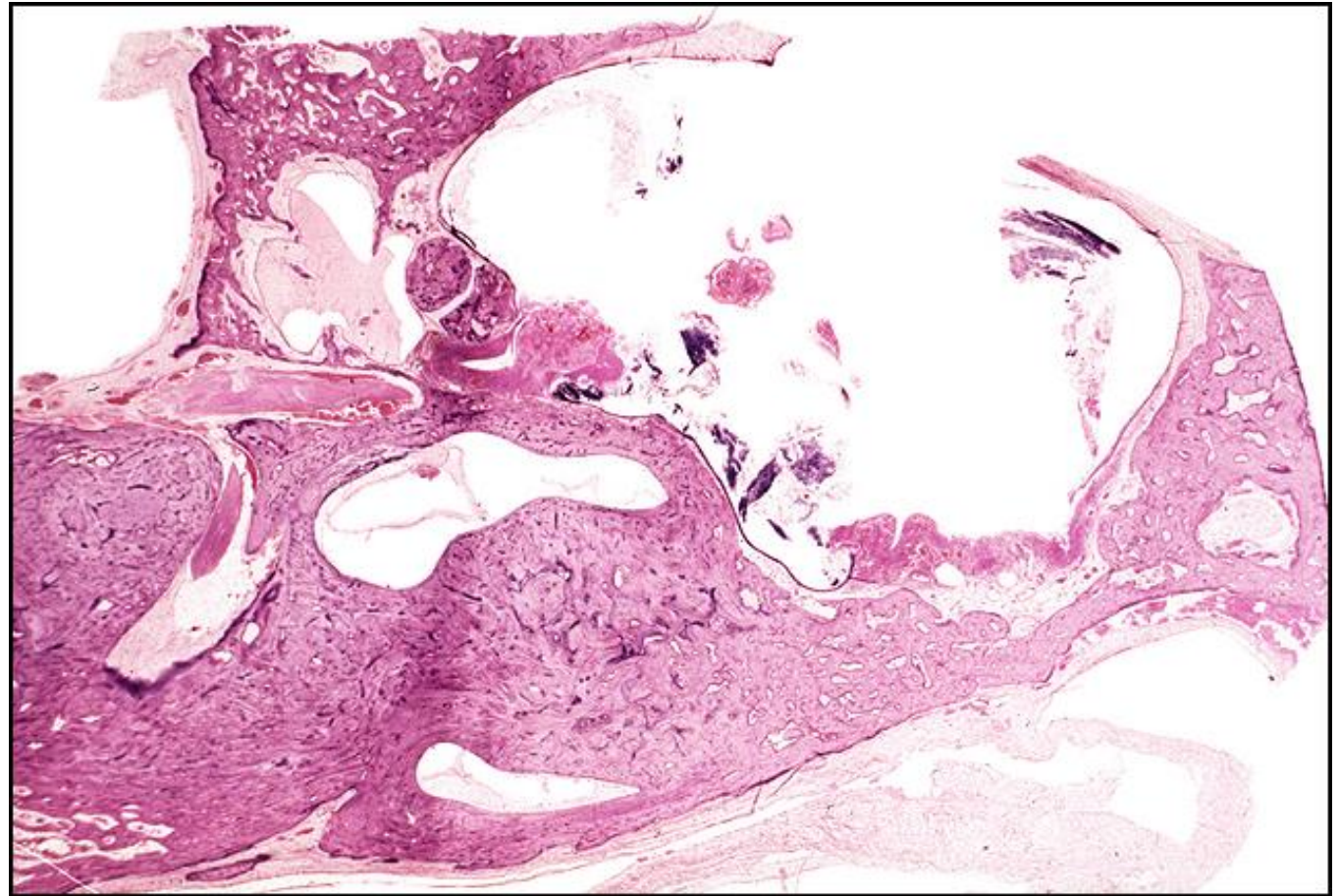
TB Case Number: 158

Gender: Female

Age (yrs.): 67

Otologic Diagnosis:

1. Subarachnoid hemorrhage
2. Otitis media, chronic, suppurative, bilateral
3. Mastoidectomy, modified radical, right
4. Mastoid bowl, granulations, right
5. Tympanic membrane, fibrosis, displacement, bilateral
6. Malleus, osseous fixation, chronic otitis media, right
7. Malleus and incus, resorptive osteitis, moderate
8. Mastoidectomy, radical, with skin graft, left



Mastoidectomy, L-331

Title: Mastoidectomy, L-331

Chapter: Surgical Pathology

Chapter Section: Tympanomastoid Surgery

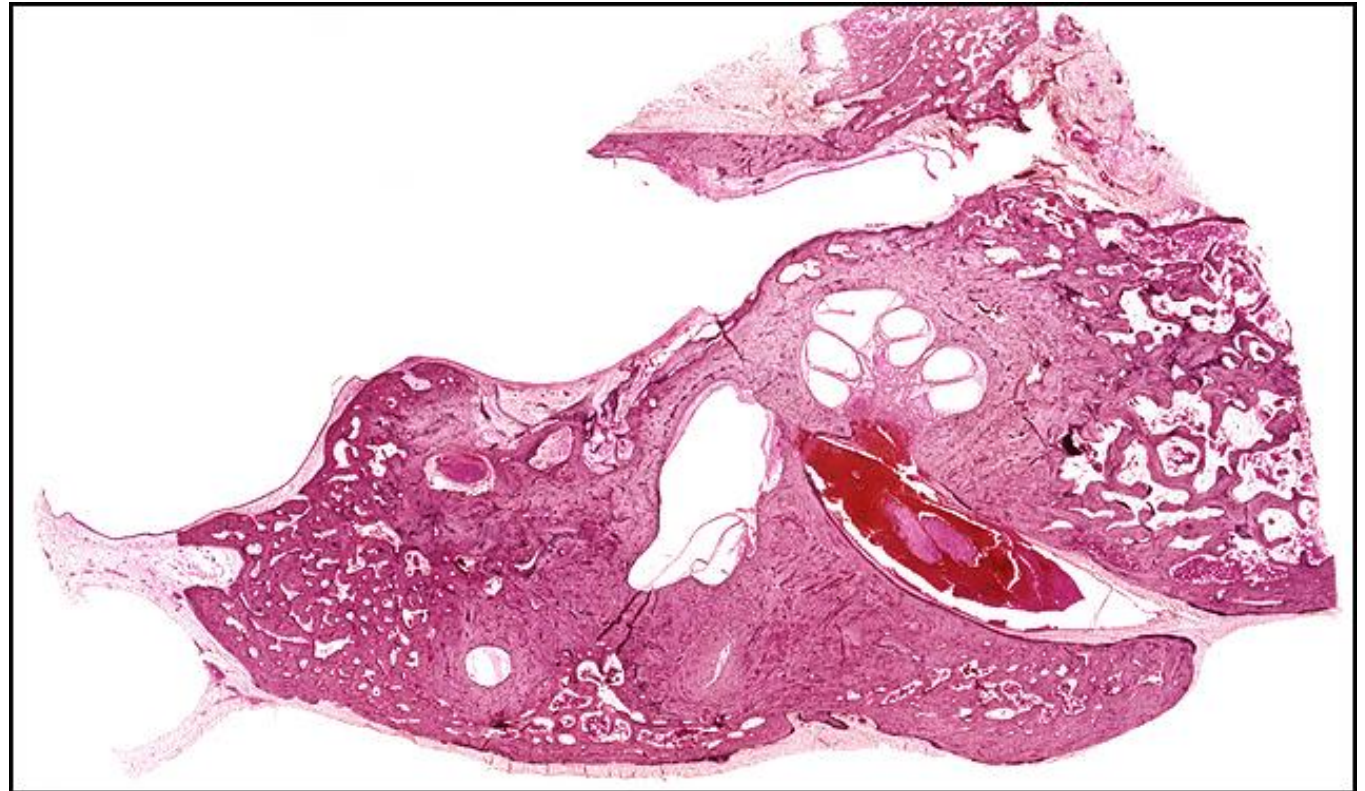
TB Case Number: 158

Gender: Female

Age (yrs.): 67

Otologic Diagnosis:

1. Subarachnoid hemorrhage
2. Otitis media, chronic, suppurative, bilateral
3. Mastoidectomy, modified radical, right
4. Mastoid bowl, granulations, right
5. Tympanic membrane, fibrosis, displacement, bilateral
6. Malleus, osseous fixation, chronic otitis media, right
7. Malleus and incus, resorptive osteitis, moderate
8. Mastoidectomy, radical, with skin graft, left



Mastoidectomy, L-501

Title: Mastoidectomy, L-501

Chapter: Surgical Pathology

Chapter Section: Tympanomastoid Surgery

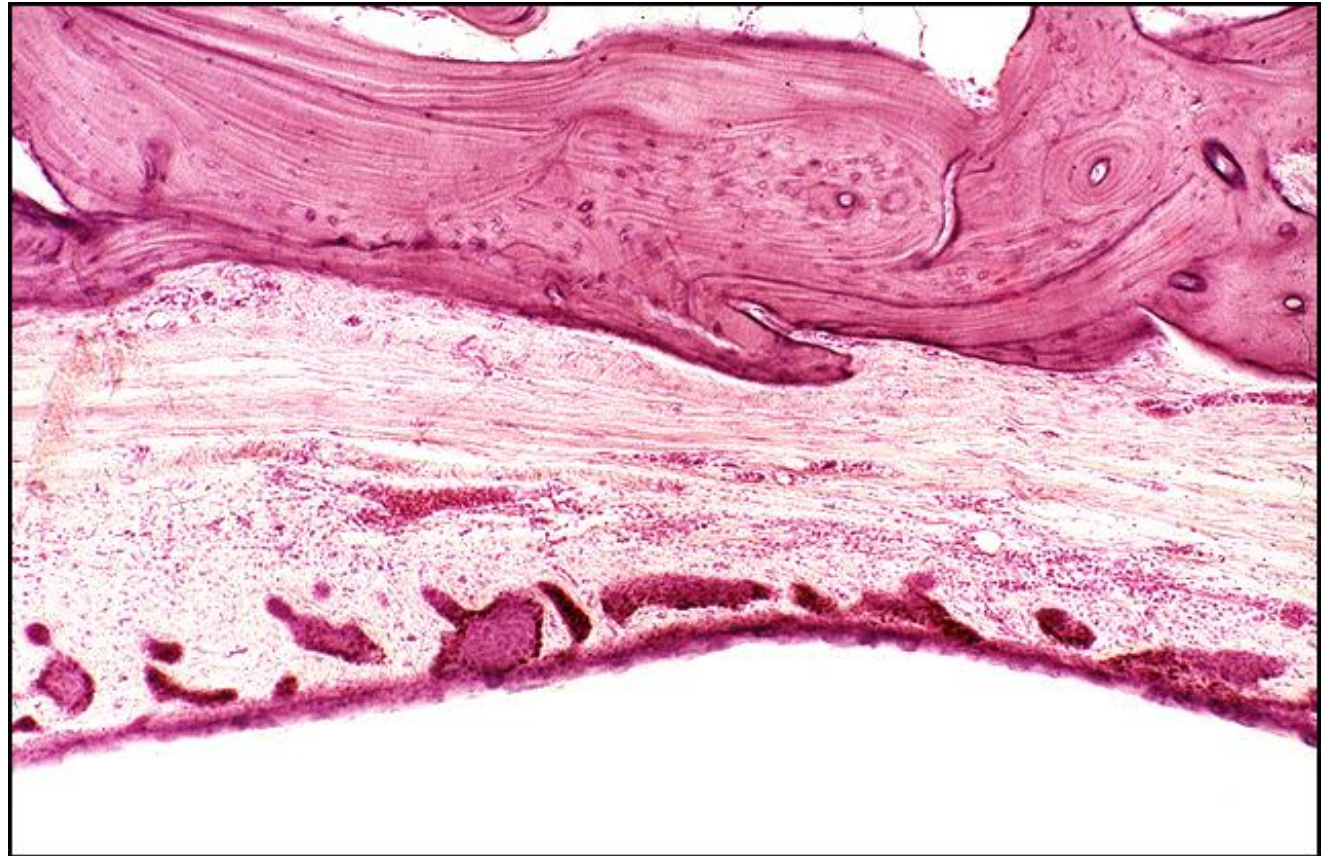
TB Case Number: 158

Gender: Female

Age (yrs.): 67

Otologic Diagnosis:

1. Subarachnoid hemorrhage
2. Otitis media, chronic, suppurative, bilateral
3. Mastoidectomy, modified radical, right
4. Mastoid bowl, granulations, right
5. Tympanic membrane, fibrosis, displacement, bilateral
6. Malleus, osseous fixation, chronic otitis media, right
7. Malleus and incus, resorptive osteitis, moderate
8. Mastoidectomy, radical, with skin graft, left
9. Mastoid bowl, postoperative, healed, left



Mastoidectomy, R-231

Title: Mastoidectomy, R-231

Chapter: Surgical Pathology

Chapter Section: Tympanomastoid Surgery

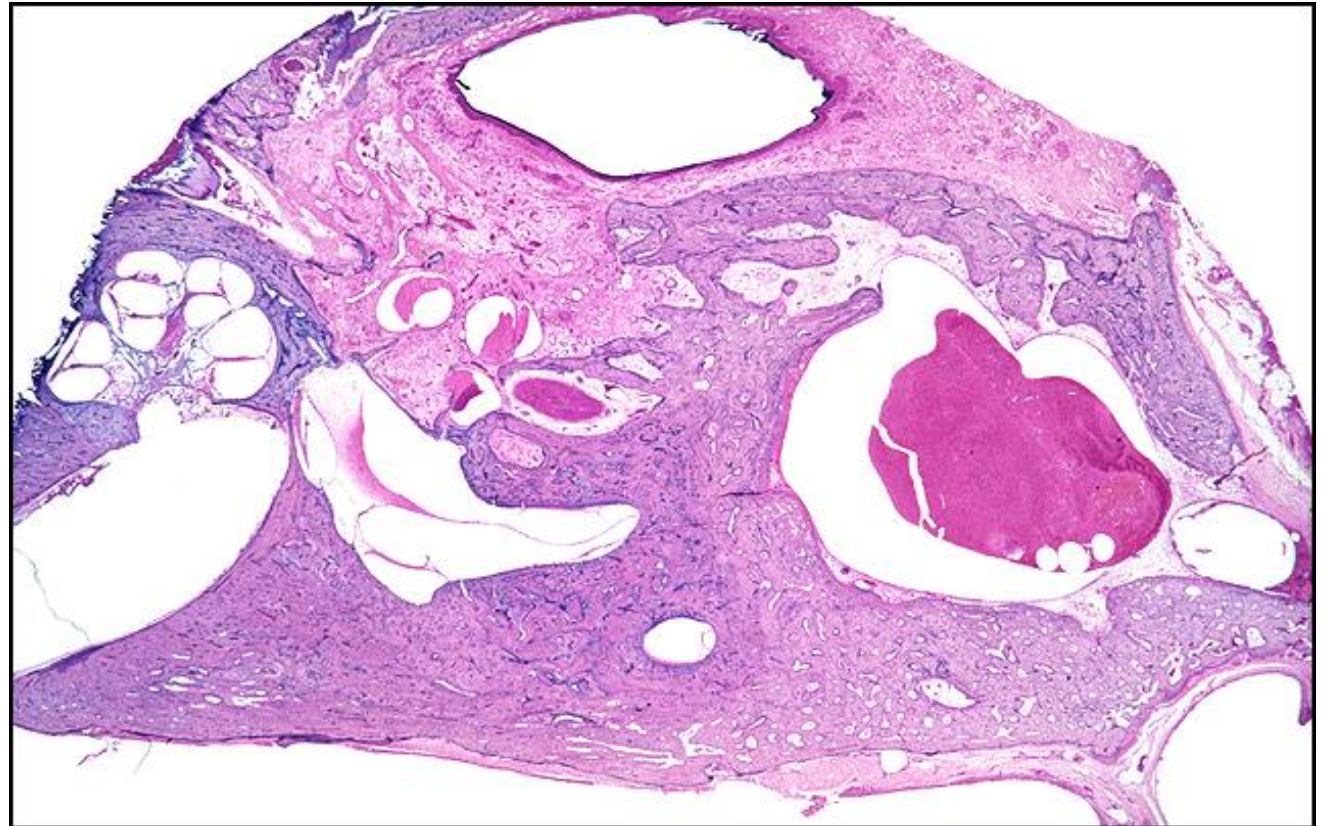
TB Case Number: 396

Gender: Male

Age (yrs.): 72

Otologic Diagnosis:

1. Status post simple mastoidectomy manifested by partial removal of lateral and posterior walls of mastoid bone, right
2. Surgical enlargement of the central mastoid tract, right
3. Fibrocystic sclerosis of the middle ear, right
4. Partial osteitic resorption of incus and malleus, right
5. Atrophy of the stria vascularis, moderately severe due to aging, left



Mastoidectomy, R-111

Title: Mastoidectomy, R-111

Chapter: Surgical Pathology

Chapter Section: Tympanomastoid Surgery

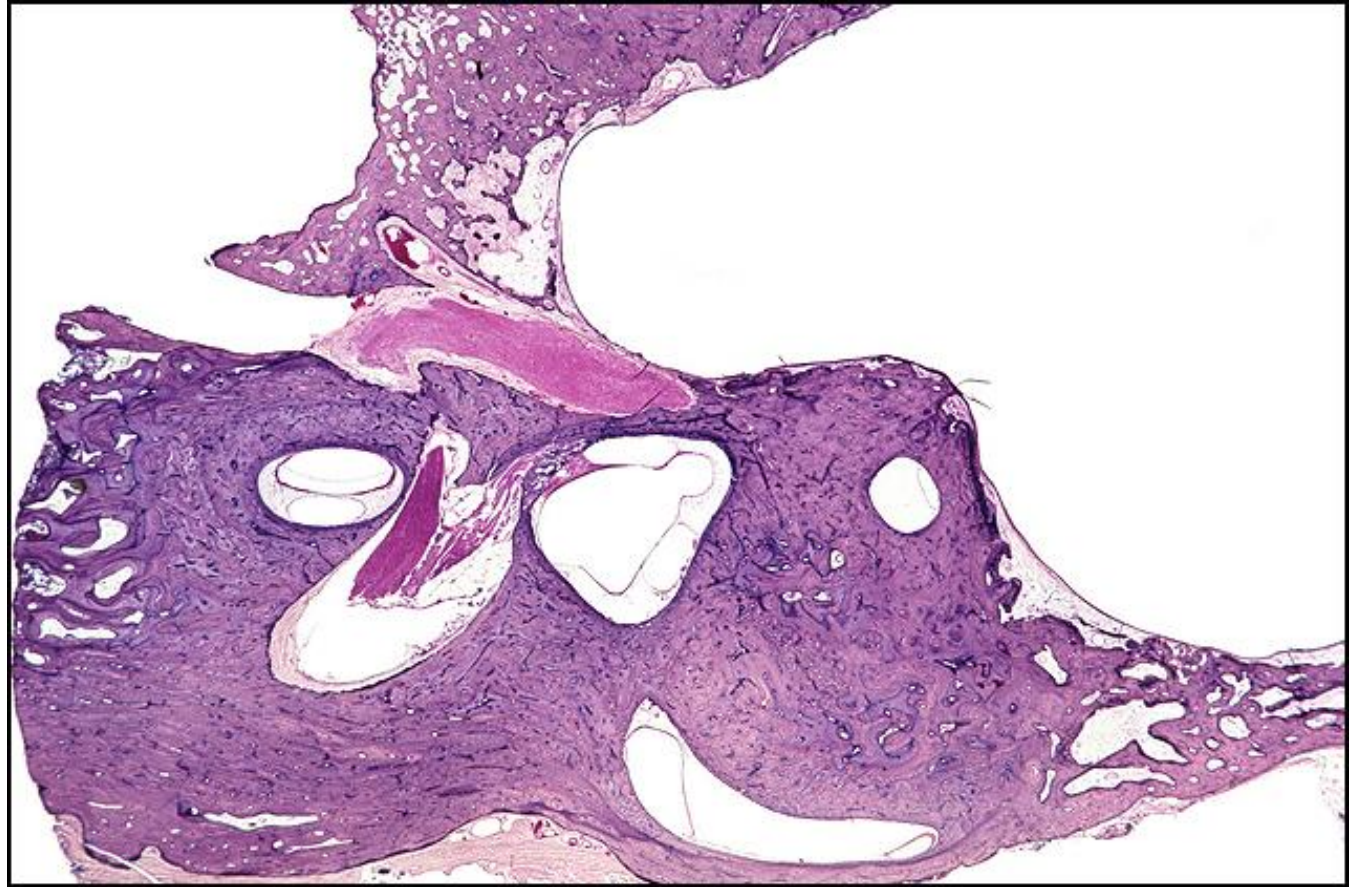
TB Case Number: 533

Gender: Male

Age (yrs.): 61

Otologic Diagnosis:

1. Cholesteatoma, by history, right
2. Radical mastoidectomy, at age 37, right
3. Radical mastoid cavity, well epithelialized, right
4. Facial nerve, dehiscence, at the oval window, bilateral
5. Facial nerve, dehiscence, anterior tympanic recess, right



Mastoidectomy, R-263

Title: Mastoidectomy, R-263

Chapter: Surgical Pathology

Chapter Section: Tympanomastoid Surgery

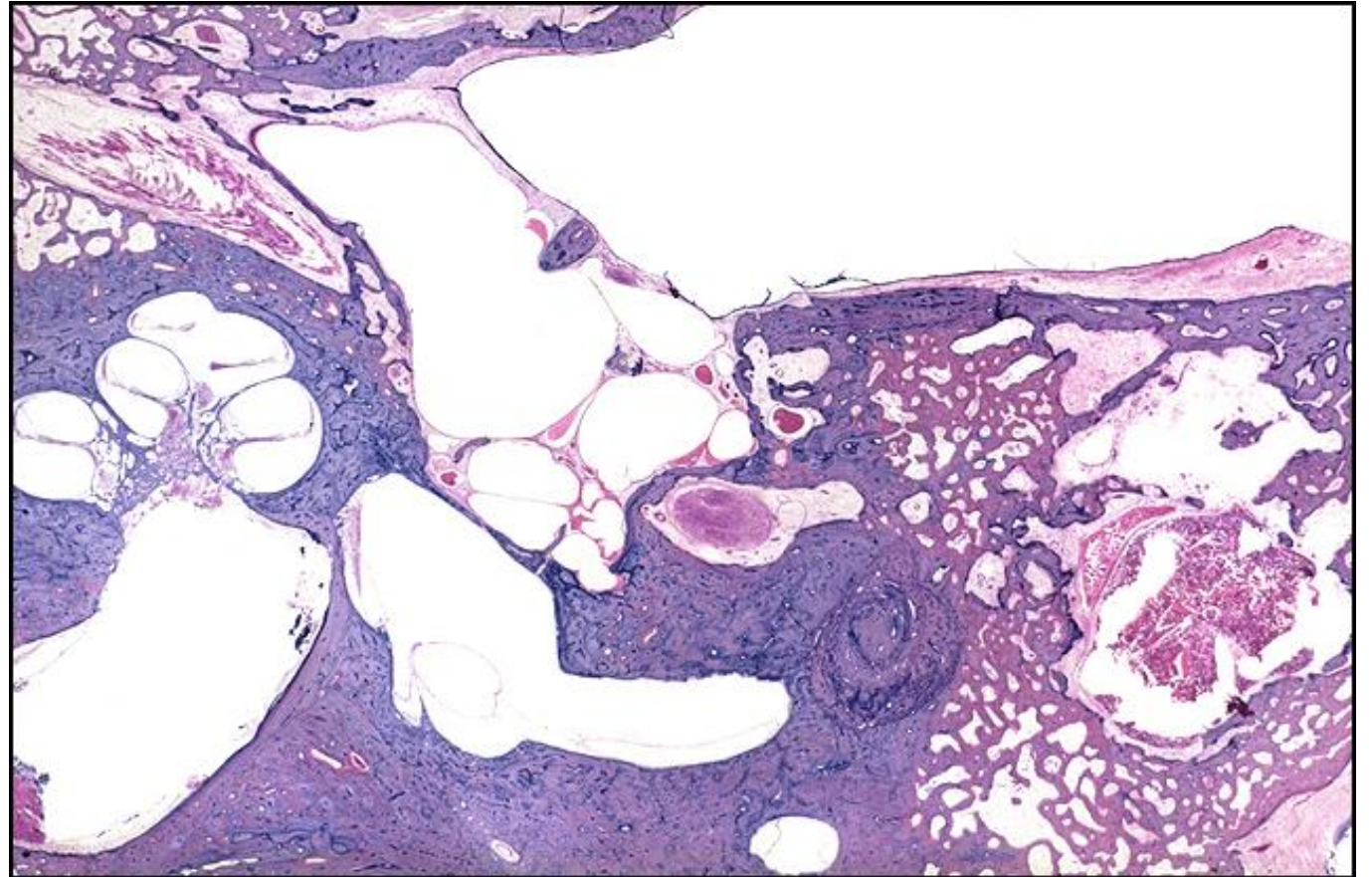
TB Case Number: 593

Gender: Male

Age (yrs.): 76

Otologic Diagnosis:

1. Otitis media, chronic, inactive, bilateral
2. Ossicles, partial resorption, right
3. Round and oval windows, fibrocystic obliteration, bilateral
4. Mastoidectomy, radical, with obliteration pedicle graft, left
5. Bony labyrinth, partial resorption, causing fistula of semicircular canal, left
6. Bony labyrinth, partial resorption, inactive, healed, right



Mastoidectomy, L-151

Title: Mastoidectomy, L-151

Chapter: Surgical Pathology

Chapter Section: Tympanomastoid Surgery

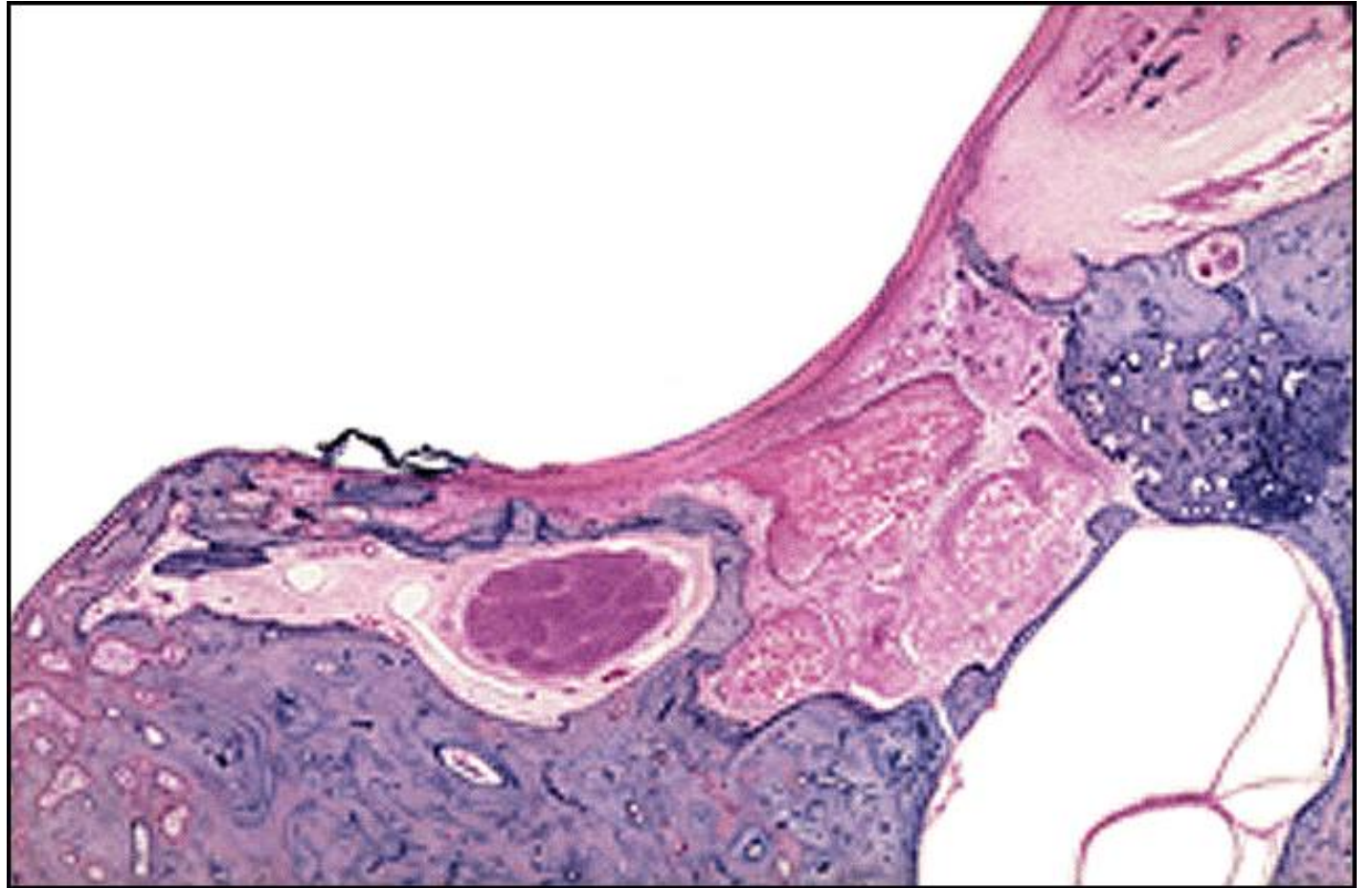
TB Case Number: 593

Gender: Female

Age (yrs.): 76

Otologic Diagnosis:

1. Otitis media, chronic, inactive, bilateral
2. Ossicles, partial resorption, right
3. Round and oval windows, fibrocystic obliteration, bilateral
4. Mastoidectomy, radical, with obliteration pedicle graft, left
5. Bony labyrinth, partial resorption, causing fistula of semicircular canal, left
6. Bony labyrinth, partial resorption, inactive, healed, right



Mastoidectomy, L-351

Title: Mastoidectomy, L-351

Chapter: Surgical Pathology

Chapter Section: Tympanomastoid Surgery

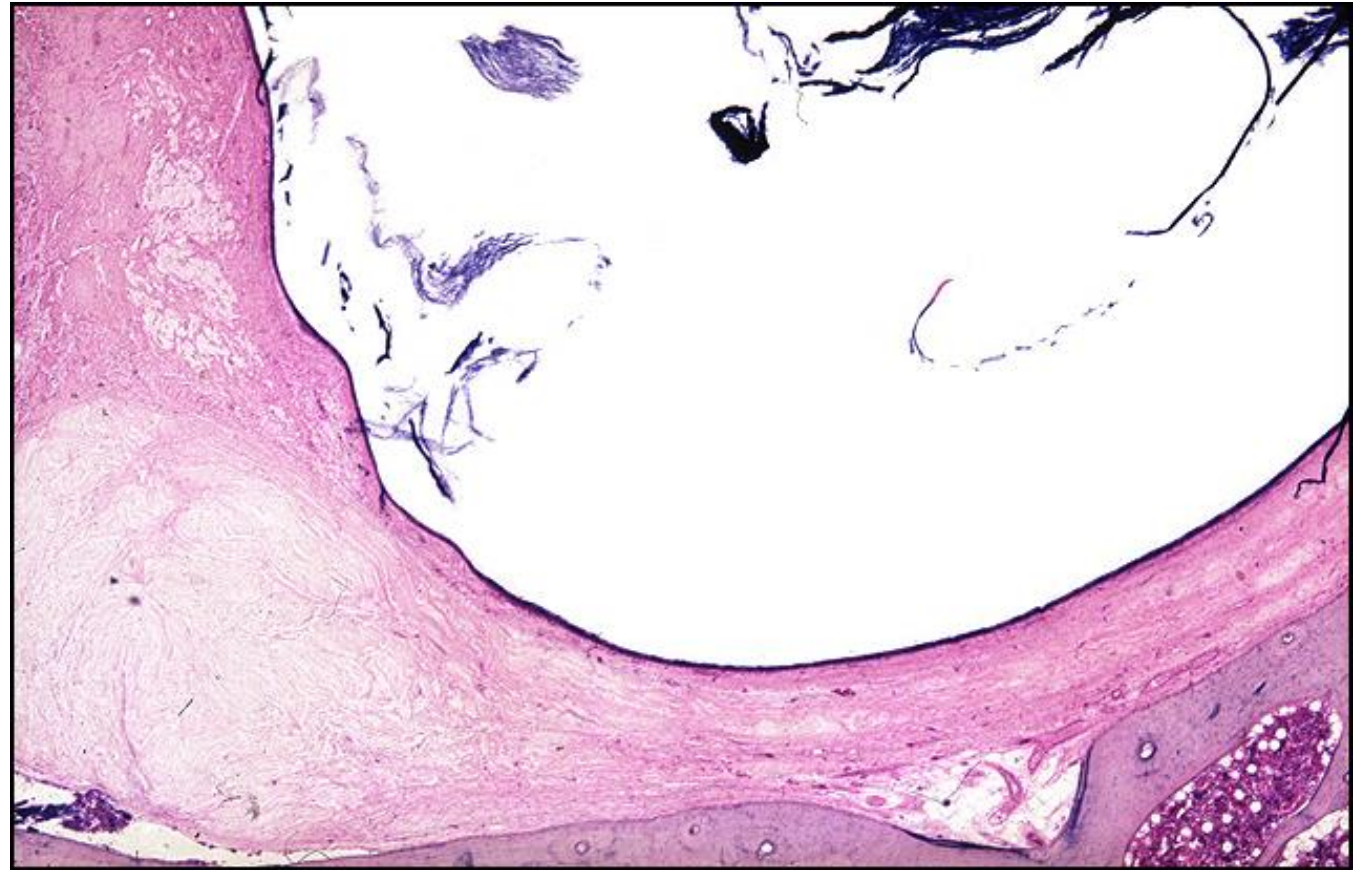TB Case Number: 593

Gender: Female

Age (yrs.): 76

Otologic Diagnosis:

1. Otitis media, chronic, inactive, bilateral
2. Ossicles, partial resorption, right
3. Round and oval windows, fibrocystic obliteration, bilateral
4. Mastoidectomy, radical, with obliteration pedicle graft, left
5. Bony labyrinth, partial resorption, causing fistula of semicircular canal, left
6. Bony labyrinth, partial resorption, inactive, healed, right



Mastoidectomy, L-151

Title: Mastoidectomy, L-151

Chapter: Surgical Pathology

Chapter Section: Tympanomastoid Surgery

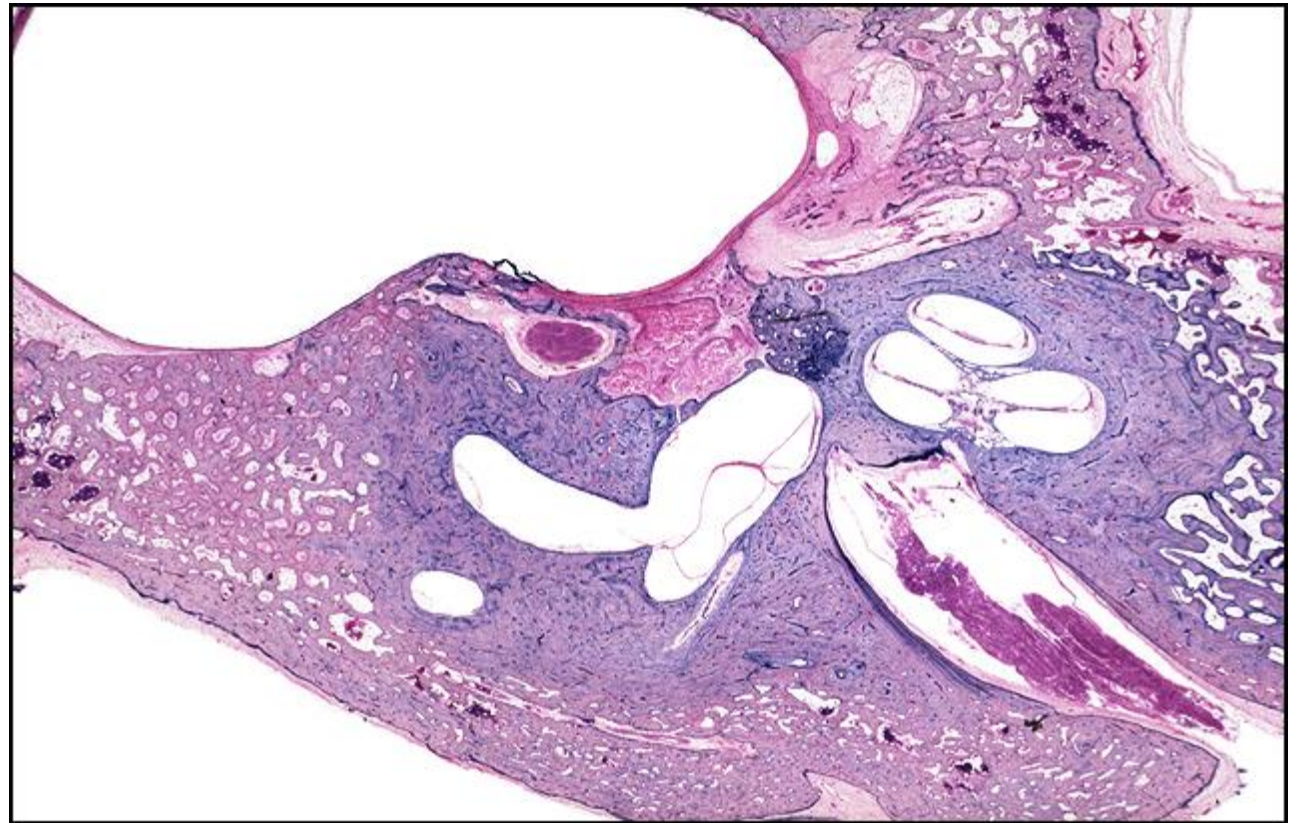
TB Case Number: 593

Gender: Female

Age (yrs.): 76

Otologic Diagnosis:

1. Otitis media, chronic, inactive, bilateral
2. Ossicles, partial resorption, right
3. Round and oval windows, fibrocystic obliteration, bilateral
4. Mastoidectomy, radical, with obliteration pedicle graft, left
5. Bony labyrinth, partial resorption, causing fistula of semicircular canal, left
6. Bony labyrinth, partial resorption, inactive, healed, right



Mastoidectomy, L-371

Title: Mastoidectomy, L-371

Chapter: Surgical Pathology

Chapter Section: Tympanomastoid Surgery

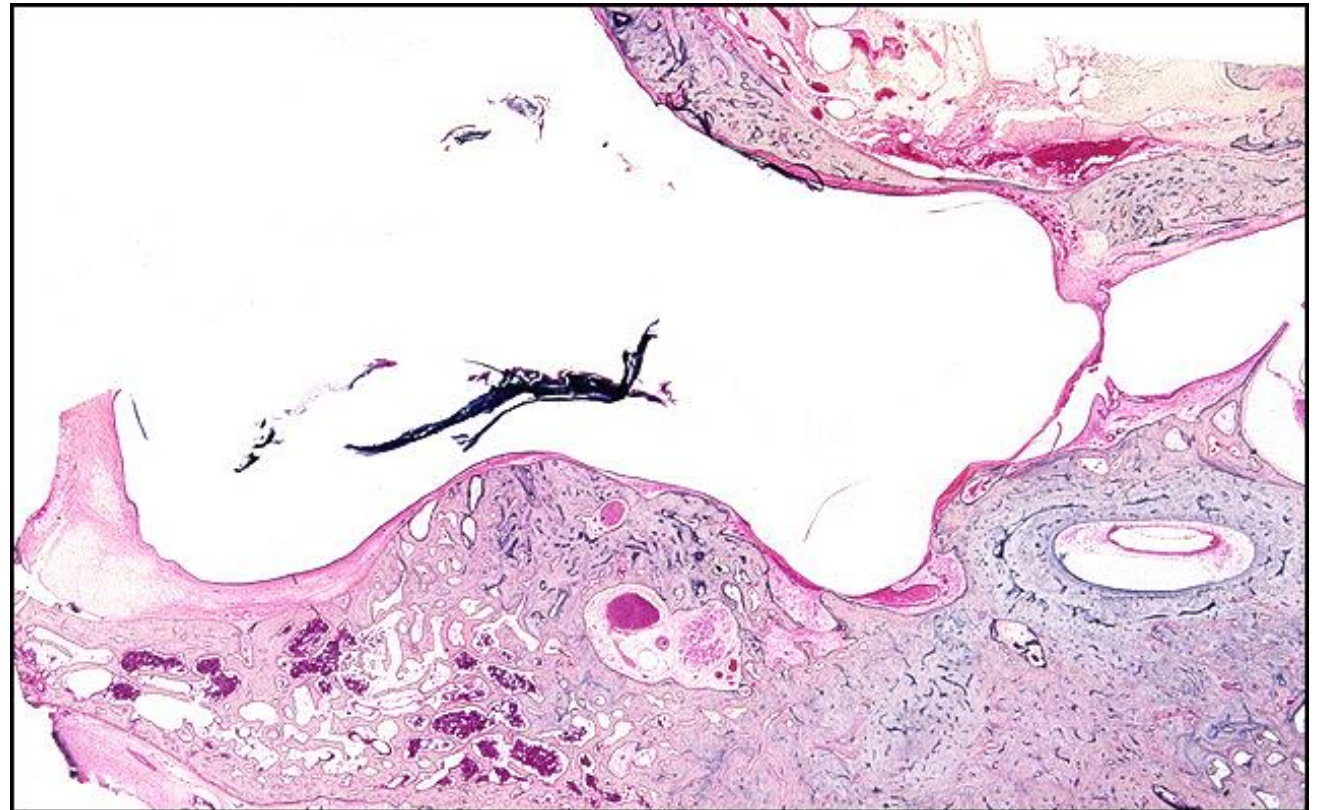
TB Case Number: 593

Gender: Female

Age (yrs.): 76

Otologic Diagnosis:

1. Otitis media, chronic, inactive, bilateral
2. Ossicles, partial resorption, right
3. Round and oval windows, fibrocystic obliteration, bilateral
4. Mastoidectomy, radical, with obliteration pedicle graft, left
5. Bony labyrinth, partial resorption, causing fistula of semicircular canal, left
6. Bony labyrinth, partial resorption, inactive, healed, right



Mastoidectomy, L-325

Title: Mastoidectomy, L-325

Chapter: Surgical Pathology

Chapter Section: Tympanomastoid Surgery

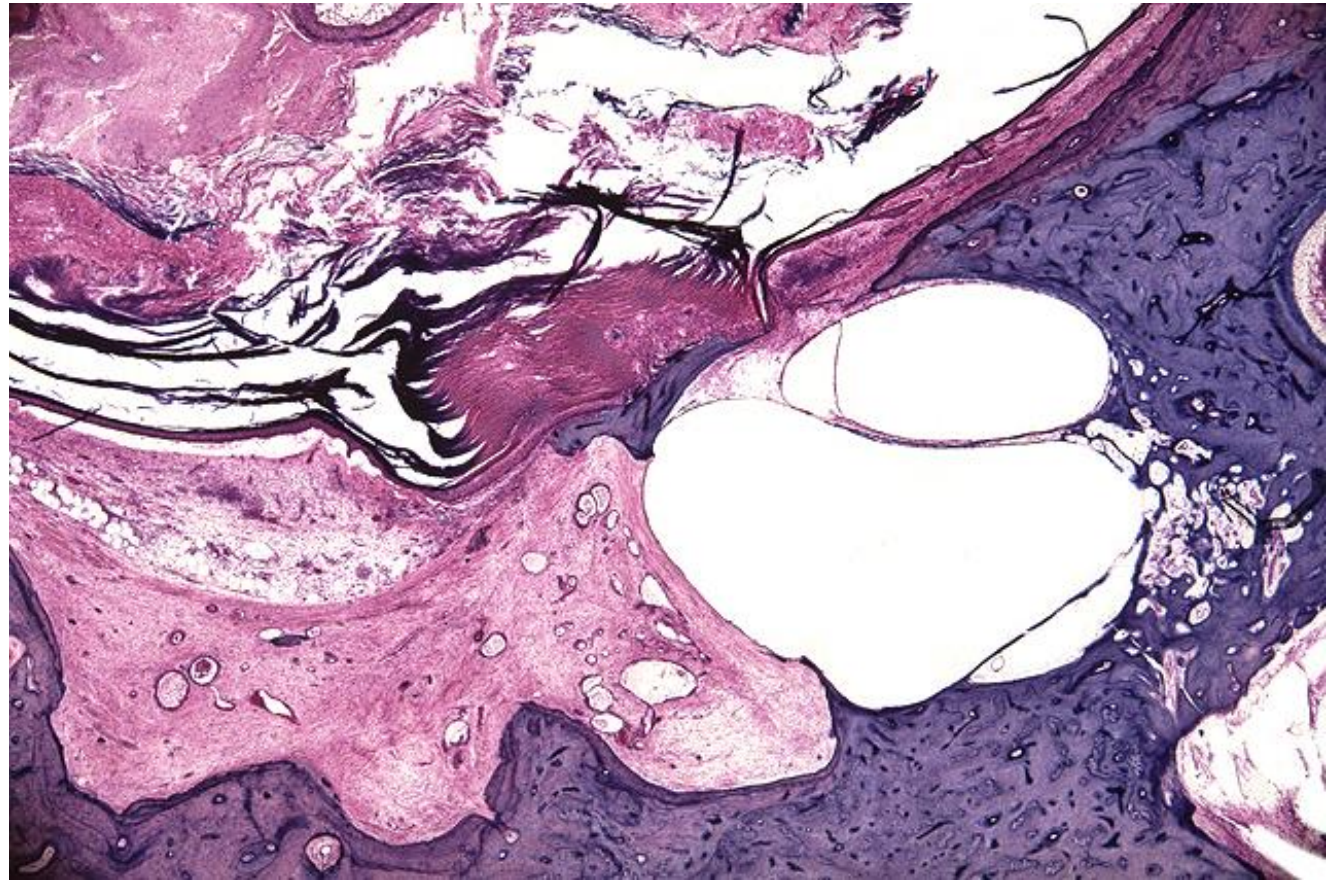
TB Case Number: 830

Gender: Male

Age (yrs.): 71

Otologic Diagnosis:

1. Otitis media, chronic, suppurative, bilateral
2. Mastoiditis, bilateral
3. Mastoidectomy, radical, with keratin-fungal mass filling tympanomastoid area, left
4. Fistula, pathologic, promontory, left
5. Infraction, surgical, lateral semicircular canal, left
6. Vestibular nerve, atrophy (vestibular neuritis), horizontal segment of ampullary branch



Mastoidectomy, L-216

Title: Mastoidectomy, L-216

Chapter: Surgical Pathology

Chapter Section: Tympanomastoid Surgery

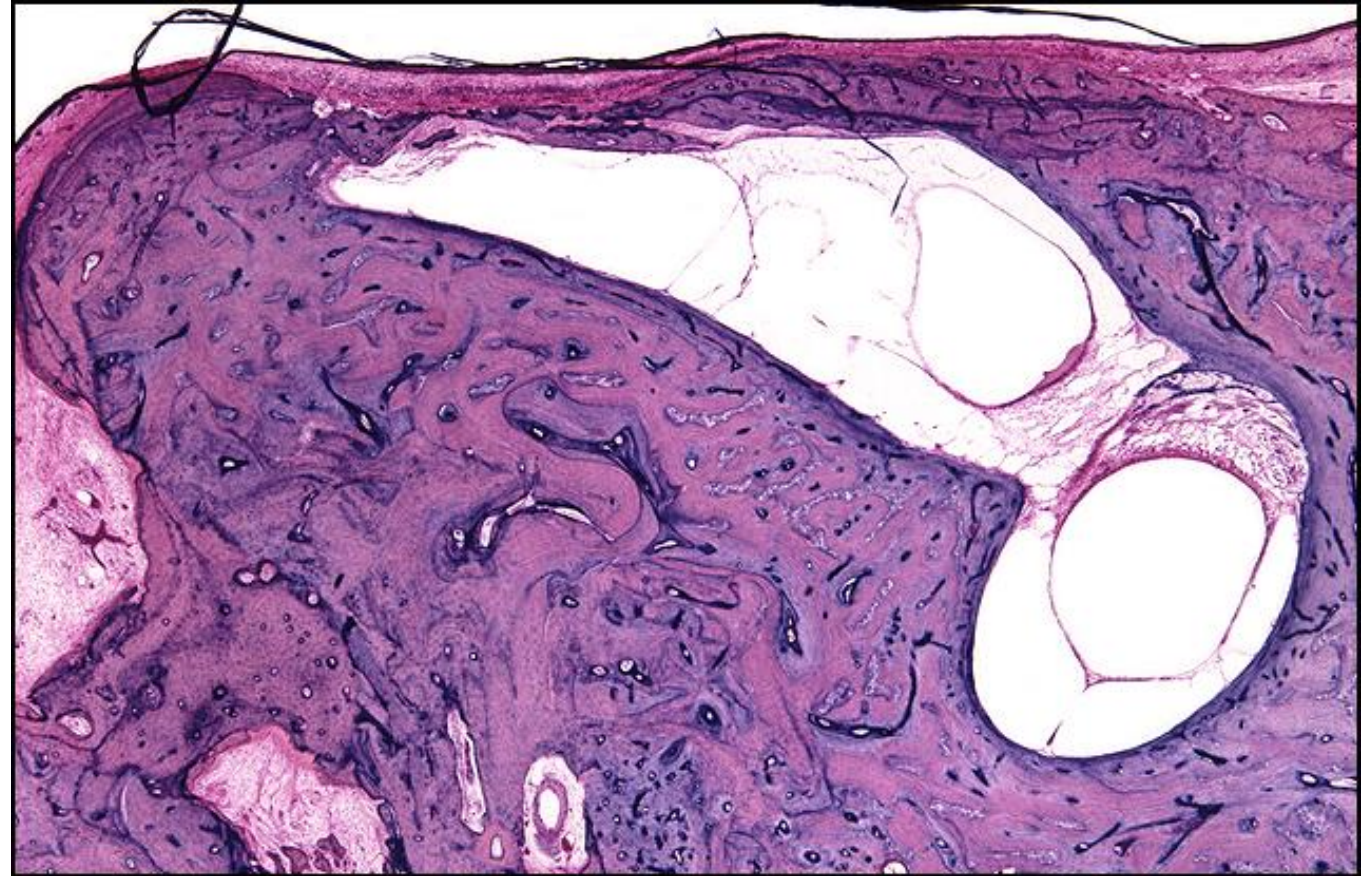
TB Case Number: 830

Gender: Male

Age (yrs.): 71

Otologic Diagnosis:

1. Otitis media, chronic, suppurative, bilateral
2. Mastoiditis, bilateral
3. Mastoidectomy, radical, with keratin-fungal mass filling tympanomastoid area, left
4. Fistula, pathologic, promontory, left
5. Infraction, surgical, lateral semicircular canal, left
6. Vestibular nerve, atrophy (vestibular neuritis), horizontal segment of ampullary branch



Radical Mastoidectomy, R-210

Title: Radical Mastoidectomy, R-210

Chapter: Surgical Pathology

Chapter Section: Tympanomastoid Surgery

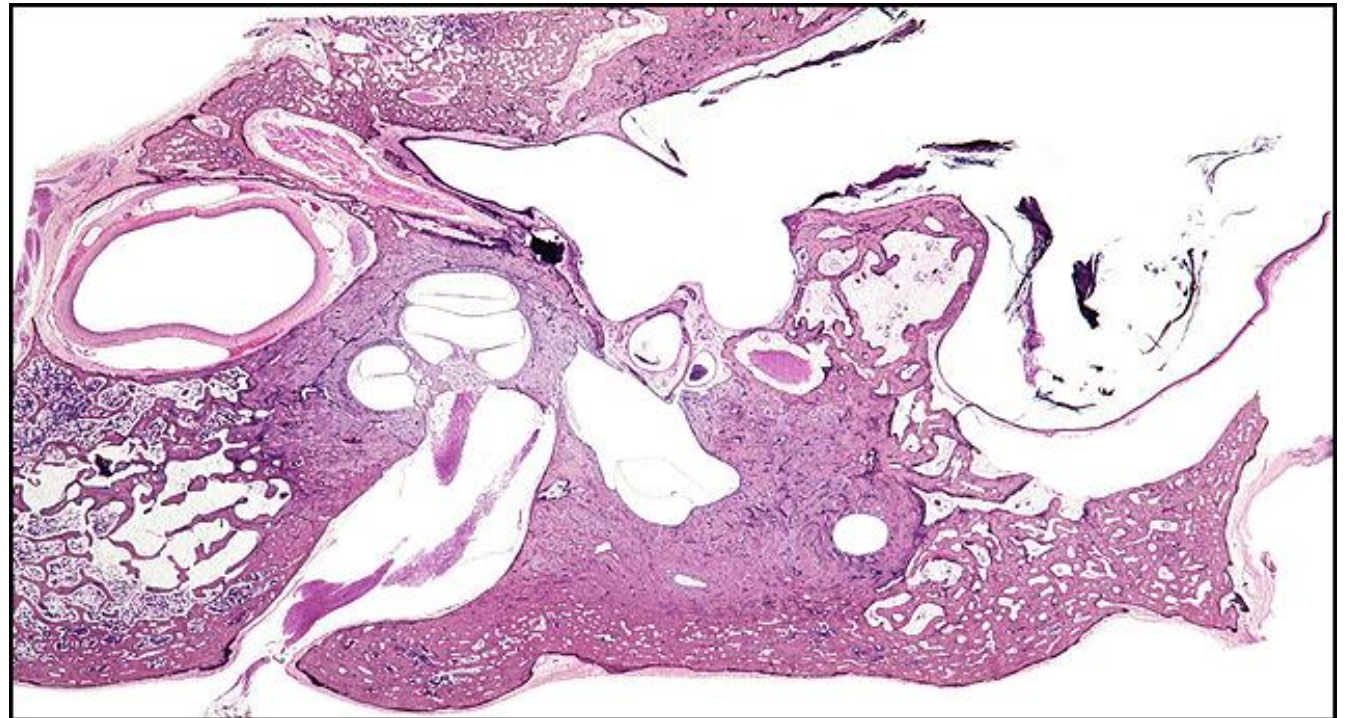
TB Case Number: 635

Gender: Female

Age (yrs.): 70

Otologic Diagnosis:

1. Mastoidectomy, modified radical, right
2. Mastoidectomy, simple, left
3. Osteitis, resorptive, ossicles, partial, bilateral
4. Fibrocystic proliferation and obliteration, mastoid, left
5. Atrophy, chorda tympani nerve, surgically induced, bilateral
6. Membranous labyrinths, normal, bilateral



Simple Mastoidectomy, L-191

Title: Simple Mastoidectomy, L-191

Chapter: Surgical Pathology

Chapter Section: Tympanomastoid Surgery

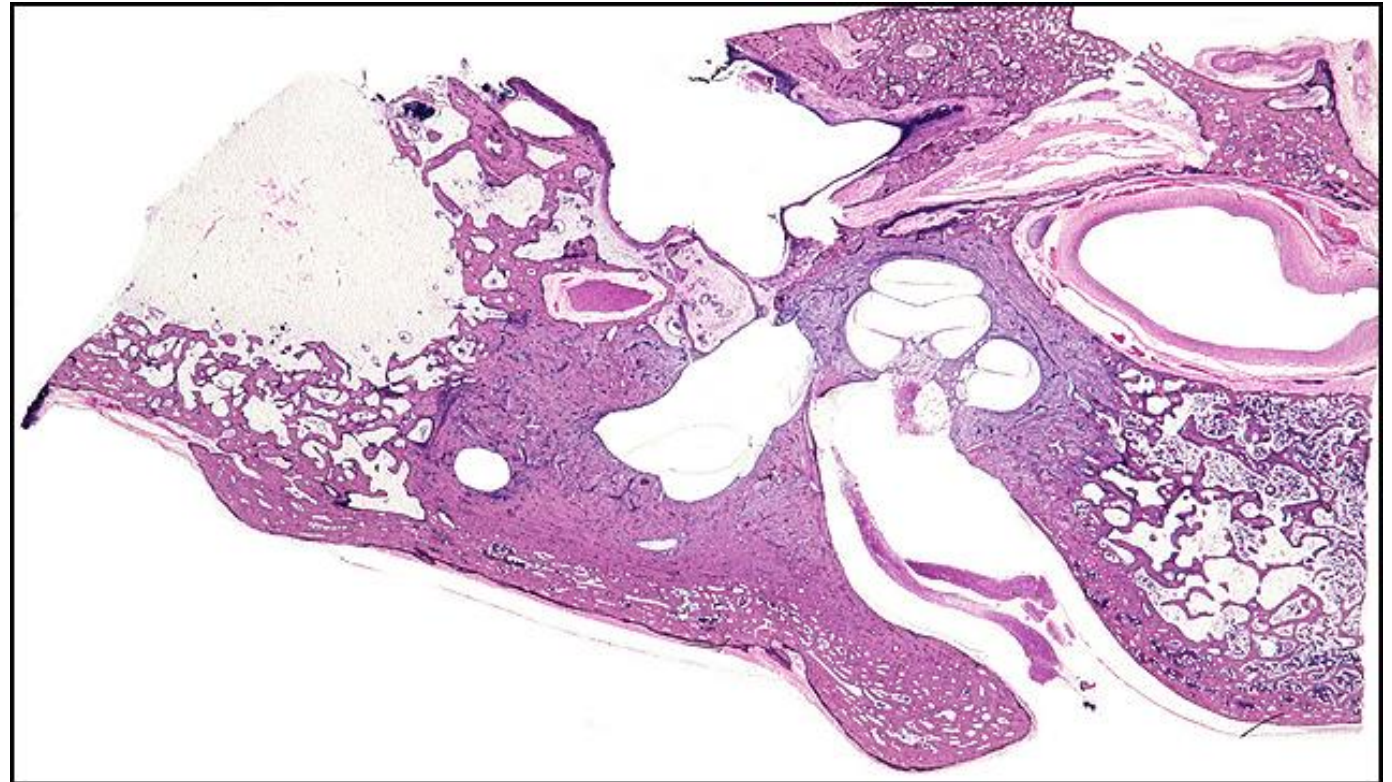TB Case Number: 635

Gender: Female

Age (yrs.): 70

Otologic Diagnosis:

1. Mastoidectomy, modified radical, right
2. Mastoidectomy, simple, left
3. Osteitis, resorptive, ossicles, partial, bilateral
4. Fibrocystic proliferation and obliteration, mastoid, left
5. Atrophy, chorda tympani nerve, surgically induced, bilateral
6. Membranous labyrinths, normal, bilateral



Mastoidectomy, Stapes, L-157

Title: Mastoidectomy, Stapes, L-157

Chapter: Surgical Pathology

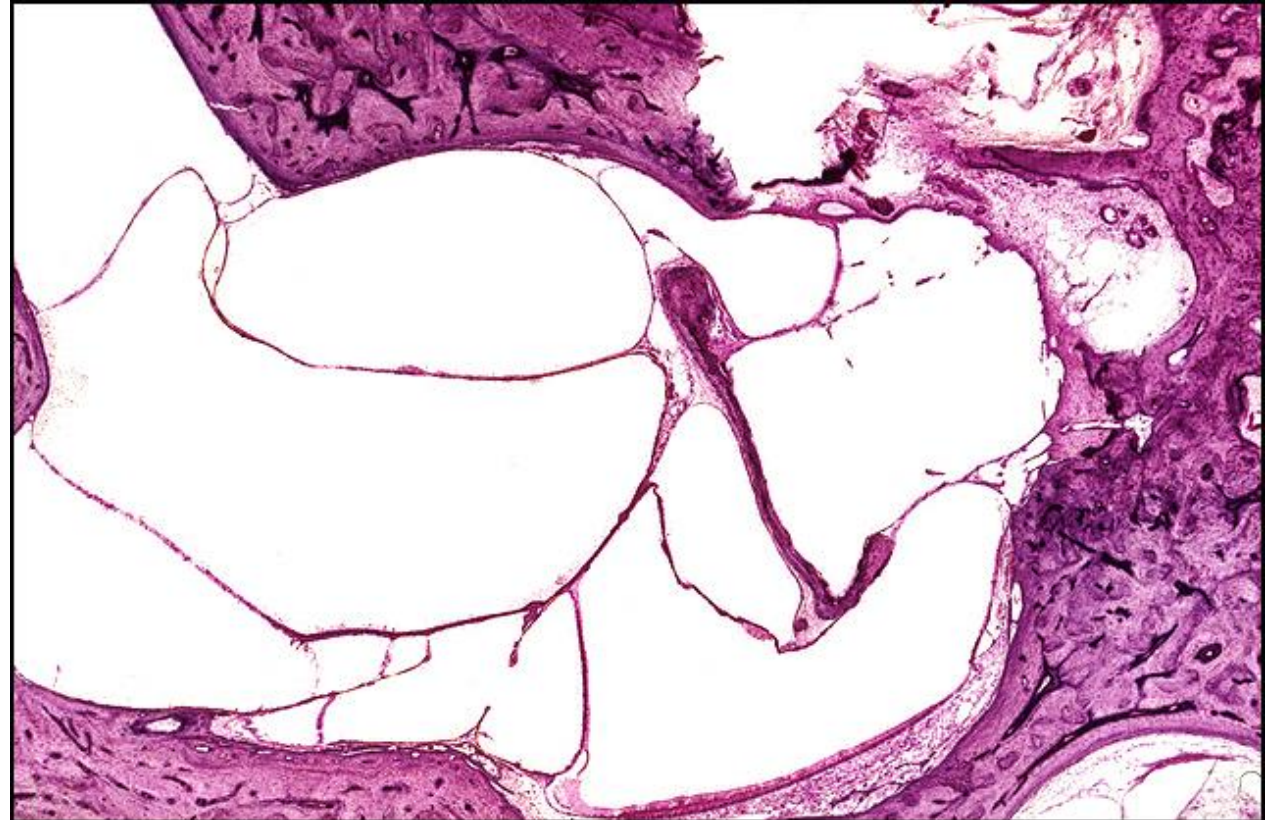
Chapter Section: Tympanomastoid Surgery

TB Case Number: 296

Gender: Male **Age (yrs.):** 55

Otologic Diagnosis:

1. Tympanomastoiditis, chronic, suppurative, left
2. Cholesteatoma, acquired, mastoid, left
3. Epidermization, middle ear, left
4. Ossiculoplasty, details unknown, left
5. Mastoidectomy, radical (age 42), left
6. Fistula, surgical, lateral canal, left
7. Stapes, luxation into vestibule, surgical, left
8. Mastoid bowl, surgical, healed, left
9. Organ of Corti, atrophy, iatrogenic, left
10. Neurons, atrophy, iatrogenic, left
11. Niche, round window, fibrous obliteration, left
12. Artifact, removal, fistulization, cochlea, left
13. Artifact, preparation, membranous labyrinth, folds, tears, creeping, left



Intact Canal Wall Tymp, R-371

Title: Intact Canal Wall Tymp, R-371

Chapter: Surgical Pathology

Chapter Section: Tympanomastoid Surgery

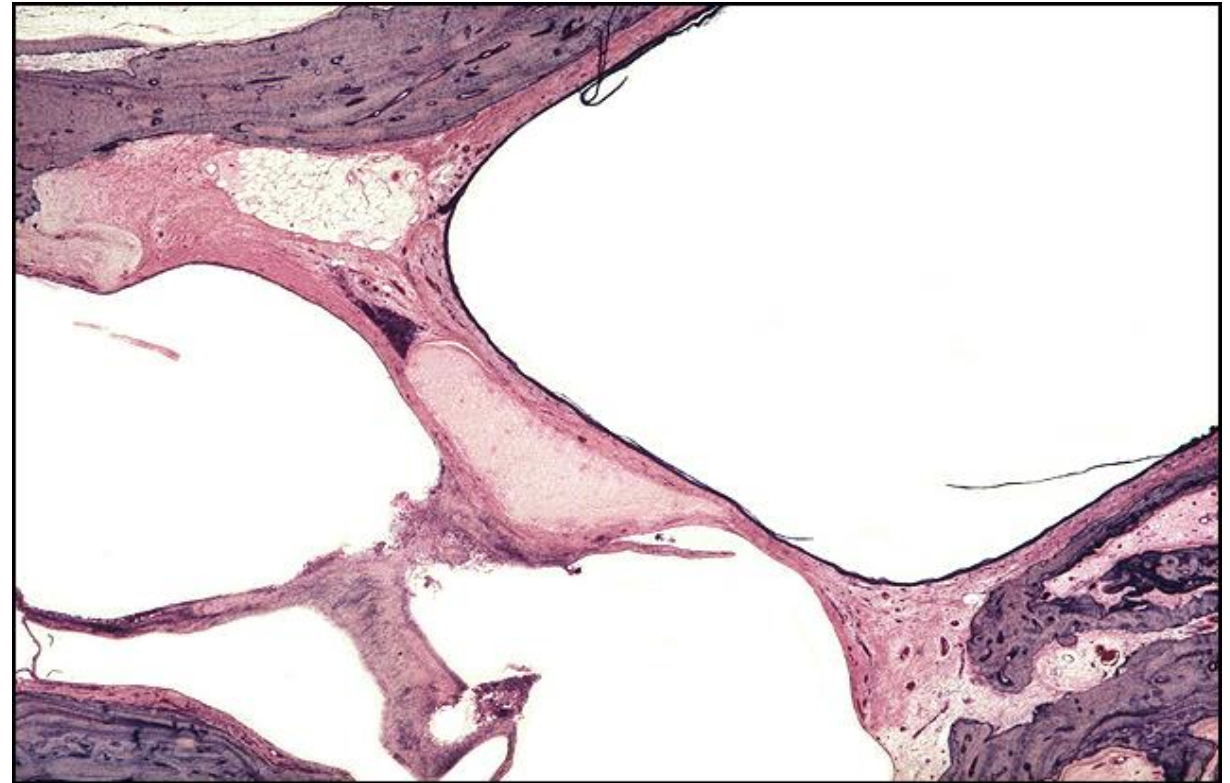TB Case Number: 440

Gender: Male

Age (yrs.): 62

Otologic Diagnosis:

1. Chronic otitis media, inactive, bilateral
2. Intact canal wall tympanomastoidectomy, showing posterior tympanotomy, fascial graft myringoplasty, cartilage graft, and Silastic implant, right
3. Devitalization and partial resorption of cartilage implant, right
4. Retraction and perforation of tympanic membrane, left
5. Fibrocystic and osseous obliteration, mastoid, left
6. Mild patchy atrophy of the stria vascularis, bilateral
7. Neural atrophy, mild, basal turns (neural presbycusis), bilateral



Intact Canal Wall Tymp, R-271

Title: Intact Canal Wall Tymp, R-271

Chapter: Surgical Pathology

Chapter Section: Tympanomastoid Surgery

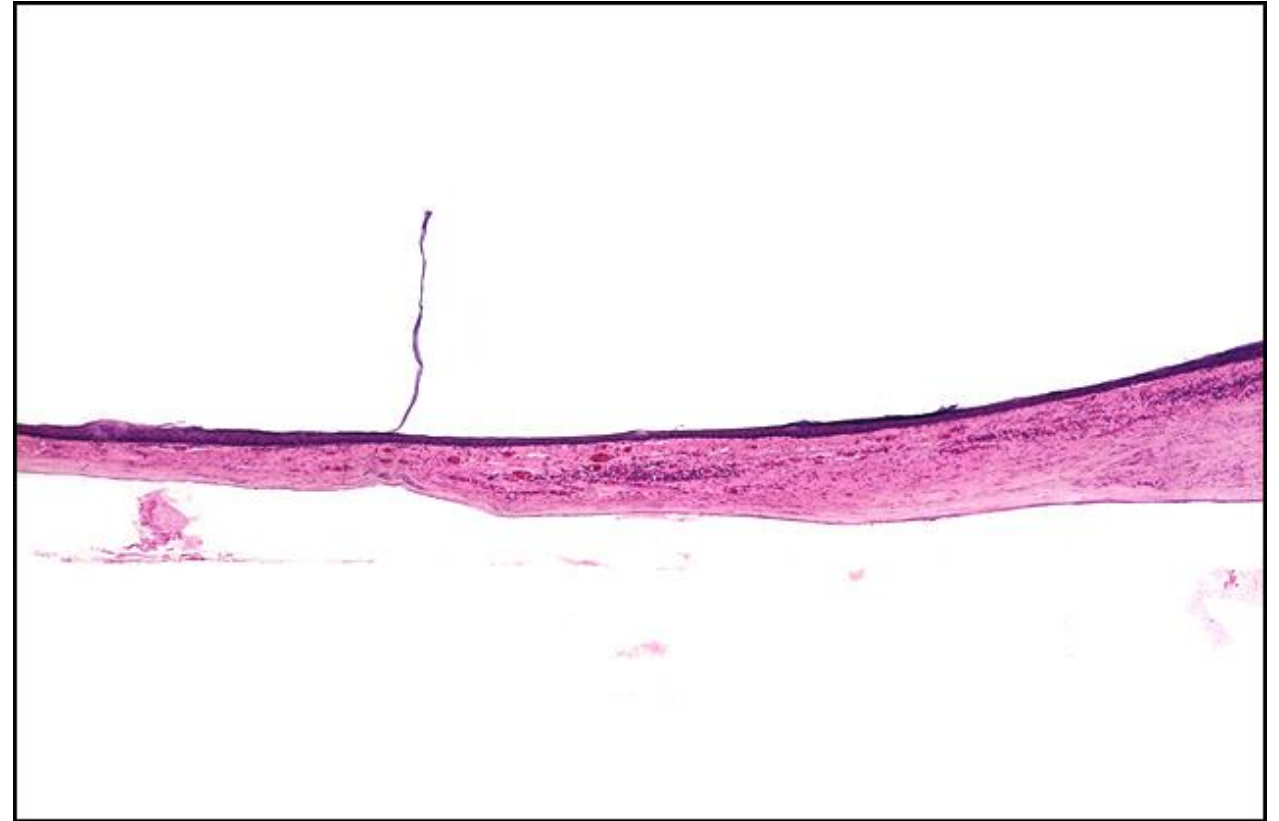TB Case Number: 440

Gender: Male

Age (yrs.): 62

Otologic Diagnosis:

1. Chronic otitis media, inactive, bilateral
2. Intact canal wall tympanomastoidectomy, showing posterior tympanotomy, fascial graft myringoplasty, cartilage graft, and Silastic implant, right
3. Devitalization and partial resorption of cartilage implant, right
4. Retraction and perforation of tympanic membrane, left
5. Fibrocystic and osseous obliteration, mastoid, left
6. Mild patchy atrophy of the stria vascularis, bilateral
7. Neural atrophy, mild, basal turns (neural presbycusis), bilateral



Intact Canal Wall Tymp, R-341

Title: Intact Canal Wall Tymp, R-341

Chapter: Surgical Pathology

Chapter Section: Tympanomastoid Surgery

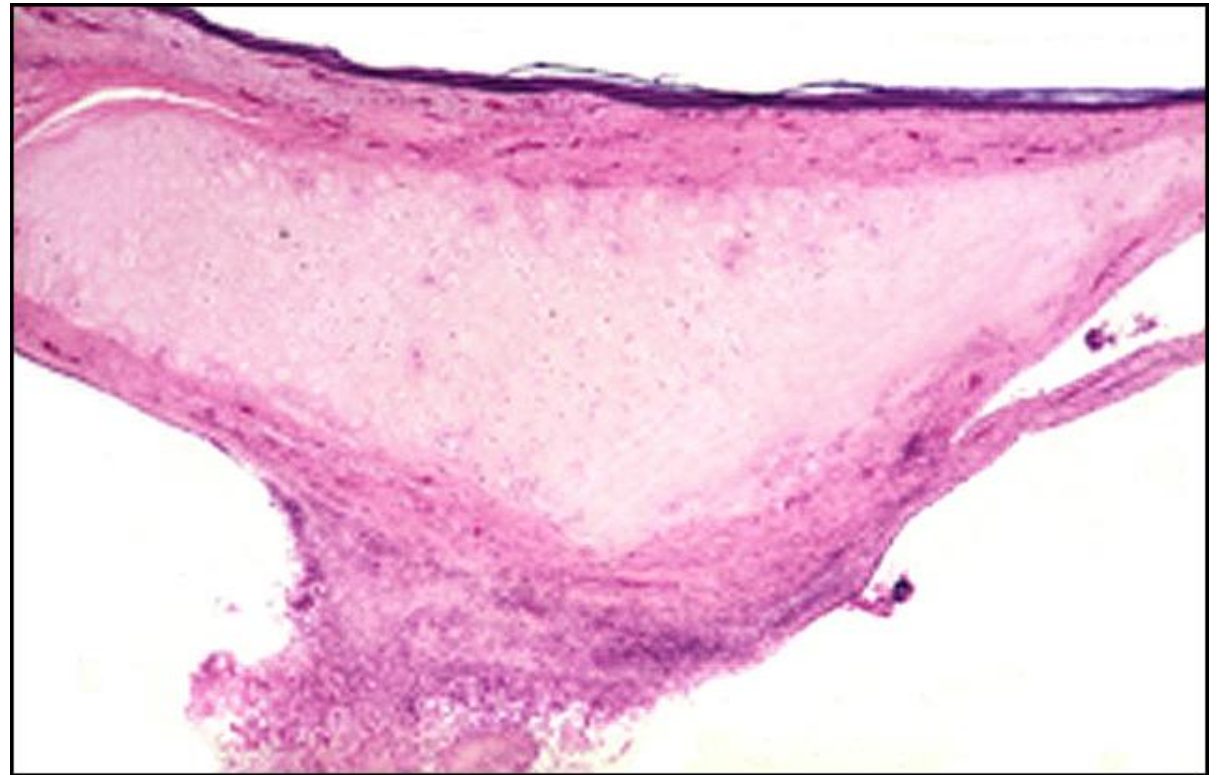
TB Case Number: 440

Gender: Male

Age (yrs.): 62

Otologic Diagnosis:

1. Chronic otitis media, inactive, bilateral
2. Intact canal wall tympanomastoidectomy, showing posterior tympanotomy, fascial graft myringoplasty, cartilage graft, and Silastic implant, right
3. Devitalization and partial resorption of cartilage implant, right
4. Retraction and perforation of tympanic membrane, left
5. Fibrocystic and osseous obliteration, mastoid, left
6. Mild patchy atrophy of the stria vascularis, bilateral
7. Neural atrophy, mild, basal turns (neural presbycusis), bilateral



Intact Canal Wall Tymp, L-96

Title: Intact Canal Wall Tymp, L-96

Chapter: Surgical Pathology

Chapter Section: Tympanomastoid Surgery

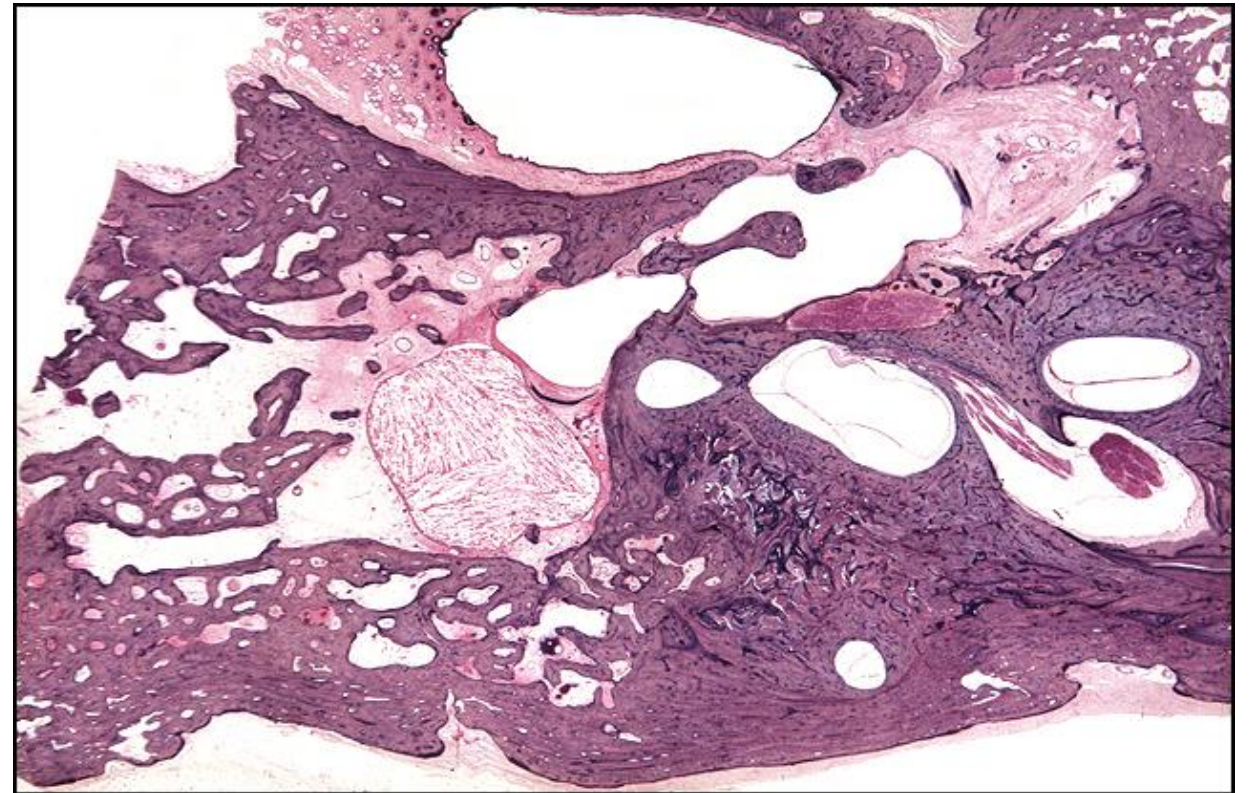
TB Case Number: 440

Gender: Male

Age (yrs.): 62

Otologic Diagnosis:

1. Chronic otitis media, inactive, bilateral
2. Intact canal wall tympanomastoidectomy, showing posterior tympanotomy, fascial graft myringoplasty, cartilage graft, and Silastic implant, right
3. Devitalization and partial resorption of cartilage implant, right
4. Retraction and perforation of tympanic membrane, left
5. Fibrocystic and osseous obliteration, mastoid, left
6. Mild patchy atrophy of the stria vascularis, bilateral
7. Neural atrophy, mild, basal turns (neural presbycusis), bilateral



Intact Canal Wall Tymp, L-341

Title: Intact Canal Wall Tymp, L-341

Chapter: Surgical Pathology

Chapter Section: Tympanomastoid Surgery

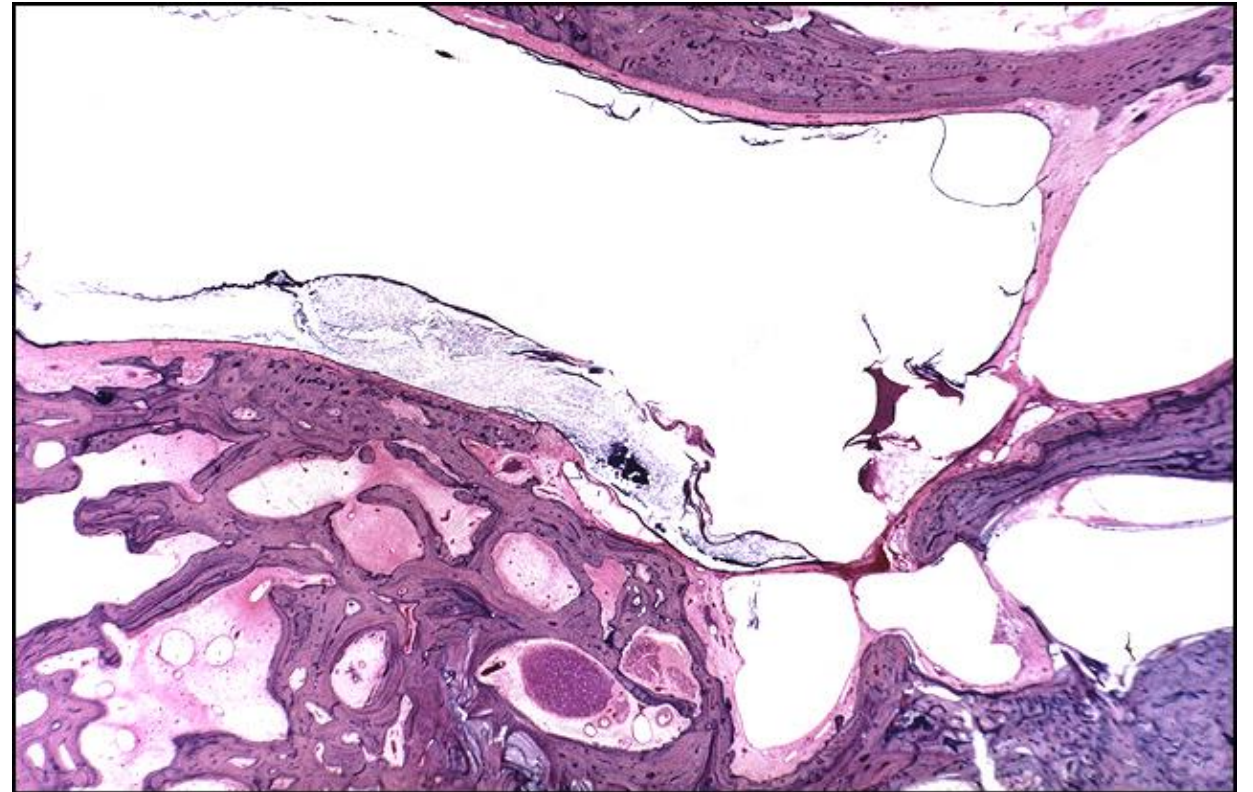
TB Case Number: 440

Gender: Male

Age (yrs.): 62

Otologic Diagnosis:

1. Chronic otitis media, inactive, bilateral
2. Intact canal wall tympanomastoidectomy, showing posterior tympanotomy, fascial graft myringoplasty, cartilage graft, and Silastic implant, right
3. Devitalization and partial resorption of cartilage implant, right
4. Retraction and perforation of tympanic membrane, left
5. Fibrocystic and osseous obliteration, mastoid, left
6. Mild patchy atrophy of the stria vascularis, bilateral
7. Neural atrophy, mild, basal turns (neural presbycusis), bilateral



Exploratory Tympanoplasty for TS Fracture, L-230

Title: Exploratory Tympanoplasty for TS Fracture, L-230

Chapter: Surgical Pathology

Chapter Section: Tympanoplasty, Tympanotomy

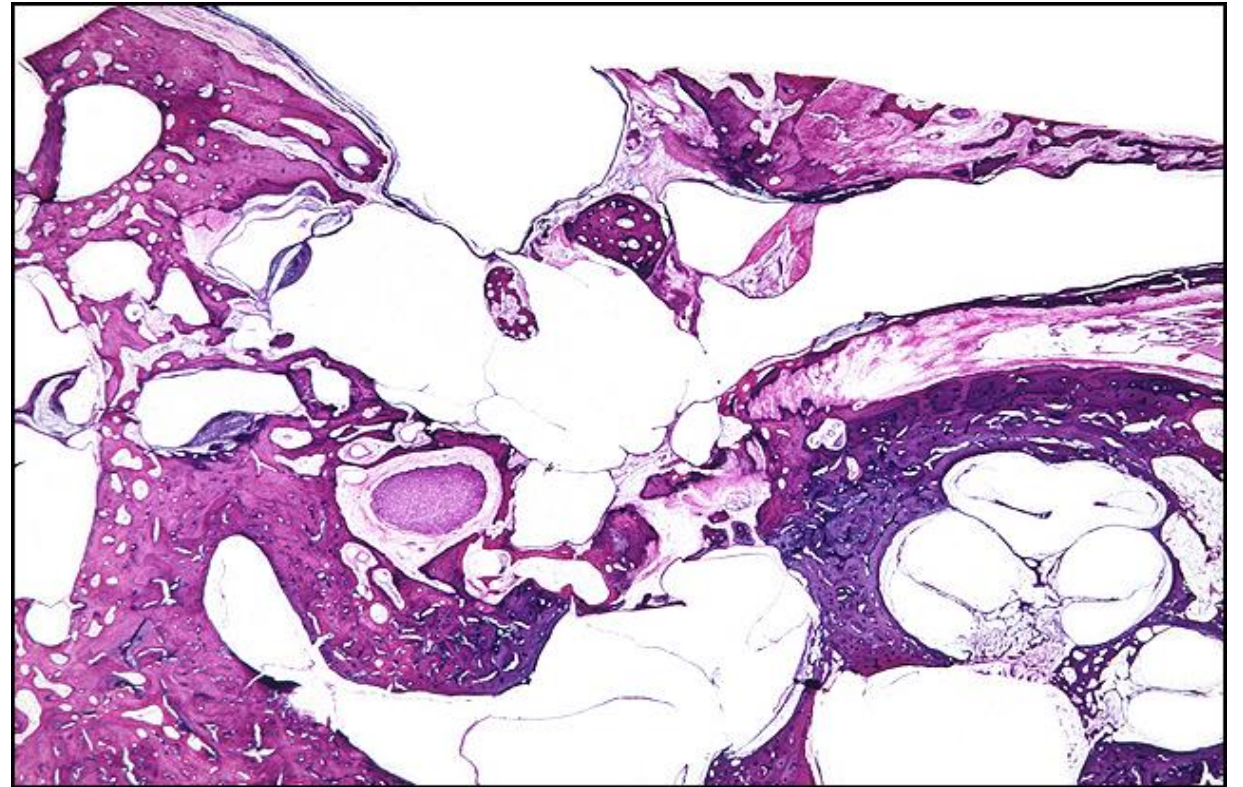
TB Case Number: 134

Gender: Female

Age (yrs.): 85

Otologic Diagnosis:

1. Tympanomastoiditis, healed, inactive, bilateral
2. False fundus, external auditory canal, secondary to fibrocystic proliferation, right
3. Tympanosclerosis, focal, mild on right, severe on left
4. Malleus, fixation, by fibrous tissue on right, by tympanosclerosis on left
5. Stapes fracture, footplate, surgically induced, bilateral
6. Prosthesis, polyethylene strut, surgically implanted, middle ear, right
7. Incus, surgically removed, right



Exploratory Tympanoplasty for Tympanosclerosis, L-547

Title: Exploratory Tympanoplasty for Tympanosclerosis, L-547

Chapter: Surgical Pathology

Chapter Section: Tympanoplasty, Tympanotomy

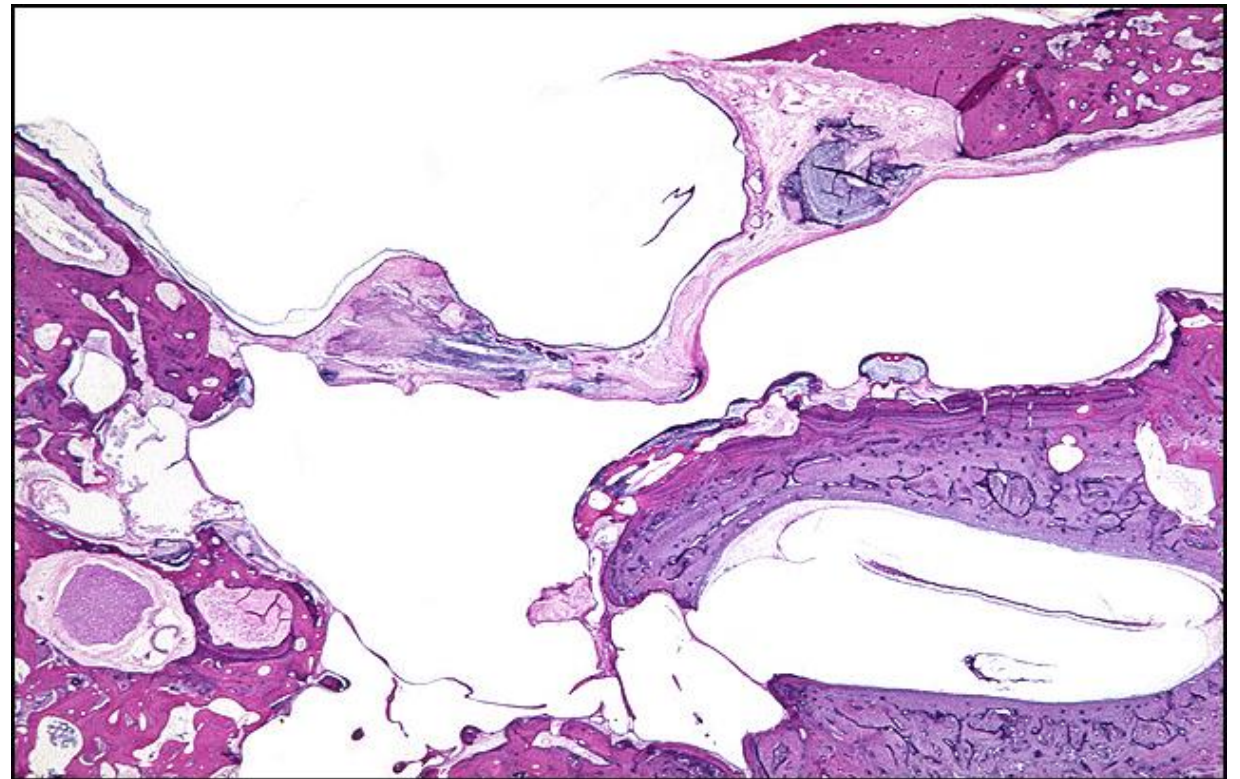
TB Case Number: 135

Gender: Female

Age (yrs.): 85

Otologic Diagnosis:

1. Tympanomastoiditis, healed, inactive, bilateral
2. False fundus, external auditory canal, secondary to fibrocystic proliferation, right
3. Tympanosclerosis, focal, mild on right, severe on left
4. Malleus, fixation, by fibrous tissue on right, by tympanosclerosis on left
5. Stapes fracture, footplate, surgically induced, bilateral
6. Prosthesis, polyethylene strut, surgically implanted, middle ear, right
7. Incus, surgically removed, right



Labyrinthectomy, L-212

Title: Labyrinthectomy, L-212

Chapter: Surgical Pathology

Chapter Section: Other Surgical Cases

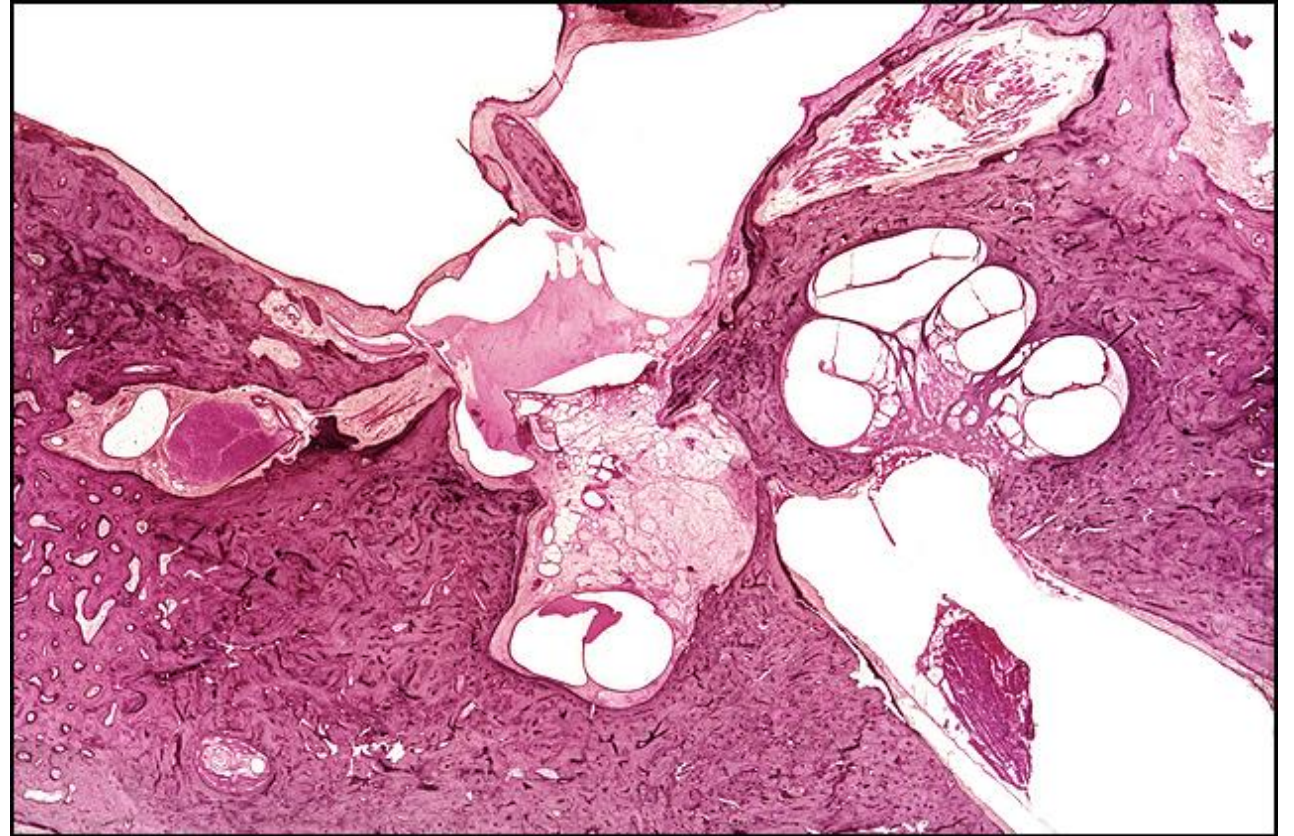TB Case Number: 848

Gender: Male

Age (yrs.): 64

Otologic Diagnosis:

1. Otitis media (chronic, fibrosing) and mastoiditis (sclerosing with attic retraction pockets), bilateral
2. Cholesteatoma, middle ear, right
3. Spiral ganglion, moderately severe degeneration, presumably with partial degeneration of the organ of Corti, right



Labyrinthectomy, L-221

Title: Labyrinthectomy, L-221

Chapter: Surgical Pathology

Chapter Section: Other Surgical Cases

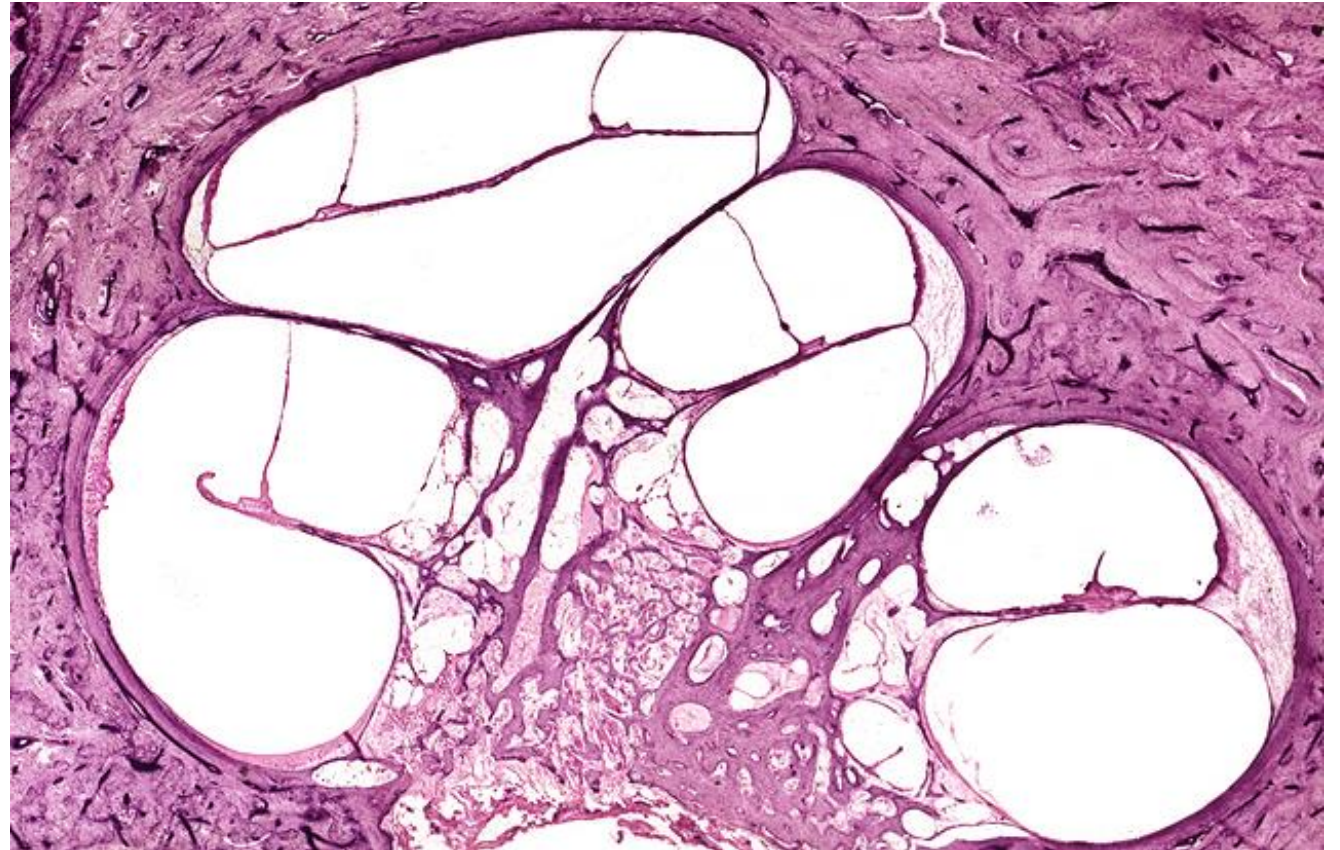
TB Case Number: 848

Gender: Male

Age (yrs.): 64

Otologic Diagnosis:

1. Otitis media (chronic, fibrosing) and mastoiditis (sclerosing with attic retraction pockets), bilateral
2. Cholesteatoma, middle ear, right
3. Spiral ganglion, moderately severe degeneration, presumably with partial degeneration of the organ of Corti, right



Labyrinthectomy, L-201

Title: Labyrinthectomy, L-201

Chapter: Surgical Pathology

Chapter Section: Other Surgical Cases

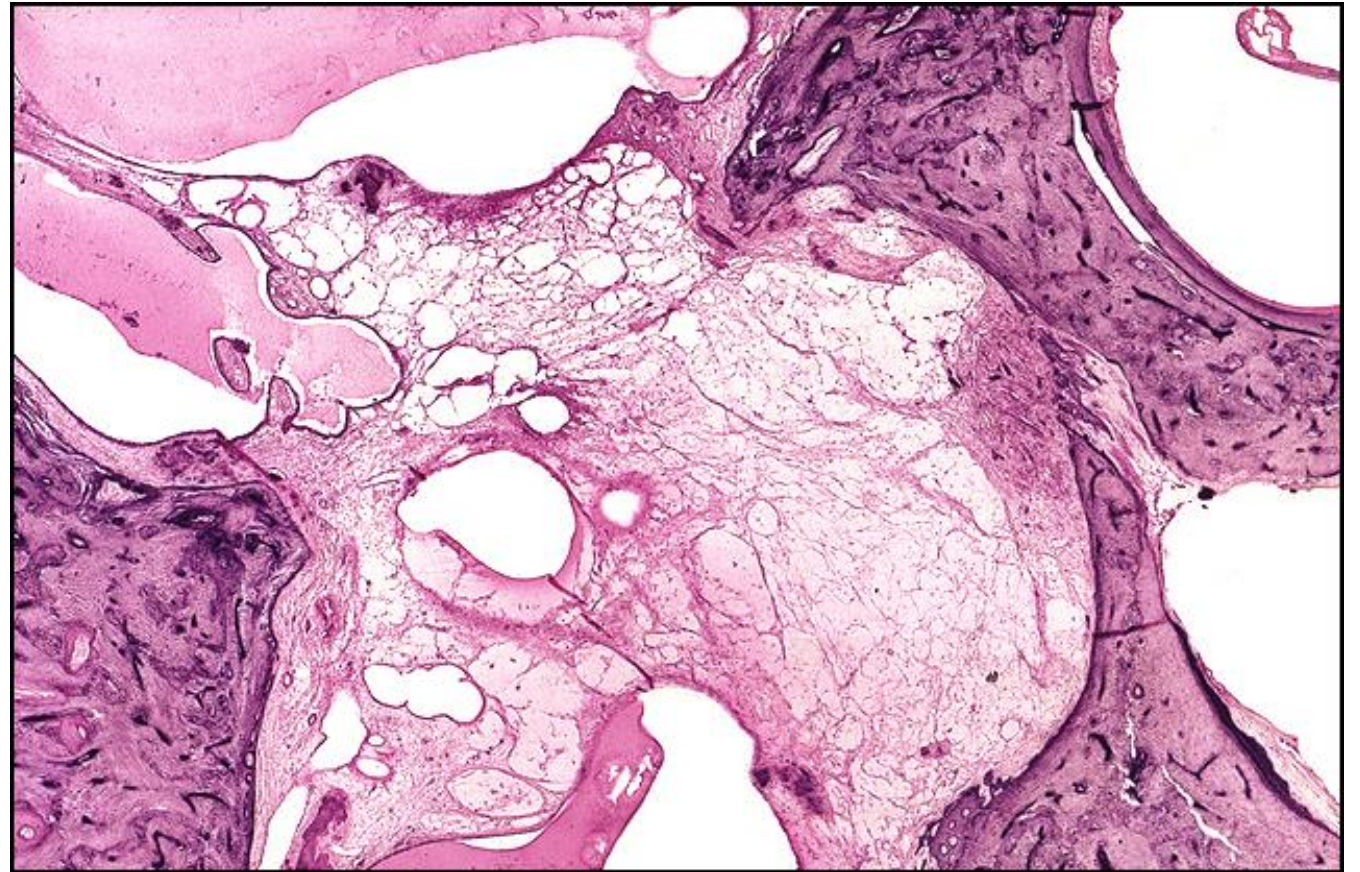
TB Case Number: 848

Gender: Male

Age (yrs.): 64

Otologic Diagnosis:

1. Otitis media (chronic, fibrosing) and mastoiditis (sclerosing with attic retraction pockets), bilateral
2. Cholesteatoma, middle ear, right
3. Spiral ganglion, moderately severe degeneration, presumably with partial degeneration of the organ of Corti, right



Labyrinthectomy, L-120

Title: Labyrinthectomy, L-120

Chapter: Surgical Pathology

Chapter Section: Other Surgical Cases

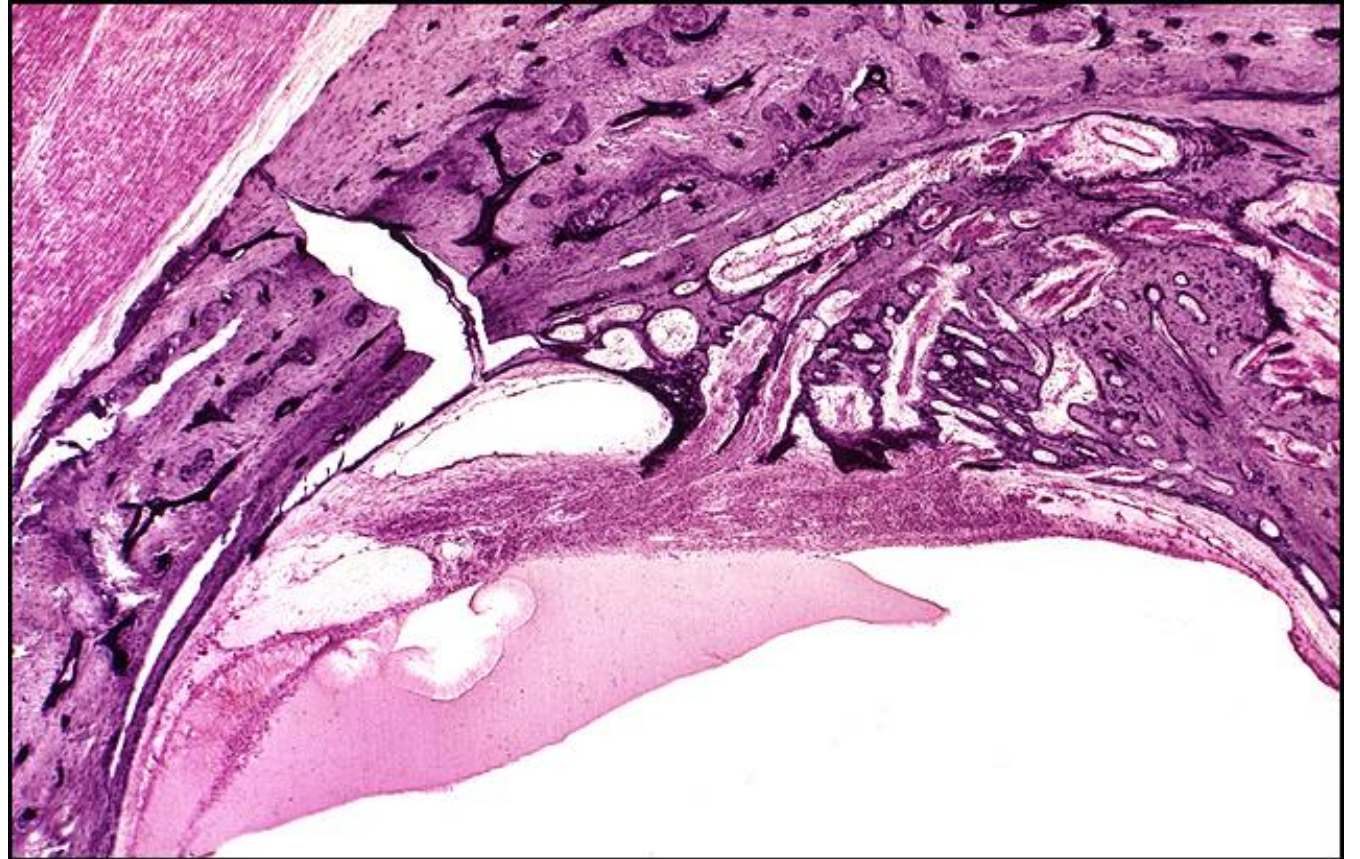
TB Case Number: 848

Gender: Male

Age (yrs.): 64

Otologic Diagnosis:

1. Otitis media (chronic, fibrosing) and mastoiditis (sclerosing with attic retraction pockets), bilateral
2. Cholesteatoma, middle ear, right
3. Spiral ganglion, moderately severe degeneration, presumably with partial degeneration of the organ of Corti, right



Labyrinthectomy, L-82

Title: Labyrinthectomy, L-82

Chapter: Surgical Pathology

Chapter Section: Other Surgical Cases

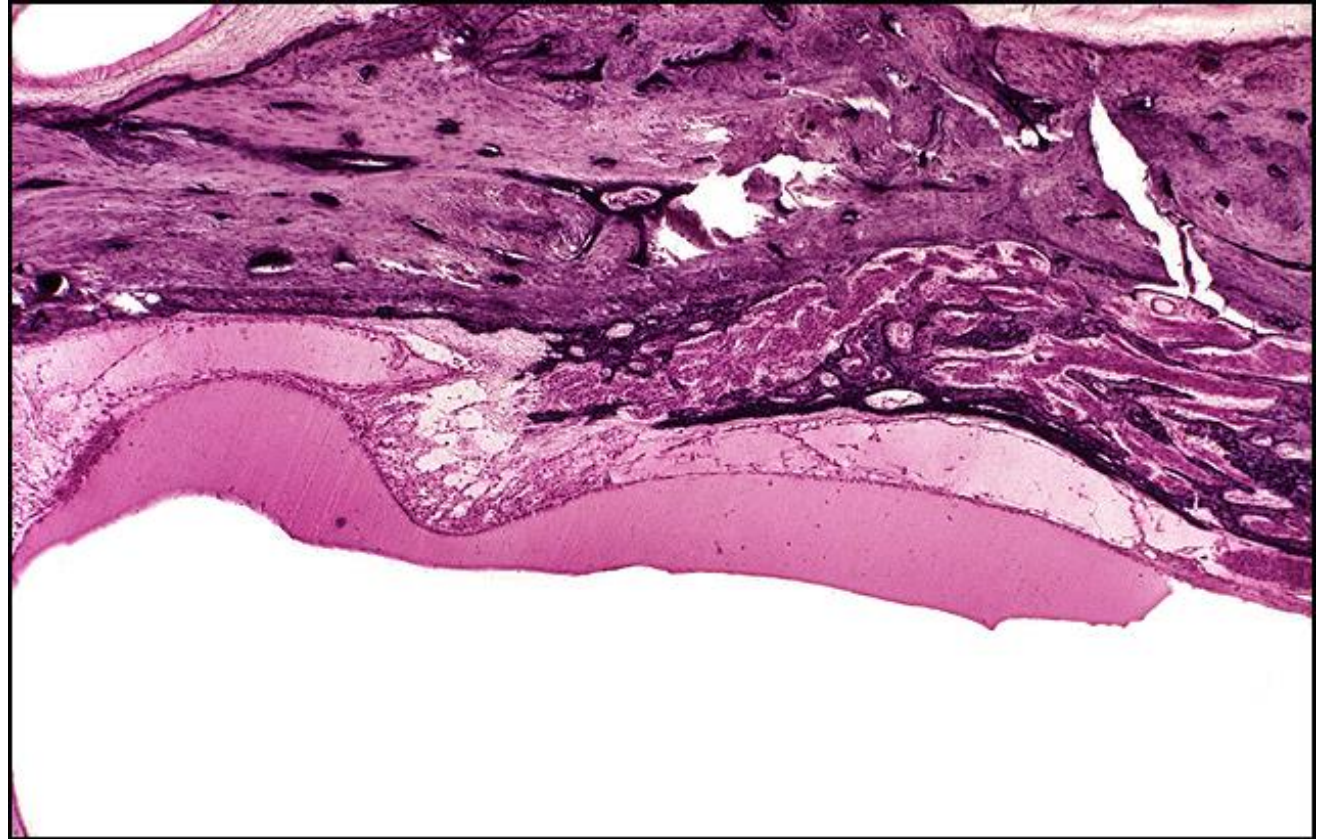
TB Case Number: 848

Gender: Male

Age (yrs.): 64

Otologic Diagnosis:

1. Otitis media (chronic, fibrosing) and mastoiditis (sclerosing with attic retraction pockets), bilateral
2. Cholesteatoma, middle ear, right
3. Spiral ganglion, moderately severe degeneration, presumably with partial degeneration of the organ of Corti, right



Labyrinthectomy, L-119

Title: Labyrinthectomy, L-119

Chapter: Surgical Pathology

Chapter Section: Other Surgical Cases

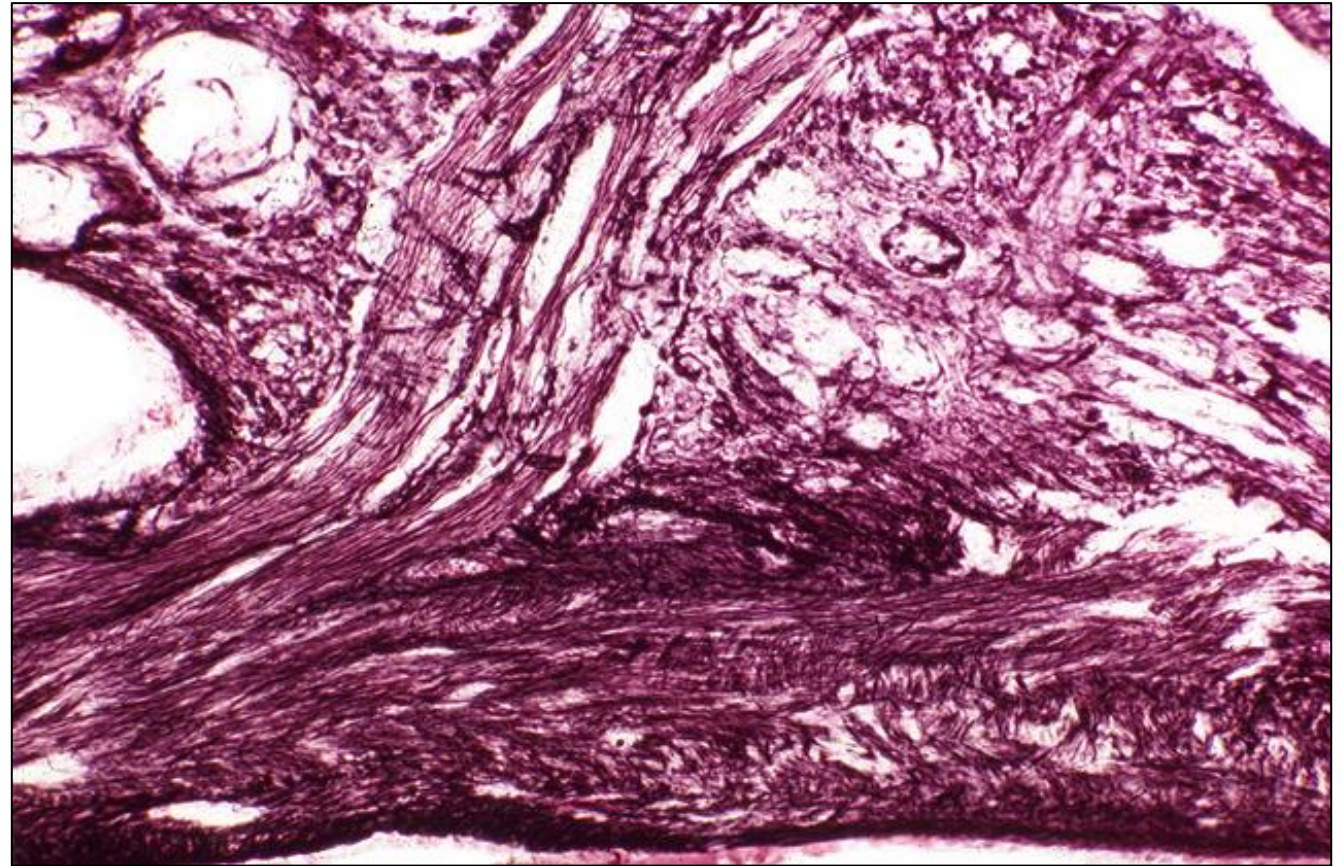
TB Case Number: 848

Gender: Male

Age (yrs.): 64

Otologic Diagnosis:

1. Otitis media (chronic, fibrosing) and mastoiditis (sclerosing with attic retraction pockets), bilateral
2. Cholesteatoma, middle ear, right
3. Spiral ganglion, moderately severe degeneration, presumably with partial degeneration of the organ of Corti, right



Labyrinthectomy, L-311

Title: Labyrinthectomy, L-311

Chapter: Surgical Pathology

Chapter Section: Other Surgical Cases

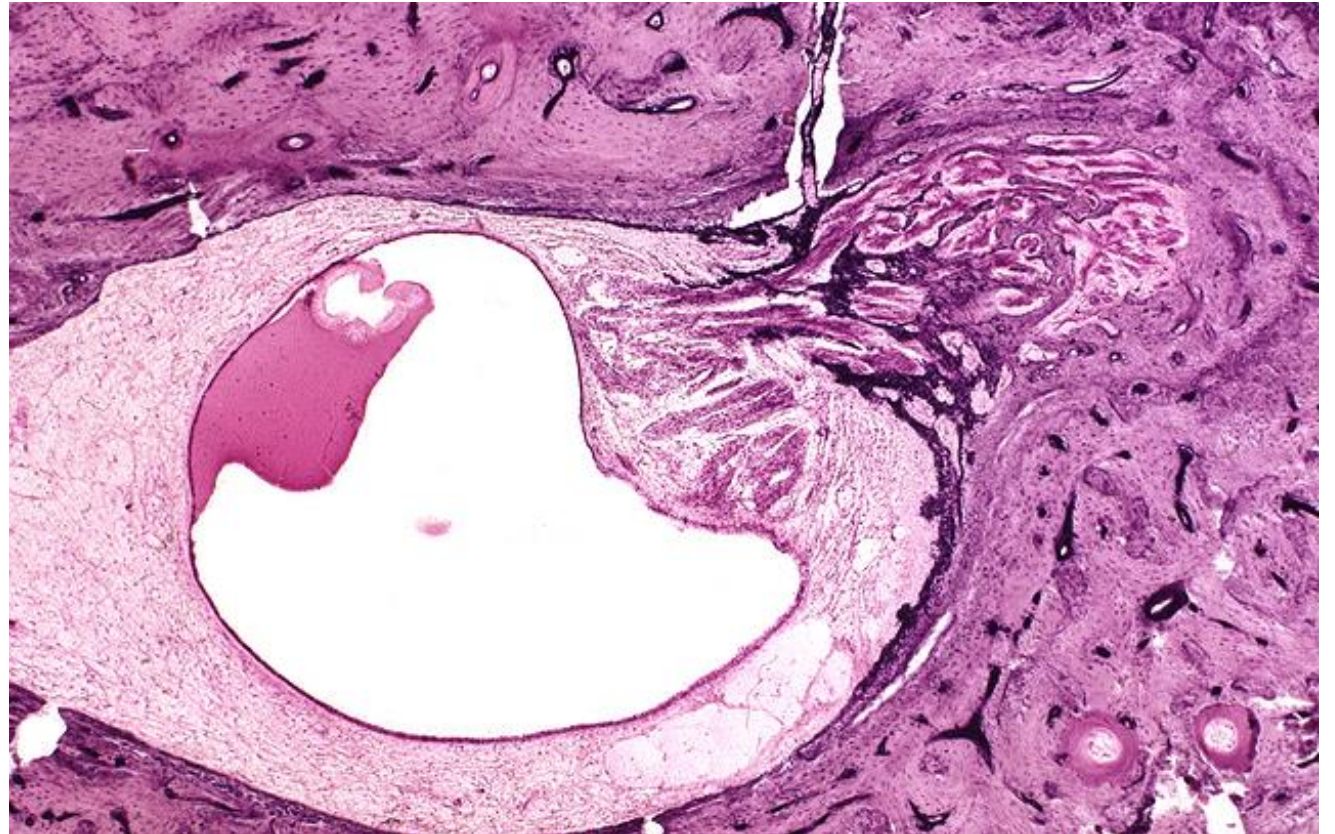
TB Case Number: 848

Gender: Male

Age (yrs.): 64

Otologic Diagnosis:

1. Otitis media (chronic, fibrosing) and mastoiditis (sclerosing with attic retraction pockets), bilateral
2. Cholesteatoma, middle ear, right
3. Spiral ganglion, moderately severe degeneration, presumably with partial degeneration of the organ of Corti, right



Labyrinthectomy, L-330

Title: Labyrinthectomy, L-330

Chapter: Surgical Pathology

Chapter Section: Other Surgical Cases

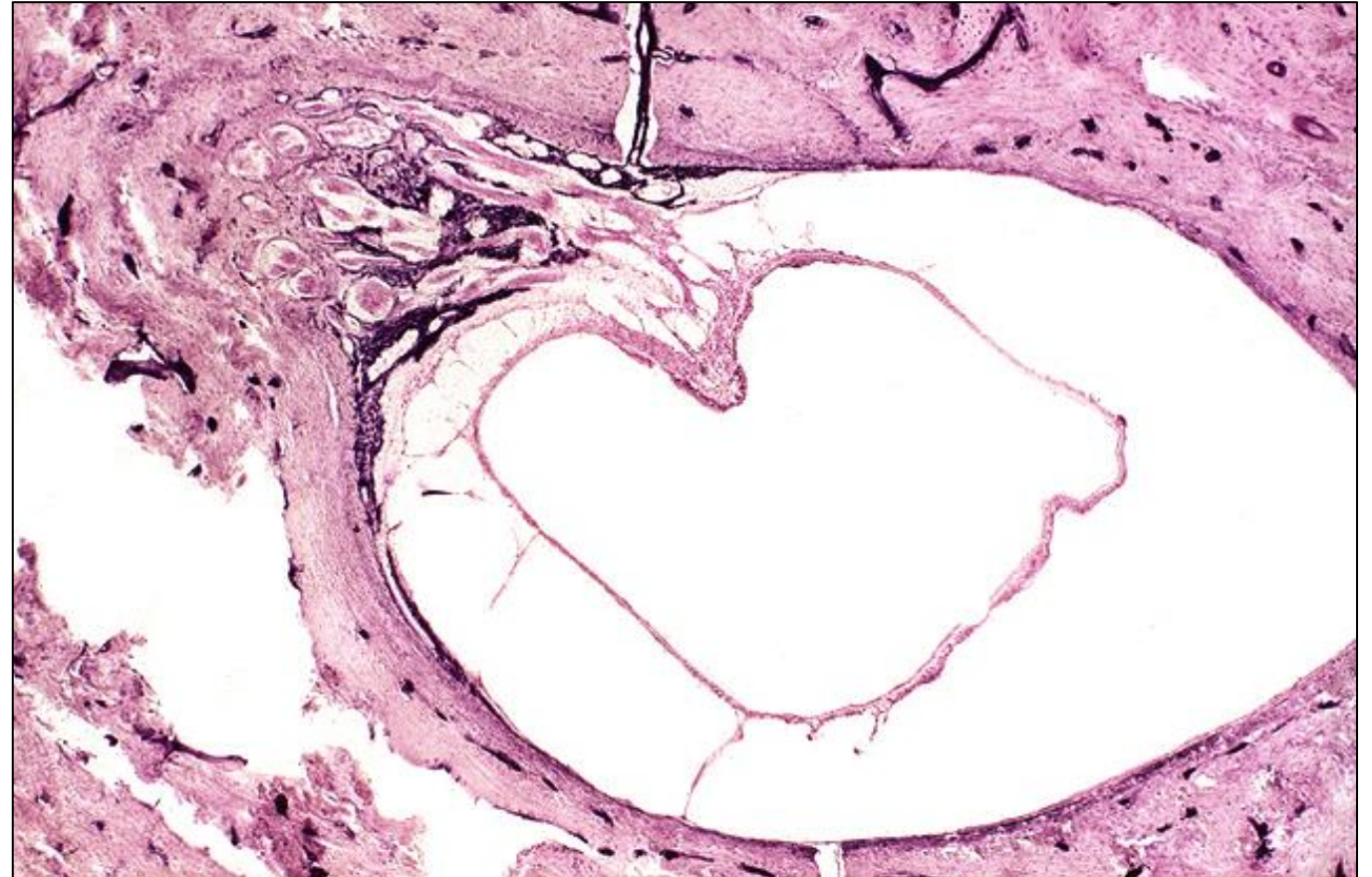TB Case Number: 848

Gender: Male

Age (yrs.): 64

Otologic Diagnosis:

1. Otitis media (chronic, fibrosing) and mastoiditis (sclerosing with attic retraction pockets), bilateral
2. Cholesteatoma, middle ear, right
3. Spiral ganglion, moderately severe degeneration, presumably with partial degeneration of the organ of Corti, right



Labyrinthectomy, R-121

Title: Labyrinthectomy, R-121

Chapter: Surgical Pathology

Chapter Section: Other Surgical Cases

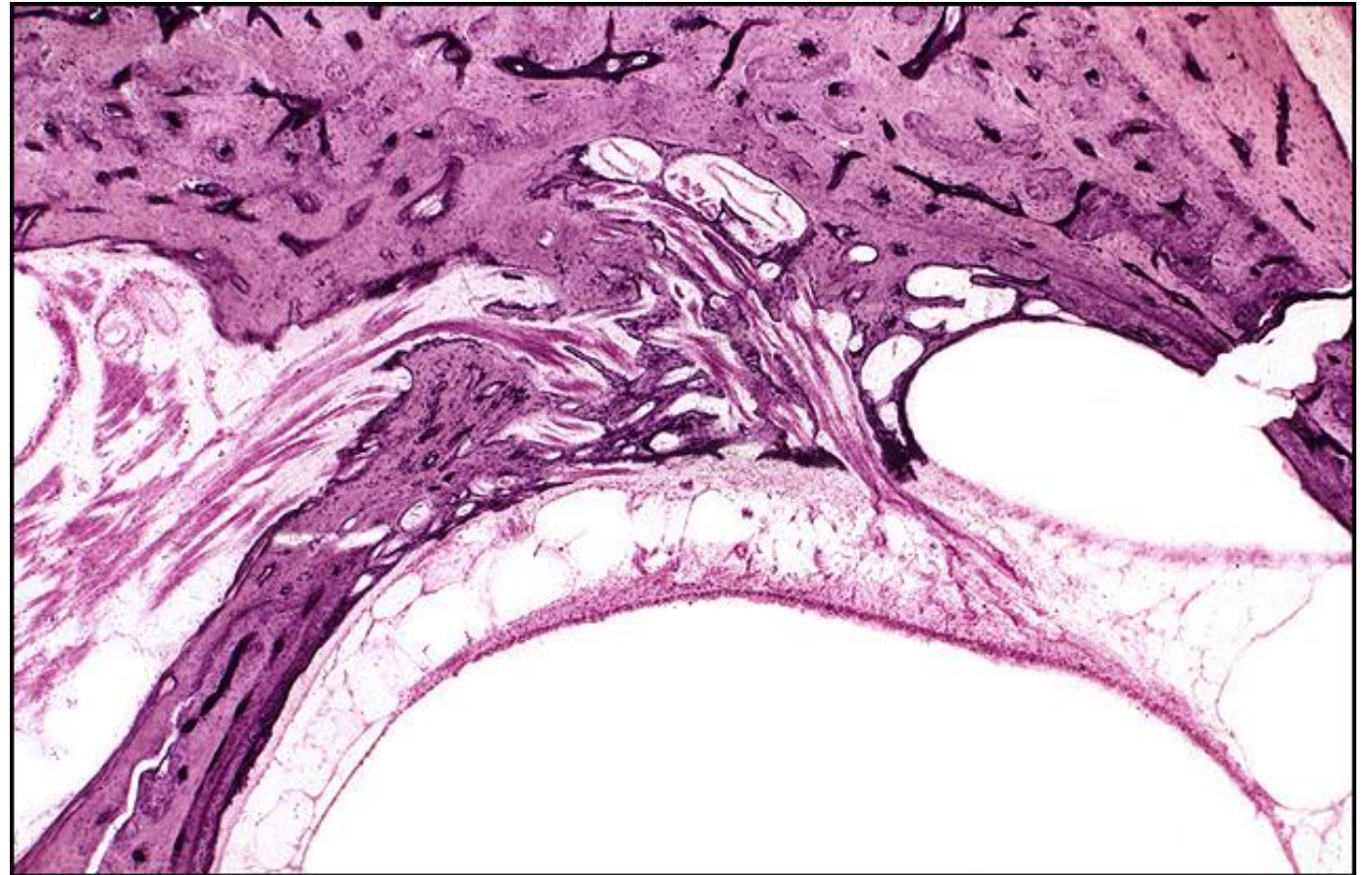
TB Case Number: 848

Gender: Male

Age (yrs.): 64

Otologic Diagnosis:

1. Otitis media (chronic, fibrosing) and mastoiditis (sclerosing with attic retraction pockets), bilateral
2. Cholesteatoma, middle ear, right
3. Spiral ganglion, moderately severe degeneration, presumably with partial degeneration of the organ of Corti, right



Labyrinthectomy, R-192

Title: Labyrinthectomy, R-192

Chapter: Surgical Pathology

Chapter Section: Other Surgical Cases

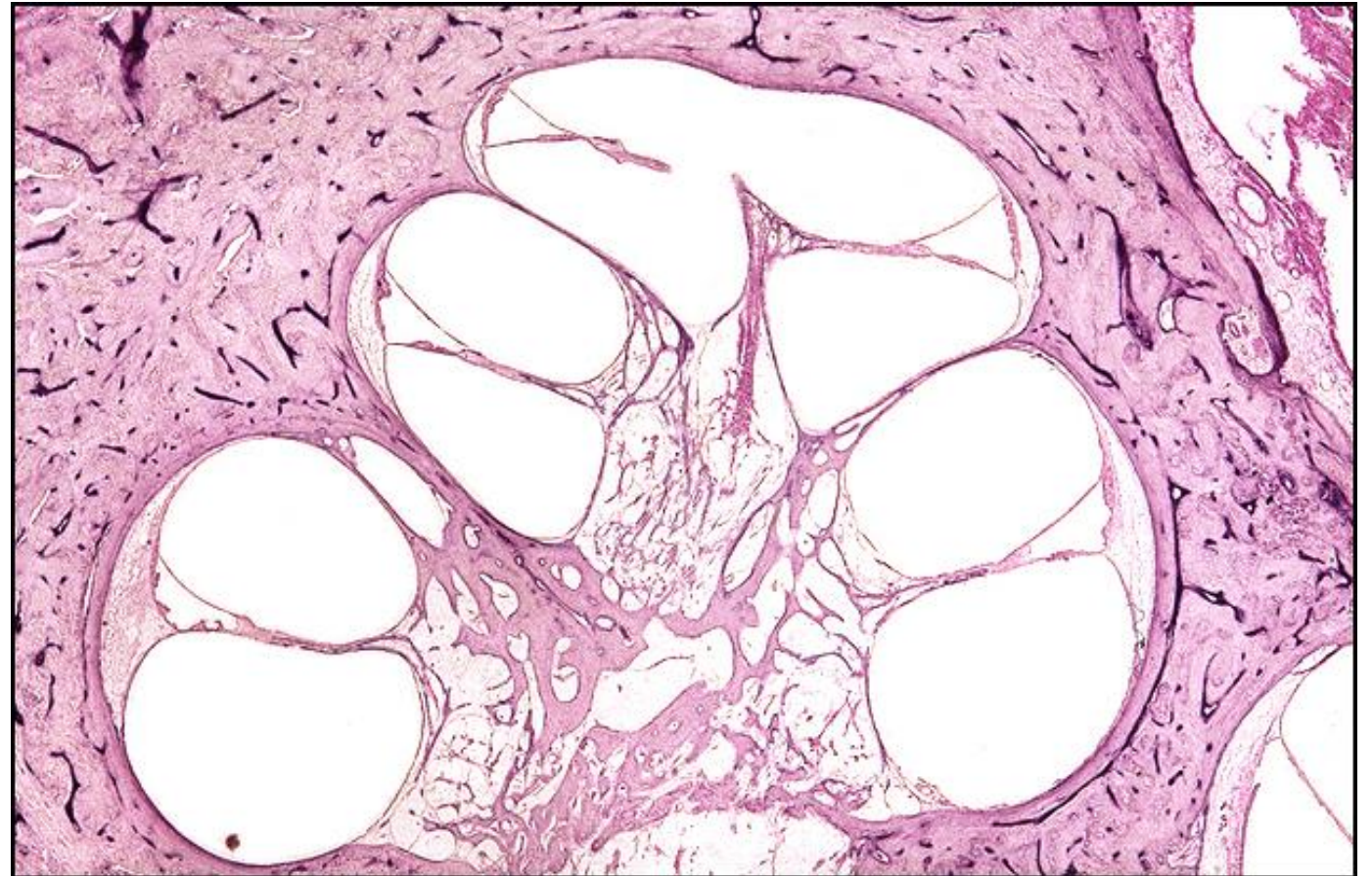
TB Case Number: 848

Gender: Male

Age (yrs.): 64

Otologic Diagnosis:

1. Otitis media (chronic, fibrosing) and mastoiditis (sclerosing with attic retraction pockets), bilateral
2. Cholesteatoma, middle ear, right
3. Spiral ganglion, moderately severe degeneration, presumably with partial degeneration of the organ of Corti, right





Mass General Brigham

Mass Eye and Ear